



Manuscript ID ZUMJ-2207-2605 (R1)

DOI 10.21608/ZUMJ.2022.151612.2605

**ORIGINAL ARTICLE**

## Outcome of Decompression with Transpedicular Screw Fixation and Posterolateral Fusion in Stable Degenerative Lower Lumbar Canal Stenosis

Ashraf El-Desouky<sup>1\*</sup>, Ahmed M. Deabes<sup>1</sup>, Mohammed Mourad<sup>1</sup>, Shawky El melegy<sup>1</sup>

<sup>1</sup>Neurosurgery Department, Benha Faculty of Medicine, Benha University, Benha City, Egypt

**\*Corresponding Author:**

Ashraf El-Desouky  
Neurosurgery Department, Benha  
Faculty of Medicine, Benha  
University, Benha City, Egypt  
E-mail:  
ashrafeldesouky73@gmail.com  
Submit Date 2022-07-21  
Revise Date 2022-08-21  
Accept Date 2022-09-11

**ABSTRACT**

**Background:** Treatment of choice in degenerative lumbar canal stenosis (LCS) is laminectomy. Adding lumbar fusion to decompression is another option preferred by some surgeons to prevent possible instability after posterior elements removal.

**Methods:** A prospective study where we evaluated 64 patients with degenerative lower LCS in Benha University Hospitals from January 2017 to January 2020, those underwent decompression of lower two levels L4-5 and L5-S1 with instrumented fusion of L4,5 and S1 with 2-year follow-up. Pain changes were evaluated using VAS score at 1- and 2-year post-operative and functional outcome at 1- and 2-year post-operative using Oswestry Disability Index (ODI) compared to preoperative scores.

**Results:** Age of our patients ranged from 38 to 62 years with a mean of  $54.4 \pm 6.8$  years and 42 patients were females (65.6%). VAS changes for low back pain and leg pain recorded at 1 and 2-year post-op. compared to preop. showed statistically significant improvement ( $P < 0.001$ ), also there was a significant decrease in VAS for both that recorded 2-year post-op. compared to 1-year post-op. ( $P < 0.001$ ). We found improvements in means regarding ODI recorded at 1 and 2-year post-op. compared to preop. mean statistically significant ( $P < 0.001$ )

**Conclusions:** We hereby recommend laminectomy of L4 and L5, with instrumented posterolateral fusion of L4,5, and S1 regarding the significant pain reduction and excellent functional outcome without perioperative major complications to avoid the high possibility of spine instability and the need for second surgery with added risk and cost that may follow posterior decompression alone in such cases.

**Keywords:** Lumbar Canal stenosis; Lumbar spine laminectomy; Transpedicular screw fixation



### INTRODUCTION

Degenerative lumbar canal stenosis (LCS), causes significant pain and disability and is considered as one of the most common indications for spine surgery [1]. There are multiple underlying pathological factors as fibrous tissue hyperplasia and facet joint arthropathy leading to diminution of the sagittal diameter of the spinal canal and/or nerve root foramina, causing clinical symptoms resulting from compression of the spinal nerve root or cauda equina [2]. According to the etiology of LCS it is classified into congenital and degenerative types and according to the site of compression it is classified into central, lateral recess, and foraminal stenosis [3]. In central lumbar canal Stenosis, the patients complain of

neurogenic intermittent claudication while the patients with lateral recess or foraminal stenosis are usually complaining of radicular symptoms. Symptoms are different with different types of LCS [4].

The diagnostic tool of choice for evaluation of LCS is Magnetic resonance imaging (MRI); showing radiographic evidence of the spinal canal narrowing and classifying LCS type and severity [5]. Usually, surgical treatment of LCS is indicated when the trial of conservative management in the form of at least six months of medical treatment and physiotherapy failed [6]. In LCS, the optimal surgical technique is still a debatable subject, and we had no clear guidelines to make an easy decision in such cases [7].

Over the past decades, multiple lumbar spine decompression techniques have been described for the surgery of LCS [8]. Conventionally to obtain adequate decompression of LCS, laminectomy is the most commonly used technique removing the posterior elements, in spite of that, some studies documented the high rate of a second surgery after it as the patient after surgery may develop spinal instability and also weakness and atrophy of his muscles as a result of extensive removal of posterior stabilizing elements [9,10,11].

The alternative surgical techniques as microsurgical procedures took place for the management of LCS, in order to reduce the invasiveness of the classic laminectomy and to avoid postoperative possible instability [11].

The clinical outcome of the classic lumbar laminectomy improved by the addition of fusion to it, but this was found to cause some complications as adjacent segment degeneration acceleration and complications related to the fixation system itself [12].

The goal of our study is the evaluation of the outcome of transpedicular screw fixation with fusion when added to posterior decompression in stable degenerative lower lumbar canal stenosis and comparing the results with those of the conventional laminectomy used for LCS decompression published in the literature.

## METHODS

This prospective clinical study was conducted at Benha University Hospital from January 2017 to January 2020, where selected 70 patients with degenerative LCS at both levels of L4-5 and L5-S1, underwent lumbar laminectomy of L4 and 5 laminae, foraminotomy with transpedicular screw fixation of L4-L5-S1 with posterolateral bone fusion. Our patients had postoperative follow-up for at least 2 years. Those patients had typical symptoms of neurogenic intermittent claudication and/or radiculopathy due to degenerative LCS and with failed conservative management for at least 6 months in the form of medical treatment and physiotherapy. For all patients, a preoperative MRI was done that showed LCS at two levels (L4-5) and (L5-S1), with possible one-level lumbar disc prolapse at L4-5 or L5-S1.

Patients with radiologic evidence of preoperative instability, previous surgery for the lumbosacral spine, patients with associated sacroiliitis based on clinical examination, patients who had preoperative osteoporosis, and /or those with associated cervical

or dorsal surgical pathology were all excluded from this study.

**Preoperative evaluation:** We did an evaluation for our patients beginning with history taking including their medical status and the associated morbidity as DM, HTN, and IHD, also history and date of last general anesthesia if any. After that, a detailed history of their recent illness was taken regarding low back pain, sciatica, neurogenic claudication, and symptoms related to muscle weakness (foot drop) and sphincter troubles.

The General examination was done followed by a neurologic examination to assess the back tenderness, lower limb motor power, sensory changes, reflexes, signs of nerve root compression, sacroiliitis, and gait abnormalities. After that, routine laboratory tests, ECG, echocardiography, and chest X-ray were done and revised by the anesthesiologist for surgical fitness. All patients had preoperative MRI lumbosacral spine (LSS), preoperative X-ray LSS including Antero-posterior, Lateral, right, and left oblique views, and Lateral maximum flexion and extension dynamic views to exclude preoperative instability at L4,5 and S1. All patients had a preoperative Dual-energy X-ray Absorptiometry (DEXA) to assess bone density to exclude the patients with osteoporosis (T score < -2.5), in addition to patients with normal bone density, the patient with osteopenia (T score -1 to -2.5) were included but to improve their bone density they were given treatment after surgery.

For clinical evaluation, Visual Analogue Score (VAS) was recorded before surgery for assessment of low back pain and for leg pain for all patients then again at one and two years postoperative for comparison and worth to be mentioned that in patients with bilateral leg pains, we only recorded the VAS of the most painful side in our preoperative and postoperative records for comparison. For assessment of the functional outcome of our patients, the preoperative Oswestry Disability Index (ODI) was recorded for all of them and again at one and two years postoperative for comparison. ODI is the most commonly used outcome-measure questionnaire for low back pain. It is divided into ten sections to evaluate the limitations of different daily living activities. Each section is scored on a 0–5 scale. To calculate the ODI, we divide the summed score by the total possible score, then multiplied by 100 and expressed it as a percentage. So, for every question not answered, the denominator is reduced by 5 [13]. For postoperative radiological evaluation, we did plain x-ray LSS (A-p, lateral and maximum flexion

and extension views) during the postoperative hospital stay to initially evaluate the screw positioning and repeated again at 2 years postoperative to evaluate the bone fusion with CT LSS to document the direction of the screws and any possible breach. And to be mentioned that we planned to do emergency postoperative CT LSS during postoperative hospital stay in cases with new postoperative sciatica or neurological deficit to review the direction of the screws and decide the need for surgical revision or not and we reserve the MRI for patients if showing unsatisfactory postoperative clinical improvement.

**Surgical technique:** After general anesthesia, we put our patients in the prone position, and after proper sterilization and draping, adequate skin incision was done, subperiosteal muscle separation and then we prepare for screw insertion. Using intraoperative fluoroscopy guidance transpedicular screw fixation of L4-L5-S1 using 6 titanium screws were done. Laminectomy of L4 and L5 laminae, removing the medial one-third of the facet joint, and foraminotomy were done after that, to ensure adequately decompressed lumbar spinal canal and nerve roots, we did discectomy for disc prolapse in some cases if it was compromising the neural structure. In all cases, screws were inspected for malposition after decompression was completed and if any, the screws were revised and re-applied properly. Posterolateral bone graft was harvested from the laminectomy used for bone fusion, after decortication of transverse processes of targeted segments and then 2 rods were secured to the screws., closure in layers was done after proper hemostasis and a drain left and removed within 48 hours after surgery. 6 hours after surgery we checked and evaluated the motor power, sensation, sciatica, and wound drain and then re-evaluated every 12 hours till discharge. Patients were asked for early ambulation (usually on the next day morning), and the postoperative hospital stay ranged from 2 to 4 days for most of them, in case of needed further follow-up regarding their medical or surgical status, they were kept until their condition stabilized. Our patients after surgery received antibiotics for ten days and NSAIDs for two weeks on average. We removed the wound stitches 14 days postoperative and sometimes longer especially in diabetic patients if the wound healing needed more time and follow up visits were done twice monthly for 3 months then at 6, 9, 12,18, and 24 months and if they needed they could return in between.

**Informed consent and ethics committee approval:** This study was approved by the Research Ethics

Committee (REC) of the Neurosurgery Department, Faculty of Medicine, Benha University in October 2016. All patients signed informed consent for the surgery. All performed procedures involving humans were in accordance with the ethical standards of the institutional and/or national research committee and with the 1964 Helsinki Declaration and its later amendments or comparable ethical standards.

**Statistical analysis:** Data entry, presentation, and analyses were carried out using Microsoft Excel, and the STATA/SE version 11.2 for Windows (STATA Corporation, College Station, Texas). Numerical data were summarized as mean ( $\pm$  SD) and range. Categorical data were summarized as frequency and percentage. The distribution of numerical data was examined using the Shapiro-Wilk W test for normality. The Wilcoxon signed rank test (z) and the paired t-test (t) were used to detect changes in VAS scores and ODI levels recorded pre-operative, 1-year post-operative, and 2-year post-operative, as appropriate. Statistical significance was considered at  $P < 0.05$ .

## RESULTS

From January 2017 to January 2020, 70 patients were operated on according to our inclusion criteria previously mentioned, 6 patients were lost to follow-up, so only the remaining 64 cases data and results analyzed. The age of our patients ranged from 38 to 62 years with a mean of 54.4 ( $\pm 6.8$ ) and out of 64 patients, we had 42 female patients (65.6%). Table (1) shows the demographic criteria and the associated comorbidities of the studied patients.

Table (2) shows operative data for the studied patients as regards the operative time, estimated blood loss, and the length of hospital stay.

Table (3) shows the clinical evaluation of the studied patients. The preoperative VAS for low back pain ranged from zero to ten with mean  $\pm$ SD = 6.9 $\pm$ 2.2 that had become lower at one-year postoperative follow-up with a range from one to five and mean  $\pm$ SD = 2.9 $\pm$ 1.0 and at 2 years follow up the VAS score ranged from zero to three with mean  $\pm$ SD = 1.4 $\pm$ 0.8. These changes in the VAS for low back pain were recorded at 1 and 2-year post-op. in relation to preop. showed statistically significant improvement ( $P < 0.001$ ). Also, there was a significant decrease in VAS for low back pain recorded 2-year post-op. compared to 1-year post-op. ( $P < 0.001$ ).

The preoperative VAS for leg pain ranged from two to eight with mean  $\pm$ SD = 5.3 $\pm$ 1.5 that had become lower at one-year postoperative follow-up with a range from zero to five and mean  $\pm$ SD = 2.3 $\pm$ 1.1 and at 2-year follow-up, the VAS score ranged from zero

to three with mean  $\pm$ SD =  $1.0 \pm 0.8$  and we found these changes in VAS for leg pain recorded at 1 and 2-years post-op. in relation to preop. statistically significant ( $P < 0.001$ ). Also, comparing the VAS recorded at 2-year post-op to 1-year post-op was significantly improved ( $P < 0.001$ ).

The preoperative ODI ranged from 46.7 to 66.7 % with mean  $\pm$ SD =  $56.25 \pm 6.5\%$  that had become at one-year postoperative follow-up with a range from 40 to 53.3 % and mean  $\pm$ SD =  $46.6 \pm 4.5\%$  and at 2 years follow up the ODI score ranged from 26.7 to 48.9 % with mean  $\pm$ SD =  $37.5 \pm 6.9\%$  and we found these improvements in means regarding ODI recorded at 1 and 2-years post-op. in relation to preop. mean statistically significant ( $P < 0.001$ ) and also comparing the mean at 2-year post-op. to 1-year post-op. was significantly improved ( $P < 0.001$ ).

During the two years follow-up, we had no radiological evidence of spondylolisthesis in any of our patients after added lumbar fixation and bone fusion regarding that instability is the most

challenging issue following decompression surgery of more than one level of low lumbar canal stenosis when done without instrumented fusion.

Seven patients had postoperative complications; two of them had superficial wound infections, both discovered during the first week after surgery and managed conservatively with IV 3rd generation cephalosporins for 3 weeks followed by oral antibiotics for another 3 weeks. Two patients had an intraoperative dural tear which were successfully repaired with no post-operative CSF leakage. We had other three patients who needed revision of misdirected screws as they had severe postop. radiculopathy without affection of motor power and the 3 patients had improved after revision from leg pain VAS 6-7 to VAS scores 2-3. (Please see figures 1,2,3 and 4 of one of our patients, a male patient 38 years old, who had low back pain and bilateral neurogenic claudicating sciatica and was not responding to conservative management.).

**Table 1:** Demographic characteristics and comorbidities of the studied patients.

Characteristics (no. = 64)	No	%	
<b>Age (years)</b>	<55	23	35.9
	$\geq 55$	41	64.1
	Mean $\pm$ SD Range	54.4 $\pm$ 6.8 38 - 62	
<b>Gender</b>	Male	22	34.4
	Female	42	65.6
<b>Comorbidities</b>	Diabetic	5	7.8
	Hypertensive	6	9.4
	Cardiac (IHD)	4	6.2
	DM, HTN, Cardiac	5	7.8
	None	44	68.7

Table 2 shows operative data for the studied patients as regards the operative time, estimated blood loss, and the length of hospital stay.

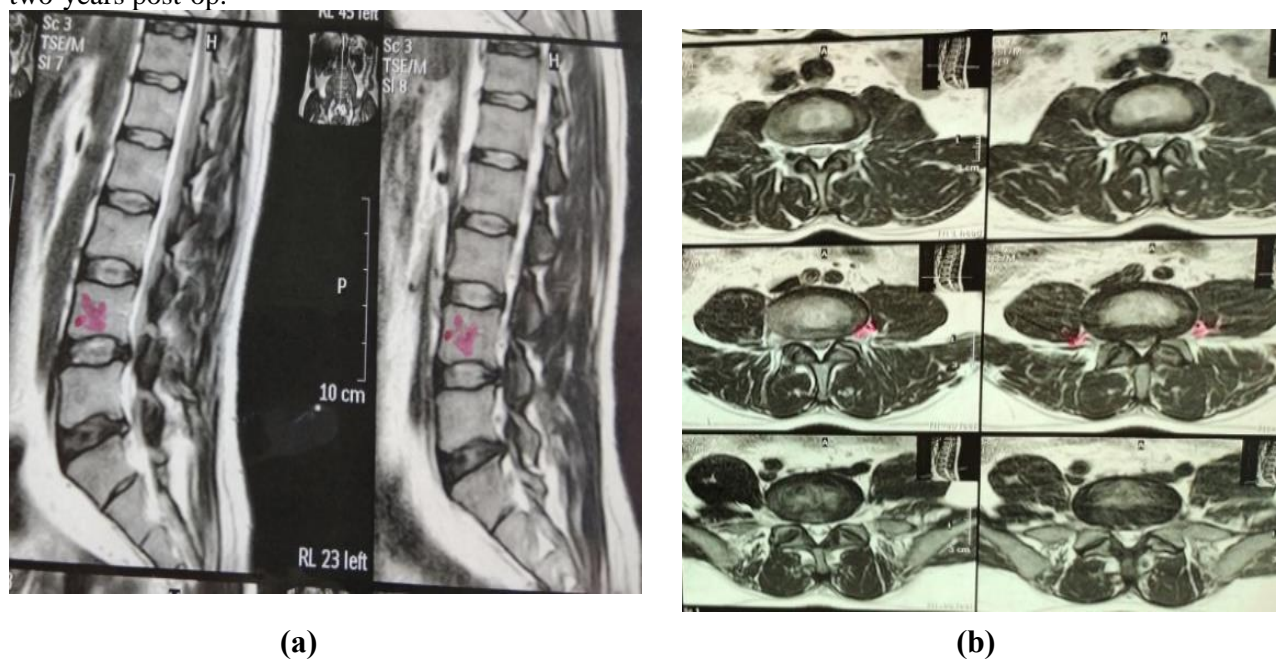
**Table 2:** Operative data for the studied patients.

No. = 64	Range	Mean $\pm$ SD
<b>Operative time (min.)</b>	200-260	222.6 $\pm$ 20.1
<b>Estimated blood loss (ml)</b>	230-600	353.7 $\pm$ 115.9
<b>The length of hospital stay (days)</b>	2-15	3.25 $\pm$ 1.8

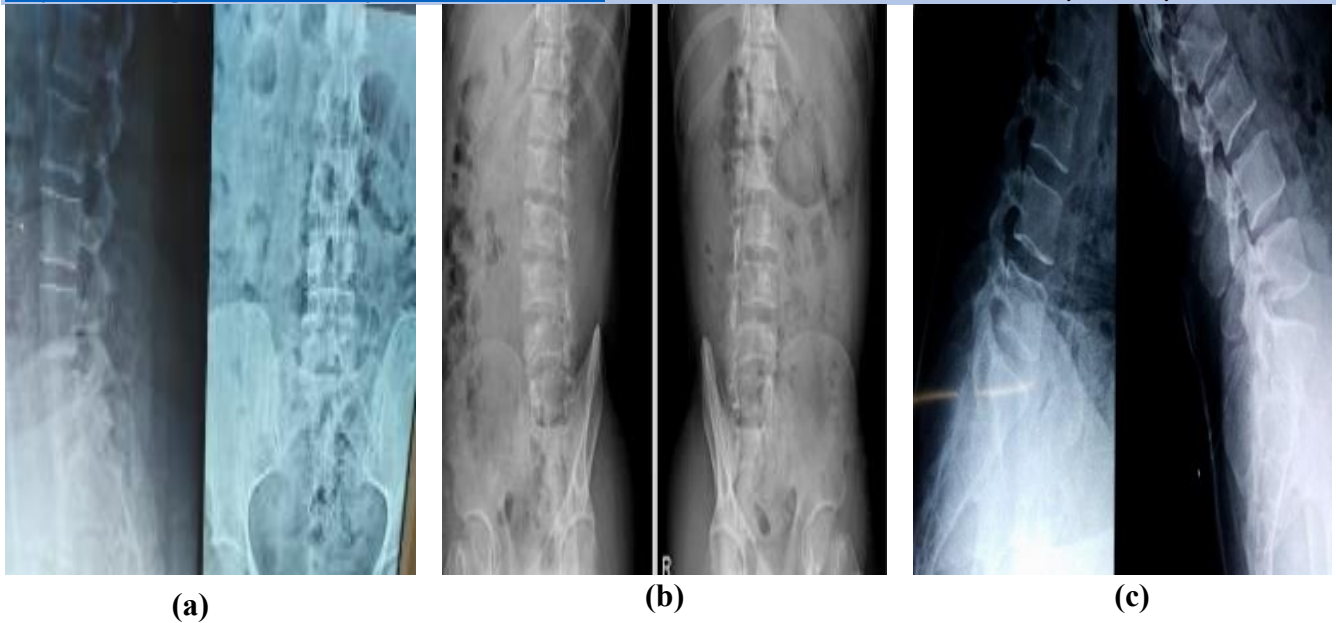
**Table 3:** Clinical evaluation of studied patients.

Time	Mean ± SD Range		
	VAS for low back pain	VAS for leg pain	DOI (%)
<b>Pre-operative</b>	6.9±2.2 0-10	5.3±1.5 2-8	56.25±6.5 46.7-66.7
<b>One-year post-operative</b>	2.9±1.0 1-5	2.3±1.1 0-5	46.6±4.5 40-53.3
<b>Two-years post-operative</b>	1.4±0.8 0-3	1.0±0.8 0-3	37.46±6.9 26.7-48.9
<b>Test statistics P1</b>	Z=-6.69 <0.001	Z=-7.01 <0.001	t=12.20 <0.001
<b>Test statistics P2</b>	Z=-6.95 <0.001	Z=-6.99 <0.001	t=16.90 <0.001
<b>Test statistics P3</b>	Z=-6.66 <0.001	Z=-6.49 <0.001	t=12.97 <0.001

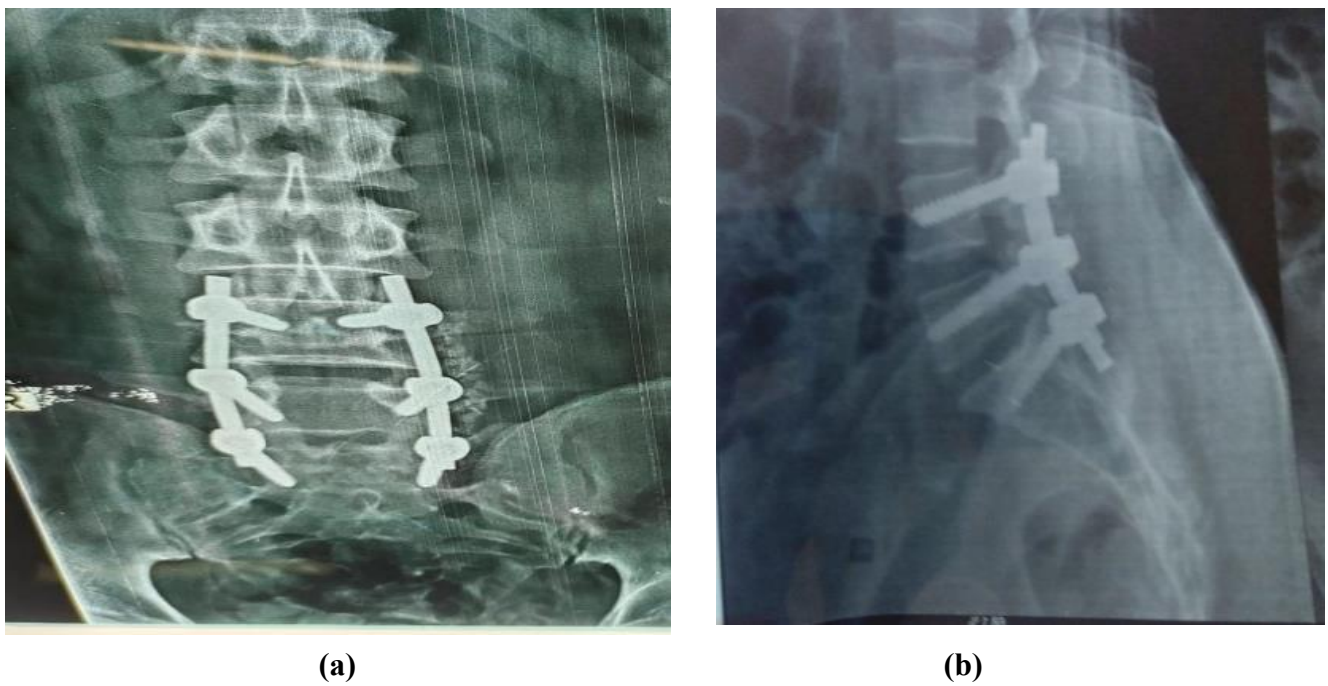
**Z:** Wilcoxon signed-rank test, **t:** Paired t-test, **P1:** for comparison between pre-op. and one-year post-op. **P2:** for comparison between pre-op. and two-years post-op., **P3:** for comparison between one-year post-op. and two-years post-op.



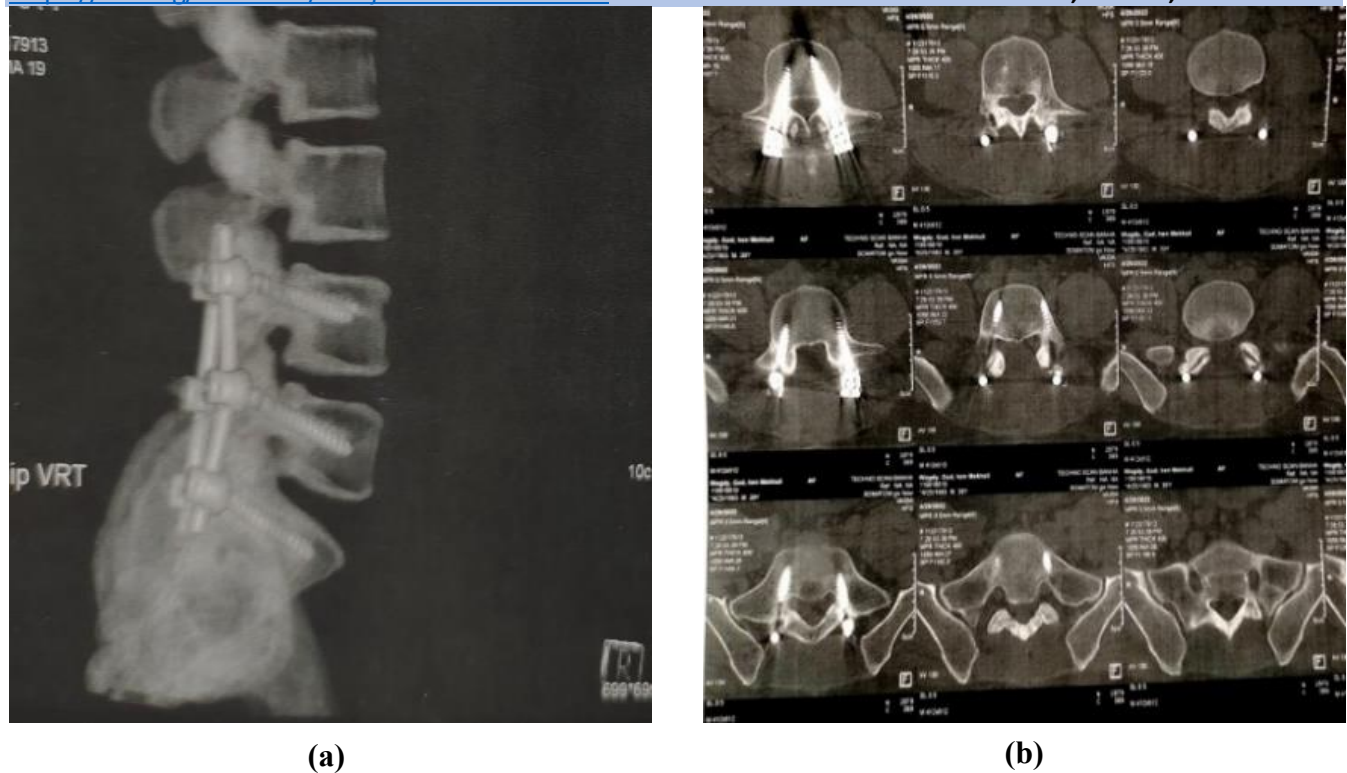
**Figure 1** showing, MRI LSS (a) sagittal T2-WI and (b) axial T2-WI showing L4-5 lumbar disc prolapse and L5-S1 diffuse disc bulge causing lumbar canal stenosis (central, and bilateral foraminal stenosis).



**Figure 2** showing, preoperative Plain X-ray LSS (a) anteroposterior and lateral, (b) Rt. and Lt. obliques, and (c) max. flexion-extension dynamics) views, showing no evidence of instability.



**Figure 3** showing, 2 years post-operative plain X-ray LSS (a) anteroposterior and (b) lateral views; showing transpedicular lumbar screw fixation of L4, L5, S1 by 6 titanium screws and 2 rods with posterolateral bone fusion and two levels wide canal decompression.



**Figure 4** showing, 2 years postoperative CT LSS (a) sagittal and (b) axial views; confirming good screws position with no signs of instability at the targeted segments because of instrumented fusion.

#### DISCUSSION

Degenerative lumbar canal Stenosis is considered as one of the most common indications for spine surgery [1]. There are multiple underlying pathological factors as fibrous tissue hyperplasia and facet joint arthropathy leading to diminution of the sagittal diameter of the spinal canal and/or nerve root foramina, causing clinical symptoms resulting from compression of the spinal nerve root or cauda equina [2]. Surgery is indicated after conservative management failure, there is no agreement about the exact period for conservative management. The aim of surgery is the decompression of the compromised neural structures [14].

Decompressive laminectomy is the gold standard and most commonly used technique for LCS for decades Since the first report by Lane in 1893 [15]. Posterior decompression of the stenotic lumbar spinal canal will reduce the pain caused by nerve pressure, however, the complete removal of the lamina and spinal process is associated with spine instability causing chronic pain, particularly in multi-segmental lumbar canal stenosis [16].

Conventionally to obtain adequate decompression of LCS, laminectomy is the most commonly used

technique removing the posterior elements, in spite of that, some studies documented the high rate of a second surgery after it as the patient after surgery may develop spinal instability and also weakness and atrophy of his muscles as a result of extensive removal of posterior stabilizing elements [9,10,11]. We remove all posterior structures including complete laminectomy medial facetectomy and bilateral foraminotomy in conventional laminectomy. This technique is associated with increased blood loss, increased hospital stays, and spinal instability [17].

In vitro and clinical studies showed that even with the preservation of the facet the removed posterior structures can destabilize this spinal segment and the patients probably need a second surgery for instrumented fusion. Bresnahan et al. used an in vitro model in a biomechanical study where they removed the posterior elements, they reported that the removed posterior structures at L4–L5 and L5–S1 levels caused an increase in flexion-extension and axial rotation at this site. and that minimally invasive techniques may prevent iatrogenic instability [18]. Minimal invasive lumbar decompression (MILD) preserves most of the posterior structures and so

stability of the spinal segment as proved by biomechanical studies and is associated with less blood loss and short postoperative hospital stay [19,20]. However, it has several potential drawbacks as reported in the literature as it has some limitations in achieving adequate wide decompression causing unsatisfactory clinical results [21,22].

Instability after lumbar decompression is one of the primary motivators of fusion performed in the index surgery, or during reoperations after lumbar decompression [23].

Segmental spinal stability compromised by the nature of the surgical approach, with the possibility of excessive motion when wider decompressions are done, greater ligamentous disruption occurs, or multiple levels are included [24]. In fact, instability is one of the most common indications for reoperation for stabilization following decompression laminectomy [25].

In the literature, The incidence of post-decompression instability is widely variable, ranging from 0% to 63% [26], Partly because of the lack of standardized radiographic criteria [27]. There was a higher incidence of reoperation for instability in patients with Lumbar spine stenosis when open decompression was performed (11%) compared with a minimally invasive decompression (0.7%,  $p < 0.001$ ) [28].

In our study, 64 patients underwent posterior decompression of two levels L4-5 and L5-S1 by laminectomy of L4 and L5 with instrumented posterolateral bone fusion using transpedicular fixation by 6 titanium screws and 2 rods. The mean age of our patients was  $54.4 \pm 6.8$  years, slightly younger than what was reported in the literature that the degenerative process of the lumbar spine begins at or after the seventh decade of life. We can explain that, as most of the included patients were heavy workers, those had to work to manage their life needs, so they had earlier degenerative lumbar changes. 42 females were included in our study representing 65.6% of our patients. In the literature, there is approval regarding gender differences in the incidence of symptomatic lumbar canal stenosis, and its incidence in females was found to be higher according to some studies [29].

One year and 2 years postoperative VAS for low back pain and leg pain significantly decreased in comparison to the preoperative values. Those changes in the VAS confirm the good clinical outcome in such surgical procedures tailored for our patients. And those results are comparable with the clinical trial of Sun C. et al., as they evaluated 113

patients with lower lumbar 2 or three levels degenerative LCS who underwent laminectomy with lumbar fixation and follow-up periods between 24-30 months and reported a significant decrease of VAS for both low back pain and for leg pain [30].

The preoperative mean ODI score was  $56.25 \pm 6.5\%$  that changed at one year postoperative to  $46.6 \pm 4.5\%$  and at 2years postoperative follow up the mean ODI score was  $37.5 \pm 6.9\%$  and we found those improvements in means regarding ODI recorded at 1 and 2 years postoperative highly significant and reflect the excellent functional outcome of the surgery, we found our results matching with the clinical outcome of the patients in Al dahshory et al., a clinical trial where their patients in the fusion group (25 patients) out of a total 50 patients included in their study had a preoperative mean ODI score of  $51.78 \pm 9.9$  which showed initial improvement after 6 months follow up to be  $38.08 \pm 8.42$  then more improvement was present after one-year post-operative to reach  $31.52 \pm 7.97$  [31].

Forsth et al. reported that adding fusion to the decompression is a subject of debate in patients without spinal instability; in their study from a total of 247 patients with degenerative LCS without spondylolisthesis, 135 patients underwent decompression with fusion, and they found no ODI difference between the groups who underwent decompression alone and who had added fusion after 2years post-operative [32].

The average blood loss in our study was  $353.7 \pm 115.9$  ml, this volume is lower than that of Sun C. et al that was  $563.0 \pm 96.83$ ml in laminectomy with lumbar fixation. [30] Aldahshory et al., compared between simple decompression versus adding instrumented fusion and reported that; a mean of 422 ml blood loss was present in the fusion group compared to 298 ml in the simple decompression group, which is lower, but this difference had no statistical significance [31].

Our operative time ranged from 200 to 260 minutes with a mean of  $222.6 \pm 20.1$  minutes. In a clinical trial by Sun C. et al., performing a similar procedure of multi-level lumbar canal decompression with transpedicular screw fixation for patients with lower lumbar two or three levels of degenerative LCS, the mean operative time was  $198 \pm 16$  minutes [31]. Aldahshory et al. reported that their operative time in the classic laminectomy with transpedicular screw fixation ranged from 2 to 6 hours [32]. We found our operative time is in accordance with both.

The length of hospital stays in our study ranged from 2-15 days with a mean of  $3.25 \pm 1.8$  days, we found



that is comparable with the results of Al dahshory et al., with a range from 3–16 days and a mean of 5.56 days and they reported that the more prolonged hospital stay with the fixation group is accepted even with the statistically significant difference when compared with simple laminectomy group but this stay still did not affect the final clinical outcome, they said [31].

In our study, two patients had an unintended dural tear representing 3.12% and we did intraoperative watertight closure with no post-operative CSF leak. In Al dahshory trial, the accidental dural tear occurred in only one patient in the laminectomy with the fusion group (25 patients) representing 4% while in the laminectomy group (25 patients) they had four patients with accidental dural tears representing 16% [31].

Sun C. et al., compared between lumbar decompression with fusion and simple decompression in patients with two or three levels of degenerative LCS, and they concluded that; hospital stays were prolonged, and the bleeding increased in decompression with the fusion group when compared to those of the simple decompression group and reported that they had no statistically significant difference in wound complications between both [30].

The main limitations of this study were the relatively small number of patients included and short-term follow up and these are to be considered in future studies.

### CONCLUSIONS

We hereby recommend classic laminectomy of L4 and L5, with or without one level discectomy with instrumented posterolateral fusion of L4,5, S1 regarding the significant pain reduction and excellent functional outcome without perioperative major complications to avoid the high possibility of spine instability and the need for second surgery with added risk and cost that may follow posterior decompression alone in such cases.

**Conflict of interest:** None.

**Financial Disclosures:** None.

### REFERENCES

1. Jia L, Yang L. Modern surgical concept of degenerative lumbar spinal stenosis. *Chin J Orthop.* 2002; (8): 509.
2. Szpalski M, Gunzburg R. Lumbar spinal stenosis in the elderly: An overview. *Eur Spine J.* 2003; 12 (Suppl 2): S170–5.
3. Lee SY, Kim TH, Oh JK, Lee SJ, Park MS. Lumbar stenosis: A recent update by review of literature. *Asian Spine J.* 2015; 9 (5): 818–28.
4. Allegri M, Montella S, Salici F, Valente A, Marchesini M, Compagnone C, et al. Mechanisms of low back pain: A

- guide for diagnosis and therapy. *F1000Res.* 2016; 5: F1000.
5. Schroeder GD, Kurd MF, Vaccaro AR. Lumbar spinal stenosis: How is it classified?. *J Am Acad Orthop Surg.* 2016; 24 (12): 843–52.
6. Kovacs FM, Urrútia G, Alarcón JD. Surgery versus conservative treatment for symptomatic lumbar spinal stenosis: A systematic review of randomized controlled trials. *Spine (Phila Pa 1976)* 2011; 36 (20): E1335–51.
7. Zaina F, Tomkins-Lane C, Carragee E, Negri S. Surgical versus nonsurgical treatment for lumbar spinal stenosis. *Spine (Phila Pa 1976)* 2016; 41 (14): E857–68.
8. H.W. Bae, S.S. Rajaei, L.E. Kanim. Nationwide trends in the surgical management of lumbar spinal stenosis. *Spine (Phila Pa 1976)* 2013; 38 (11): 916-26.
9. Alimi M, Hofstetter CP, Torres-Campa JM, Navarro-Ramirez R, Cong GT, Njoku I, et al. Unilateral tubular approach for bilateral laminotomy: effect on ipsilateral and contralateral buttock and leg pain. *Eur. Spine J.* 2017; 26 (2): 389-96.
10. Boehm H, Greiner-Perth R, El-Saghir H, Allam Y. A new minimally invasive posterior approach for the treatment of cervical radiculopathy and myelopathy: surgical technique and preliminary results. *Eur. Spine J.* 2003; 12: 268-73.
11. Wu AM, Zheng YJ, Lin Y, Wu YS, Mao FM, Ni WF, et al. Transforaminal decompression and interbody fusion in the treatment of thoracolumbar fracture and dislocation with spinal cord injury. *PLoS One* 2014; 9 (8): e105625.
12. Deyo RA, Martin BI, Kreuter W, Jarvik JG, Angier H, Mirza SK Revision surgery following operations for lumbar stenosis. *J Bone Joint Surg Am.* 2011; 93 (21): 1979-86.
13. Fairbank JC, Pynsent PB. The Oswestry disability index. *Spine (Phila Pa 1976)* 2000; 25 (22): 2940–52.
14. Ammendolia C, Stuber KJ, Rok E, Rampersaud R, Kennedy CA, Pennick V, et al. Nonoperative treatment for lumbar spinal stenosis with neurogenic claudication. *Cochrane Database Syst Rev.* 2013; (8): CD010712.
15. Lane A. Case of spondylolisthesis associated with progressive paraplegia; laminectomy. *Lancet* 1893; 141 (3635): 991-2.
16. Jacobs WC, Rubinstein SM, Willems PC, Moojen WA, Pellisé F, Oner CF, et al. The evidence on surgical interventions for low back disorders, an overview of systematic reviews. *Eur Spine J.* 2013; 22 (9): 1936-49
17. Phan K, Mobbs RJ. Minimally invasive versus open laminectomy for lumbar stenosis: A systematic review and meta-analysis. *Spine (Phila Pa 1976)* 2016; 41 (2): E91–100.
18. Ishimoto Y, Yoshimura N, Muraki S, Yamada H, Nagata K, Hashizume H, et al. Prevalence of symptomatic lumbar spinal stenosis and its association with physical performance in a population-based cohort in Japan: The Wakayama Spine Study. *Osteoarthritis Cartilage.* 2012; 20 (10): 1103–8.
19. Lee MJ, Bransford RJ, Bellabarba C, Chapman JR, Cohen AM, Harrington RM, et al. The effect of bilateral laminotomy versus laminectomy on the motion and

- stiffness of the human lumbar spine: A biomechanical comparison. *Spine (Phila Pa 1976)* 2010; 35 (19): 1789–93.
20. Ho YH, Tu YK, Hsiao CK, Chang CH. Outcomes after minimally invasive lumbar decompression: A biomechanical comparison of unilateral and bilateral laminotomies. *BMC Musculoskelet. Disord.* 2015; 16: 208.
  21. Min SH, Yoo JS. The clinical and radiological outcomes of multilevel minimally invasive transforaminal lumbar interbody fusion. *Eur Spine J.* 2013; 22 (5): 1164–72.
  22. Phan K, Mobbs RJ. Minimally invasive versus open laminectomy for lumbar stenosis: a systematic review and meta-analysis. *Spine (Phila Pa 1976)* 2016; 41 (2): E91–E100
  23. Javalkar V, Cardenas R, Tawflk TA, Khan IR, Bollam P, Banerjee AD, et al. Reoperations after surgery for lumbar spinal stenosis. *World Neurosurg.* 2011; 75 (5-6): 737–42.
  24. Lee KK, Teo EC, Qiu TX, Yang K. Effect of facetectomy on lumbar spinal stability under sagittal plane loadings. *Spine (Phila Pa 1976)* 2004; 29 (15): 1624–31.
  25. Martin BI, Mirza SK, Comstock BA, Gray DT, Kreuter W, Deyo RA. Reoperation rates following lumbar spine surgery and the influence of spinal fusion procedures. *Spine (Phila Pa 1976)* 2007; 32 (3): 382–7.
  26. Arai Y, Hirai T, Yoshii T, Sakai K, Kato T, Enomoto M, et al. A prospective comparative study of 2 minimally invasive decompression procedures for lumbar spinal canal stenosis: unilateral laminotomy for bilateral decompression (ULBD) versus muscle-preserving interlaminar decompression (MILD). *Spine (Phila Pa 1976)* 2014; 39 (4): 332–40.
  27. Yone K, Sakou T. Usefulness of Posner's definition of spinal instability for selection of surgical treatment for lumbar spinal stenosis. *J Spinal Disord.* 1999; 12 (1): 40–4.
  28. Guha D, Heary RF, Shamji MF. Iatrogenic spondylolisthesis following laminectomy for degenerative lumbar stenosis: systematic review and current concepts. *Neurosurg Focus* 2015; 39 (4): E9.
  29. Alebshehy R, Shuaib NM, Mbako JD, Barffo D, Nuotol RK. Determinant analysis of obesity among adult females in Egypt. *Egypt J Hosp Med.* 2016; 65 (1): 662–9.
  30. Sun C, Tian WJ, Liu HX, Guan PG. Outcomes of multisegmental transforaminal enlarged decompression plus posterior pedicle screw fixation for multilevel lumbar spinal canal stenosis. *Int J Surg.* 2018; 50: 72–8.
  31. Al dahshory AR, Mashaly H, EL Molla ST, Ismaiel IA, Saoud K. Comparative Study of Minimally Invasive Lumbar Decompression versus Decompressive Laminectomy with Posterolateral Transpedicular Fixation for the Treatment of Degenerative Lumbar Canal Stenosis. *Asian J. Neurosurg.* 2020; 15 (2): 293–301.
  32. Forsth P, Ólafsson G, Carlsson T, Frost A, Borgström F, Fritzell P, et al. A randomized, controlled trial of fusion surgery for lumbar spinal stenosis. *N. Engl. J. Med.* 2016; 374 (15): 1413–23.

### To Cite:

**zaghloul, A., Deabes, A., Mourad, M., Elmeleigy, S. Outcome of Decompression with Transpedicular Screw Fixation and posterolateral fusion in Stable Degenerative Lower Lumbar Canal Stenosis. *Zagazig University Medical Journal*, 2024; (307-316): -. doi: 10.21608/zumj.2022.151612.2605**