



ISSN: 2141 -  
3290

**EFFECTS OF ACUTE EXPOSURE TO CHLORFENAPYR ON HEPATIC ENZYME  
ACTIVITIES AND SERUM LIPID PROFILE OF AFRICAN CATFISH,  
*Clarias gariepinus* (BURCHELL 1822)**



ESENOWO, I.K.<sup>1\*</sup>, NELSON, A.U.<sup>2</sup>, EKPO, N.D.<sup>1</sup>, CHUKWU, M.N.<sup>3</sup>, AKPAN, A.U.<sup>1</sup>,  
UGWUMBA, A.A.A.<sup>4</sup>, UGWUMBA, A.O.<sup>4</sup>, ALIMBA, C.G.<sup>4</sup>, EFFIONG, M.U.<sup>1</sup>, UDOIDUNG, N.I.<sup>1</sup>,  
UKPONG, N.C.<sup>1</sup>, OGIDIKA, E.<sup>5</sup>, ADEYEMI-ALE, O. A.<sup>6</sup>, OBOHO, D.E.<sup>1</sup>.

<sup>1</sup>Department of Animal and Environmental Biology, Faculty of Science, University of Uyo, Nigeria

<sup>2</sup>Department of Animal Science, Faculty of Agricultural Science, Federal Polytechnic, Ugep, Cross River State, Nigeria.

<sup>3</sup>Department of Pure and Applied Sciences, Faculty of Science, National Open University of Nigeria

<sup>4</sup>Department of Zoology, University of Ibadan, Nigeria

<sup>5</sup>Department of Science and Technology, fisheries and Fisheries Technology Option,  
Delta State School of Marine Technology, Burutu, Delta State.

<sup>6</sup>Department of Zoology, University of Ilorin, Nigeria

\*Corresponding author's email: [imehesenowo@gmail.com](mailto:imehesenowo@gmail.com)

### ABSTRACT

The effects of acute exposure to chlorfenapyr on hepatic enzymes and lipid profile of *Clarias gariepinus* juveniles were investigated following standard protocols. Test organisms were exposed to chlorfenapyr concentrations of 5, 7, 9, 11 and 15 mgL<sup>-1</sup> for 96 hr exposure period. After exposure, peripheral blood was collected through the caudal vein into plain sterilised tubes and allowed stand for 1 h for clot to form. The clotted blood was then centrifuged at 3000 rpm for 10 min and the serum obtained was used for all the biochemical assay. Cross-sections of the gills were examined for histological aberrations. Results showed significant increase in enzymatic activities of Aspartate amino transferases (AST), Alanine amino transferases (ALT) and Alkaline phosphatase (ALP) (p< 0.05) when compared with control. Lipid profile results showed significant (p<0.05) increase in Total cholesterol (TC) and Low- density lipoprotein-cholesterol (LDL-cholesterol) in all treated groups when compared with the control. Significant (p<0.05) reduction in high density lipoprotein- cholesterol (HDL-cholesterol) and triacylglycerides in all treated groups compared to the control was also recorded. Such alterations in biochemical parameters did not show any relationship with gills histology as the cross-section of the gills provided no evidence of aberrations. The results suggest that exposure to acute concentrations of chlorfenapyr can alter liver enzyme activities and serum lipid profile initiating a jump in the energy requirement of the exposed organism.

**KEYWORDS:** Chlorfenapyr, hepatic enzymes, Lipid profile, *Clarias gariepinus*

### Introduction

Pesticides are used extensively in salvaging households from pest infestations and improving yields in agriculture; and these have brought both beneficial and detrimental impacts to the environment (Aktar *et al.*, 2009; Muyesaier *et al.*, 2021). Pesticide residue, which can affect different non-target aquatic organisms can reach aquatic ecosystem through various routes and these includes run-off, direct application, spray-drift, leaching, indiscriminate discharge from factories and sewage (Barlas 1999; Katagi 2010). Through the food web, these pesticides can bioaccumulate and get transferred from planktons (producers) through fish (primary consumer) and ultimately to humans (tertiary consumer). According to Matagi *et al.* (1998), fin and shell fishes directly absorb toxicants deposited within aquatic environment using their gills and other exposed bio-membranes. Pesticide may significantly damage certain physiological and biochemical processes when they enter into the organs of fishes, affecting their growth, survival and reproduction (Banaee *et al.*, 2008, 2011; Mhadi, 2012). It is also reported that long-term exposure to pesticide can increase stress in juvenile aquatic organisms, thereby rendering them prone to predation (Ewing, 1999).

Due to their persistence in the environment and resistance posed by several targeted pest species, many pesticides (including the organochlorides, organophosphates,

carbamates and pyrethroids) have met with criticisms (Ansari *et al.*, 2011). Such criticisms have led to the synthesis of new chemical pesticides perceived to be more potent and more environmentally friendly. One of such newly developed pesticide is the insecticide, chlorfenapyr (chemical formula C<sub>15</sub>H<sub>11</sub>BrClF<sub>3</sub>N<sub>2</sub>; melting point of 101.4 – 102.3°C), a member of the class known as pyrroles (Black *et al.*, 1994; Raghavendra *et al.*, 2011). According to Ingham *et al.* (2012), it was considered a suitable alternative to synthetic pyrethroids due to a lower toxicity to mammalian and aquatic life. It is a pro-insecticide, which requires activation in *in vivo* by mixed function oxidative elimination of its N-ethoxymethyl group to produce the active compound, disrupting respiratory pathways and proton gradients via uncoupling the mitochondrial oxidative phosphorylations, and interrupting the conversion of ADP to ATP (Black *et al.*, 1994). According to WHO criterion, chlorfenapyr molecule has low mammalian toxicity and is classified as a slightly hazardous insecticide (Tomlin, 2000). It is used in controlling mites and insects (e.g. termites and mosquitoes) (Sheppard *et al.*, 1998; Kamaraju *et al.*, 2011). Unfortunately, pesticides developed to be as much as possible, specific and selective in action against target organisms, rarely achieve their purposes without the wider environment being exposed and susceptible non-target organisms getting affected (Malik *et al.*, 2008). For instance,

chlorfenapyr has been shown to increase glutathione S-transferase in the freshwater protozoan, *Paramecium* sp. (Benbouzid *et al.*, 2015) indicating induction of free radicals in this aquatic fauna; and significant reduction in fecundity in *Geocoris punctipes* by this chemical has also been reported (Elzen and Elzen, 1999). Based on the observations of Zhao and Mu (2018), low lethal concentrations of this pesticide can affect oviposition, population development, digestive activities, detoxification enzymes and nutrients accumulation in *Bradysia doriphaga*.

Fishes change and adapt to their metabolic functions during acute stress conditions (Malarvizhi *et al.*, 2012). Such adaptations have been realized through alterations in biochemical markers studied as indicators of tissue damage (Webb *et al.*, 2005). Sub-lethal effects of stressors (e.g. pesticides) in fishes can be indicated by significant increase or decrease in enzymatic activities (Harabawy *et al.*, 2014). The liver serves as the main organ of various essential metabolic pathways; hence, adversely affected by chemicals. Foreign compounds are predominantly biotransformed in the liver by the action of metabolizing enzymes including microsomal enzymes, aminotransferases and oxygenases (Stickel *et al.*, 2005). Thus, the liver has a high metabolic flexibility in response to enzyme induction to a variety of metabolites as well as the capacity to regulate the expression of genes coding for the biosynthesis of such enzymes. The disruption of the integrity of biochemical and physiological processes in fish has been monitored by determining the changes in the activities of enzymes in plasma/serum and tissues of the gill, brain, liver, muscle and kidney of the fish (de laTorre *et al.*, 2005; Ayalogu *et al.*, 2001; Gabriel and George, 2005; Leelanvinonthan and Amali, 2005). The liver marker enzymes of common interest are the transaminases: alanine transaminase (ALT), aspartate transaminase (AST) and alkaline phosphatase (ALP).

In addition, there are reports indicating that exposures to environmental stressors such as pesticides have resulted in alteration of the lipid profile of fishes (Hammed *et al.*, 2013). Lipid profile are good indicators of an organism's likelihood of developing cardiovascular attack as a result of blockage of the blood vessels or hardening of the arteries (atherosclerosis). The lipid profile frequently assayed include total cholesterol (TC), high density lipoprotein cholesterol (HDL-C), low density lipoprotein cholesterol (LDL-C) and triglycerides. Nevertheless, sometimes an extended profile may include very low-density lipoprotein cholesterol (VLDL-C) and non-HDL-C.

Furthermore, such toxic effects can be assayed through morphological aberrations of histological sections of some organs. Exposure and bioaccumulation of pesticides in sensitive organs such as the liver and gills of a fish may cause histological injuries thus leading to physiological disruptions; and such histological injuries are reflected in the histological sections of the organ (Xing *et al.*, 2012; Banaee *et al.*, 2014; Maksymiv *et al.*, 2015; Adel *et al.*, 2017; Ghelichpour *et al.*, 2017; Hoseini and Yousefi, 2019).

Histopathological alterations of tissues have been commonly used along with biochemical biomarkers in assessing the health of fish exposed to pollutants *in situ* or *ex situ*; and by extension, deciphering the overall health status of the entire aquatic ecosystem (Drishya *et al.*, 2016; Olaniyi, 2020). Although there is deluge of studies on the effect of pesticides on aquatic organisms, limited studies exist on the sub-lethal effect of chlorfenapyr insecticides on fishes. The aim of this study was to investigate the effect of chlorfenapyr on the activities of liver enzymes and lipid profile of African mud catfish (*Clarias gariepinus*). Additionally, the histological section of the gills was analysed to assay the extent of toxicity caused by the chemical on the fish. *Clarias gariepinus* was selected because it is readily and widely available. It is ecologically important as it serves as effective biomarker to changes in the state of the aquatic environment and can survive under laboratory conditions.

## Materials and Methods

### Fish Collection and acclimatization

Three hundred juvenile species of *C. gariepinus* Juveniles (Burchell, 1822) (Family: Clariidae, Order: Siluriformes) with an average weight of 172.6 g were procured from a local fish farm in Abak Local Government Area and were transported in well-aerated, open plastic container of fresh water to the Department of Animal and Environmental Biology Laboratory, University of Uyo. The fish were kept in transparent plastic tanks filled with dechlorinated tap water and made to acclimatize in laboratory conditions for two weeks. They were fed *ad libitum* with commercial feed (Coppens commercial feed, Coppens International Helmond, Netherlands) containing 40% crude protein. To maintain hygiene, the water was renewed every 24 h to prevent the accumulation of metabolic wastes and unconsumed food particles.

### Experimental Procedure and preparation of stock solutions

After the period of acclimation, the fish were randomly distributed into six plastic aquaria (56 x 28 x 28cm) which were designated as 1 - 6. The control group of fish was kept in aquarium 1 while aquaria 2 - 6 contained the test group of fish reared in water contaminated with varying concentrations of chlorfenapyr. The concentrations were prepared following standard protocol as described in a previous study by Esenowo *et al.* (2021). Each aquarium was made to hold ten fishes in 10 L of dechlorinated water. The experiment lasted for 96 hrs. After completion of treatment, the test animals were removed from aquaria, washed with water, and sacrificed. Feeding of the fishes was stopped 24 hours before the start of the test (Sprague, 1972).

### Blood collection, serum preparation and biochemical analysis

After sacrifice, blood was collected through the caudal vein, stored in plain sterile tubes and allowed to stand for 1 hr to clot. The clotted blood samples were centrifuged at 3000 rpm for 10 min to separate the serum. The serum was used for all biochemical assays. The enzymic activities of alanine

transaminase (ALT), aspartate transaminase (AST) and alkaline phosphatase (ALP) in the serum were measured using kits purchased from Randox Laboratories Limited, United Kingdom (UK). The ALT activity was measured by monitoring the concentration of pyruvate hydrazine formed with 2,4-dinitrophenylhydrazine at 546 nm.

AST activity was measured by monitoring the concentration of oxaloacetate hydrazine formed with 2,4-dinitrophenylhydrazine at 546 nm.

ALP was determined by measuring the increase in absorbance due to increase in the formation p-nitrophenol reaction in the sample at 405 nm.

Serum total cholesterol was estimated using automatic serum chemistry auto analyser and kit (AUTOPAK supplied by Beyer Diagnostics India) by the enzymatic (Cholesterol Esterase, Cholesterol Oxidase and Peroxidase method of Allain *et al.* (1974). Results obtained were expressed as mgdl<sup>-1</sup> of serum.

Serum Triglycerides estimation was carried out with the use of the automatic serum analyser and kit (AUTOPAK, Bayer Diagnostics India) by the enzymatic Lipoprotein lipase, Glycerol kinase, Glycerol-3-Phosphate Oxidase method of McGowan *et al.* (1983). Results are expressed as mgdl<sup>-1</sup> of serum.

Serum high density lipoprotein-cholesterol (HDL-cholesterol) was estimated using the automatic serum analyser and kits (AUTOPAK, Bayer Diagnostics India) by the phosphotungstate method. Results obtained were expressed as mgdl<sup>-1</sup> of serum.

Very Low-Density Lipoprotein-Cholesterol (VLVD-cholesterol) in serum was estimated using the Friedewald formula (Friedewald *et al.*, 1972).

$$\text{VLVD-Chol} = \text{Serum triglycerides} \div 5$$

The results obtained are expressed as mgdL<sup>-1</sup> of serum.

The serum Low Density Lipoproteins cholesterol (LDL-cholesterol) was estimated mathematically as the difference between the serum totalcholesterol and the sum of the Very Low-Density Lipid cholesterol and the High-Density Lipid cholesterol according to the Friedwald formula (Friedewald *et al.*, 1972).

$$\text{LDL-Chol (mg/dL serum)} = \text{Total Chol} - (\text{VLDL-Chol} + \text{HDL-Chol}).$$

### Histopathological Analysis

For this investigation, gills samples were immediately collected from sacrificed animals and rinsed with saline solution (0.9% NaCl) to remove blood mucus and debris and fixed in 10% formaldehyde. The tissues were dehydrated through a graded alcohol series. The dehydrated tissues were cleared in xylene and then embedded in paraffin wax. Tissue sections were cut at 5 µm using a rotary microtome and stained with hematoxylin and eosin. The prepared slides were analyzed under an Olympus optical microscope and

photographed at 40x and 100x magnifications.

### Statistical analysis

Data obtained from the experiments were collated and subjected to ANOVA using MS Office Excel Package, version 10 and the differences among means tested at p<0.05. Results were expressed as means ± standard deviation using tables and charts.

## Results

### Biochemical analysis

The results of the effect of exposure to chlorfenapyr on the liver enzymes of *Clarias gariepinus* are presented in Fig.1. As shown on the chart, activities/levels of AST, ALT and ALP were elevated following exposure to different concentrations of the insecticide when compared with what was recorded for the control. However, this increase in activities was not completely dose dependent as highest values of the enzymes were recorded at 7 mg/l of the toxicant whereas exposure to higher concentrations of the toxicant witnessed a reduction in the activities/levels of the liver enzymes when values were compared to what was recorded for the fish treated with 7mg/l of the toxicant.

The results of lipid profile presented in Table 1 revealed significant (p<0.05) alterations in the lipid profile of the fish when groups exposed to the toxicant (test groups) were compared to those that were free of the toxicants (control group); and even comparison amongst the test groups revealed significant (p<0.05) alterations. Levels of total cholesterol in the fish from the test group was significantly (p<0.05) higher in the groups treated with the toxicant when compared to what was recorded for those in the control group. LDL-cholesterol showed a similar trend. HDL-cholesterol and triacylglycerides were significantly (p<0.05) reduced in the chlorfenapyr treated groups when compared to those in the control group. Comparison amongst the treated groups showed alterations which were dose dependent and were significant (p<0.05) when mean values were compared for all the parameters except for Triacylglycerides where mean values for groups 2 and 3 as well those of groups 4 and 5 showed no significant (p>0.05) differences.

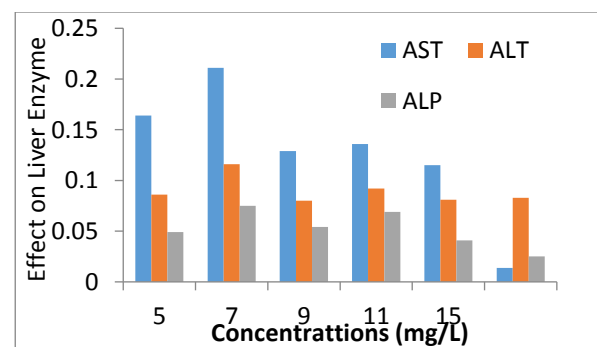


Figure 1: Effect of chlorfenapyr on Liver Enzymes of *Clarias gariepinus*

Table 1: Effect of chlorfenapyr insecticide on the serum lipid profile of *Clarias gariepinus* juveniles following 96hr exposure.

Experimental Groups	Total Cholesterol (Mg/dl)	HDL-Cholesterol (Mg/dl)	Triacylglycerides (Mg/dl)	LDL-Cholesterol (Mg/dl)
Group 1 (Control)	148.76 ± 0.18	101.30 ± 0.28	201.10 ± 7.35	48.14 ± 0.67
Group 2	153.38 ± 0.42 <sup>a</sup>	56.02 ± 1.29 <sup>a</sup>	174.61 ± 2.85 <sup>a</sup>	98.00 ± 0.36 <sup>a</sup>
Group 3	172.30 ± 1.59 <sup>a,b</sup>	37.56 ± 0.89 <sup>a,b</sup>	176.76 ± 1.67 <sup>a</sup>	104.18 ± 1.45 <sup>a,b</sup>
Group 4	192.22 ± 2.04 <sup>a,b,c</sup>	30.34 ± 0.63 <sup>a,b,c</sup>	161.72 ± 1.19 <sup>a,b,c</sup>	110.26 ± 0.87 <sup>a,b,c</sup>
Group 5	242.34 ± 0.75 <sup>a,b,c,d</sup>	23.78 ± 0.73 <sup>a,b,c,d</sup>	161.35 ± 0.79 <sup>a,b,c</sup>	120.08 ± 0.81 <sup>a,b,c,d</sup>
Group 6	261.10 ± 0.44 <sup>a,b,c,d,e</sup>	20.74 ± 1.07 <sup>a,b,c,d,e</sup>	150.10 ± 0.96 <sup>a,b,c,d,e</sup>	124.90 ± 0.88 <sup>a,b,c,d,e</sup>
P-value range	0.000	0.000	0.000 - 1.000	0.000

Values are expressed as Mean ± SD; N = 5

- a = p ≤ 0.05 (comparing values from other groups with that of the control)
- b = p ≤ 0.05 (comparing values from other groups with that of group 2)
- c = p ≤ 0.05 (comparing values from other groups with that of group 3)
- d = p ≤ 0.05 (comparing values from other groups with that of group 4)
- e = p ≤ 0.05 (comparing values from other groups with that of group 5)

### Histopathology result

The histological sections of the gills of *C. gariepinus* for the control and treatment groups are shown in fig. 2. In this study, there were no morphological anomalies throughout the experimental period.

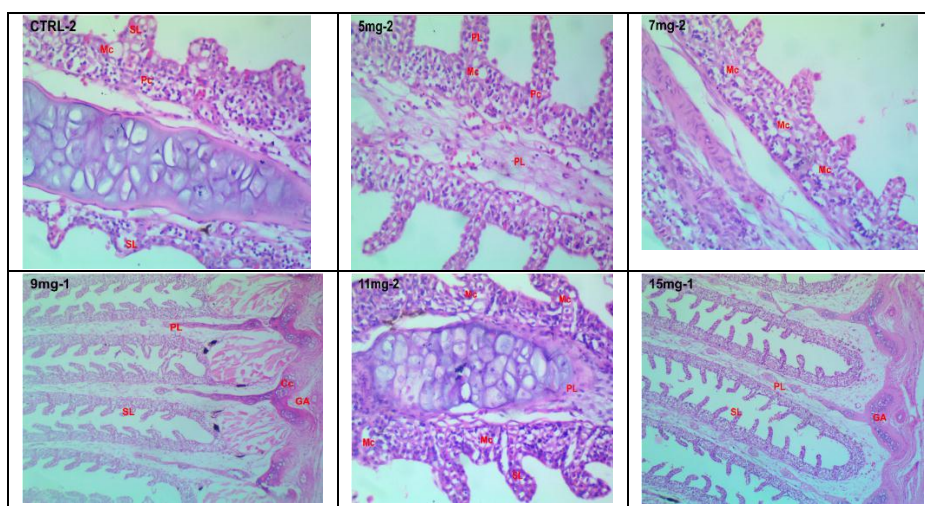


Fig. 2: Photomicrograph of the cross section of the gill of *C. gariepinus* showing: control (CTRL-2) group, H & E x100; 5 mg group, H & E x100; 7 mg group, H & E x100; 9 mg group, H & E x40; 11 mg group, H & E x100; 15 mg group, H & E x40. SL – Secondary lamellae; PL – Primary lamellae; GA – Gill arch cells; Pc – Pilaster (Pillar) cells; Mucous cells – Mc; Chloride cell (Cc)

### Discussion

Acute exposure of animals to toxicants may inflict stresses on the mechanisms required for maintaining a healthy physiological state. Several reports have shown that these stresses may result in changes in biochemical, physiological or behavioural processes as well as alterations in molecular patterns of the DNA in exposed organisms (Malarvizhi *et al.*, 2012; Harabawy *et al.*, 2014; Ghelichpour *et al.*, 2017; Ekpo *et al.*, 2018; Hoseini and Yousefi, 2019). In view of this, there has been increasing interest in examining the physiological and biochemical stress response in aquatic vertebrates to protect aquatic life. The liver is susceptible to

potential impairment by xenobiotics due to its function in accumulation, biotransformation, degradation, bioinactivation and excretion of contaminants as such, the evaluation of toxicity in animals is usually done through such path (Ross and Wilson, 2018). Alterations in the activities of the transaminases (AST and ALT) and ALP act as markers to illustrate compromised tissue integrity of the liver (Huculeci *et al.*, 2008; Firat *et al.*, 2011; Banaee, 2013). Such increases could be proportional to compromised cellular integrity resulting from potential increase of cell membrane permeability (Granner and Rodwell, 2006), hepatocellular damage (Bhattacharya and Lun, 2005; Joseph

and Raj, 2011), cholestasis and liver damage (Della Torre *et al.*, 2000). ALP adopts different mode of action, preferentially influenced by exposure dose and duration, to elicit responses to contaminants (Brander *et al.*, 2012; Sun *et al.*, 2007). In our study, there was a significant increase in the activities of AST, ALT and ALP in comparison with the control. Additionally, there are reports indicating that exposures to environmental stressors such as pesticides have resulted in alteration of the lipid profile of fishes (Hammed *et al.*, 2013). Lipid profile are good indicators of an organism's likelihood of developing cardiovascular attack as a result of blockage of the blood vessels or hardening of the arteries (atherosclerosis). The lipid profile frequently assayed include total cholesterol (TC), high density lipoprotein cholesterol (HDL-C), low density lipoprotein cholesterol (LDL-C) and triglycerides.

In this study, exposure to chlorfenapyr elicited stress actions that precipitated elevated levels/activities of liver enzymes and serum lipid profile in all treated groups when compared with what was recorded for the control. Previous researchers have documented reports of effect of chemicals on liver enzymes of *Clarias gariepinus*. Okonkwo *et al.* (2013) and Kumar *et al.* (2011) reported similar elevations in liver enzymes exposed to cypermethrin. These researchers had suggested that the elevated values in liver enzymes was due to the stepped-up transamination, where amino acids are used to generate intermediates for tricarboxylic acid cycle, in an attempt to handle the energy crisis during stress caused by the toxicants. Karami-mohajeri and Abdollahi (2011) also reported liver damage in *Clarias batrachus* exposed to phorate and carbaryl which was thought to be as a result of the production of lipolytic mitochondrial enzymes that dissolve cell membranes, lysosomal membranes and other hepatocellular organelles, thereby releasing liver enzymes into the blood. However, some of these exposures are long-term in order for observable changes in enzymic activities (Ayanda *et al.*, 2015). Also, the outcome of this present study showed an increase in total cholesterol and LDL-cholesterol level in the blood of test animals compared to their counterparts in the control group. On the other hand, Triacylglycerides and HDL-cholesterol recorded significant ( $p < 0.05$ ) reductions in all chlorfenapyr treated groups when compared with what was recorded for their counterparts in the control group. These alterations in lipid profile were observed to be dose dependent. This rise in cholesterol is an indication and probably suggests a general increase in lipid mobilization. Hypercholesterolemia observed may be due impairment of liver and inhibition of enzymes which convert cholesterol into bile acid (Murray, 1991). Reduced lipoprotein lipase activity plays a role in the increment of plasma lipid (Sharma and Agrawal, 2005). As recorded in Hammed *et al.* (2010), High density lipoproteins (HDLs) remove cholesterol from the walls of arteries, return it to the liver, and help the liver excrete it as bile while Low density lipoproteins (LDLs) transports cholesterol from the liver to the cells leaving plaque-forming cholesterol in the walls of the arteries, clogging the artery walls and setting the stage for heart disease. The higher amount of total cholesterol and

LDL-cholesterol is an indication of the chlorfenapyr's potential to impose cardiovascular health risk in *Clarias gariepinus*. This position is shared by several scholars (Filipiak, 1995; Hammed *et al.*, 2010; Hammed *et al.*, 2013).

In some cases, positive biochemical effects may not reflect positive histological damages. In our study, cross-sections of the gills were analysed to ascertain histological injury to sensitive organs. Gills were perfect for this analysis because they remain in close proximity to the external environment and respond rapidly to changes in the quality of water due to contaminants (Fernandes and Mazon, 2003; Camargo and Martinez, 2007). Our study showed that the histology of all test groups were not strongly altered compared to that of the control group. Although, the presence of mucous cells was well demonstrated at increased doses, there were no signs of degenerative, necrotic and proliferative changes in gill filaments and secondary lamellae in our study. According to Islam *et al.* (2019), lower concentrations of toxicants have no remarkable alterations in vital organs of treated organisms. We can infer that chlorfenapyr concentrations used in our study may pose no danger to the histology of the gills. This is not in agreement with histopathological studies with positive results under the influence of different pollutants recorded by several scholars (Kakuta and Murachi, 1997; Mohamed, 2009; Banaee *et al.*, 2013; Somdare *et al.*, 2015). Some notable pathological gill responses when in contact with contaminants include oedema with epithelial lifting and desquamation, telangiectasia, hyperplasia and hypertrophy of the epithelial cells (Giari *et al.*, 2007). These responses were not observable in our study.

## Conclusion

The results of the present investigation indicated that acute exposure of chlorfenapyr induced significant changes in the liver enzymes and lipid profile of *C. gariepinus*. This may infer that exposure to chlorfenapyr could pose deleterious consequences to the ecosystem and will definitely affect the survival of fish. On the contrary, the changes shown in the biochemical parameters in our study did not transmit to any observable aberrations in the histological parameters of the gills. Hence, further studies have to be carried out to evaluate the residual effects of this pesticide in other body tissues of fish in order to provide a better understanding of its physiological significance for a conclusive standpoint.

## References

- Abhijith, B. D., Ramesh, M. and Poopal, R. K. (2016). Responses of metabolic and antioxidant enzymatic activities in gill, liver and plasma of *Catlacatla* during methyl parathion exposure. *The Journal of Basic and Applied Zoology*, 77:31–40.
- Adel M., Dadar M., Khajavi S. H., Pourgholam R., Karimí B. and Velisek J. (2017). Hematological, biochemical and histopathological changes in Caspian brown trout (*Salmo trutta caspius* Kessler, 1877) following exposure to sub-lethal concentrations of chlorpyrifos. *Toxin Reviews*, 36 (1):73 –79.

- Aktar, W., Sengupta, D. and Chowdhury A. (2009). Impact of pesticides use in agriculture: Their benefits and hazards. *Interdisciplinary Toxicology*, 2:1–12.
- Allain, C. C., Poon, L. S., Chen, C. S., Richmond, W. and Fu, P. C. (1974) Enzymatic Determination of Total Serum Cholesterol. *Clinical Chemistry*, 20, 470-475.
- Ansari, R. A., Rahman, A., Kaur, M., Anjum, S. and Raisuddin, S. (2011). In vivo cytogenetic and oxidative stress-inducing effects of cypermethrin in freshwater fish, *Channapunctata* (Bloch). *Ecotoxicology and Environmental Safety*, 74 (1): 150–156.
- Ayanda, O. I., Oniye, S. J., Auta, J. A., Ajibola V. O. and Bello O. A. (2015). Responses of the African catfish *Clarias gariepinus* to long-term exposure to glyphosate- and paraquat-based herbicides, *African Journal of Aquatic Science*, 40 (3): 261-267.
- Banaee M., Physiological Dysfunction in Fish After Insecticides Exposure, Insecticides - Development of Safer and More Effective Technologies, Available from: Stanislav Trdan, Intech Open, 2013 <https://www.intechopen.com/books/insecticides-development-of-safer-and-more-effective-technologies/physiological-dysfunction-in-fish-after-insecticides-exposure>.
- Banaee, M. Mirvaghefi, A.R. Ahmadi, K. and Ashori, R. (2009). The effect of diazinon on histopathological changes of testes and ovaries of common carp (*Cyprinus carpio*). *Scientific Journal of Marine Biology*, 1(2): 25-35.
- Banaee, M. Mirvaghefi, A.R. Ahmadi, K. and Banaee, S. (2008). Determination of LC<sub>50</sub> and investigation of acute toxicity effects of diazinon on hematology and serology indices of common carp (*Cyprinus carpio*). *Journal of Marine Science and Technology Research*, 3(2): 1-10.
- Banaee, M. Sureda, A. Mirvaghefi, A. R. and Ahmadi, K. (2011). Effects of diazinon on biochemical parameters of blood in rainbow trout (*Oncorhynchus mykiss*). *Pesticide Biochemistry and Physiology*, 99: 1-6.
- Banaee, M., Haghi, B. N. and Ibrahim, A. T. A. (2014). Sub-lethal toxicity of chlorpyrifos on Common carp, *Cyprinus carpio* (Linnaeus, 1758): biochemical response. *International Journal of Aquatic Biology*, 1, 281–288.
- Banaee, M., Sureda, A., Mirvaghefi, A.R. and Ahmadi, K. (2013). Histopathological Alterations Induced by Diazinon in Rainbow trout (*Oncorhynchus mykiss*) *International Journal of Environmental Research*, 7(3):735-744.
- Barlas N. E. (1999). Determination of organochlorine residues in aquatic systems and organisms in upper Sakarya Basin Turkiye. *Bulletin of Environmental Contamination and Toxicology*. 62:278–285.
- Benbouzid H., Berrebba H. and Djebar M. R (2015). Toxicity of the Chlorfenapyr. Growth inhibition and induction of oxidative stress on a fresh water protozoan: *Paramecium* sp. *Advances in Environmental Biology*, 9 (3): 281-285.
- Black, B. C., Hollingworth, R. M., Ahmmadsahib, K. I., Kukel, C. D., Donovan, S. (1994). Insecticidal action and mitochondrial uncoupling activity of AC-303,630 and related halogenated pyrroles. *Pesticide Biochemistry and Physiology*, 50 (2): 115–128.
- Brander, S. M., He, G., Smalling, K. L., Denison, M. S. and Cherr, G. N. (2012). The in vivo estrogenic and in vitro anti-estrogenic activity of permethrin and bifenthrin. *Environmental Toxicology and Chemistry*, 31: 2848–2855.
- Camargo, M. M. and Martinez C. B. (2007). Histopathology of gills, kidney and liver of a Neotropical fish caged in an urban stream. *Neotrop. Ichthyol.* 5: 327-336.
- Chinabut, S., Limsuwan, C., Tonguthai, K. and Punkachonboon, T. (2000). Toxic and sublethal effect of formalin of freshwater fishes. Available at <http://www.fao.org>. (Accessed on November 15<sup>th</sup>, 2019).
- Della Torre, F., Salibian, A. and Ferrari, L., (2000). Biomarkers assessment in juvenile *Cyprinus carpio* exposed to waterborne cadmium. *Environmental Pollution*, 109: 277–282.
- Drishya, M., Ambikadevi, A. and Aswin, B. (2016). Histopathological changes in the gills of fresh water fish, *Catlacatla* exposed to electroplating effluent. *International Journal of Fisheries and Aquatic Studies*, 4:13–16.
- Drishya, M., Ambikadevi, A. and Aswin, B. (2016). Histopathological changes in the gills of fresh water fish, *Catlacatla* exposed to electroplating effluent. *International Journal of Fisheries and Aquatic Studies*, 4:13–16.
- Ekpo, N. D., Etim, O. E., Opara K. N., Etuk, E. U. I., Atting, I. A. and Udoinyang, E. P. (2018). Insecticide Susceptibility Profile of Malaria Vector From Crude Oil Impacted Coastal Area of Eastern Obolo LGA, Akwa Ibom State, Nigeria. *World Journal of Applied Science and Technology*, 10 (1b): 191 - 201.
- Elzen G. W. and Elzen P. J. (1999). Lethal and sub-lethal effects of selected insecticides on *Geocoris pinctipes*. *Southwestern Entomologist*, 24: 199-206.
- Ewing, R. D. (1999). Dimishing Returns: Salmon Decline and pesticides. Funded by the Oregon Pesticide Education Network, Biotech Research and Consulting, Inc., Corvallis, OR. 55p. Available at <http://www.krsweb.com/stream/pesticide-fisheffects.htm.2011>. (Accessed on November 22<sup>nd</sup>, 2019)
- F.A.O (1987). Manual of Methods in Aquatic environment Research part 10 short-term static Bioassay (Ed. Reish, D.L and R.S Oshida). F.A.O Fisheries Technical paper 247pp.
- Fernandes, M. N. and Mazon, A. F. (2003). Environmental pollution and fish gill morphology. In: Val, A.L. and B.G. Kapoor (Eds.). *Fish adaptation*. Enfield, Science Publishers, pp: 203-231.
- Firat O., Cogun, H., Yuzeroglu, T., Gok, G., Rat, O. F., Kargin, F., Kotemen, Y. (2011). A comparative study

- on the effects of a pesticide (cypermethrin) and two metals (copper, lead) to serum biochemistry of Nile tilapia, *Oreochromis niloticus*, *Fish Physiol. Biochem.* 37: 657–666.
- Friedewald, W. T., Levy, R. I. and Fredrickson, D. S. (1972) Estimation of the Concentration of Low-Density Lipoprotein Cholesterol in Plasma, without use of the Preparative Ultracentrifuge. *Clinical Chemistry*, 18: 499-502.
- Ghelichpour, M., Taheri Mirghaed, A., Mirzargar, S. S., Joshaghani, H. and Ebrahimzadeh Mousavi, H., 2017. Plasma proteins, hepatic enzymes, thyroid hormones and liver histopathology of Cyprinus carpio (Linnaeus, 1758) exposed to an oxadiazin pesticide, indoxacarb. *Aquaculture Research*. 48 (11) 5666–5676.
- Giari, L., Manera, M., Simoni, E. and Dezfuli, B. (2007). Cellular alterations in different organs of European sea bass *Dicentrarchus labrax* (L.) exposed to cadmium. *Chemosphere* 67, 1171e1181.
- Granner, R. and Rodwell, P. (2006). Harper's Illustrated Biochemistry (Harper's Biochemistry). (McGraw-Hill Medical). Bhattacharya, H., Lun, L., 2005. Biochemical effects to toxicity of CCl<sub>4</sub> on rosy barbs (*Puntius conchoniensis*). *Our Nature* 3: 20–25.
- Hammed, A. M., Fashina-Bombatta, H. A., Wusu, A. D. and Ayeyan, I. O. (2010). Lipid Profile and Blood By-Products of Deformed and Healthy African Mud Catfish. *Proceedings of Fisheries Society of Nigeria (FISON) ASCON*, Badagry 25th-29th October 2010
- Harabawy, A.S.A. and Ibrahim, A.Th.A. (2014). Sub-lethal toxicity of carbofuran pesticide on the African catfish *Clarias gariepinus* (Burchell, 1822): Hematological, Biochemical and Cytogenetic response. *Ecotoxicology and Environmental Safety*, 103: 61-67
- Hoseini, S. M. and Yousefi, M. (2019). Beneficial effects of thyme (*Thymus vulgaris*) extract on oxytetracycline-induced stress response, immunosuppression, oxidative stress and enzymatic changes in rainbow trout (*Oncorhynchus mykiss*). *Aquaculture Nutrition*. 25: 298–309.
- Huculeci R., Dinu, D., Staicu, A. C., Munteanu, M. C., Costache, M. Dinischiotu, A. (2008). Malathion-induced alteration of the antioxidant defence system in kidney, gill, and intestine of *Carassius auratus gibelio*, *Environmental Toxicology*, 523–530, <https://doi.org/10.1002/tox.20454>.
- Ingham, L., Audoer, U. and Victor, T. (2012). The Chlorfenapyr. *Biology of Insecticides*, 20: 131-6.
- Islam, M. S., Haque, M. M., Uddin, M. N. and Hasanuzzaman, M. (2019). Histopathology in the fish *Channa punctatus*, *Heteropneustes fossilis* and *Anabas testudineus* exposed to diazinon. *International Journal of Fisheries and Aquatic Studies*, 7(6): 47-54
- Ivoke, N., Mgbenka, B. O. and Okeke, O. (2007). Effect of pH on the growth performance of *Heterobranchius bidorsalis* and *Clarias gariepinus* hybrid juveniles. *Animal Research International*, 4(1): 639-642.
- Joseph, B. and Raj, S. J. (2011). Effect of Curacron toxicity on aminotransferases (ALT and AST) in the serum of the fish *Cyprinus carpio*. *International Journal of Biological and Chemical Sciences*, 5: 207–211.
- Kakuta, I. and S. Murachi, (1997). Physiological response of carp, *Cyprinus carpio*, exposed to raw sewage containing fish processing wastewater. *Environmental toxicology and water quality*, 12: 1-9.
- Kamaraju R., Barik, T. K., Velamuri, P. S., Bhatt, R., Srivastava, H., Sreehari, U. and Dash, A. P. (2011). Chlorfenapyr: A new insecticide with novel mode of action can control pyrethroid resistant malaria vectors. *Malaria Journal*, 10 (1): 16.
- Karami-Mohajeri, S and Abdollahi, M. (2011). Toxic influence of organophosphate, carbamate and organochlorine pesticides on cellular metabolism of lipids, proteins and carbohydrates: a systematic review. *Journal of Human Exposure and Toxicology*, 30: 1119-1140.
- Katagi T. (2010). Bioconcentration, bioaccumulation and metabolism of pesticides in aquatic organisms. *Review of Environmental Contamination and Toxicology*, 204:1–132.
- Kavitha P. and Rao J. V. (2009). Sub-lethal effects of profenofos on tissue-specific anti-oxidative responses in a Euryhaline fish, *Oreochromis mossambicus*. *Ecotoxicology and Environmental Safety*, 72 (6): 1727-1733.
- Kim, J.-H. and Kang, J. C. (2016). The toxic effects on the stress and immune responses in juvenile rockfish, *Sebastes schlegelii* exposed to hexavalent chromium. *Environment Toxicology and Pharmacology*, 43: 128–133
- Kumar, A., Sharma, B. and Pandey, R. S. (2011). Cypermethrin induced alterations in nitrogen metabolism in freshwater fishes. *Chemosphere*, 83: 492-501.
- Kumar, A., Sharma, B. and Pandey, R. S. (2011). Cypermethrin induced alterations in nitrogen metabolism in freshwater fishes. *Chemosphere* 83: 492–501.
- Louis A. H. and Diana L. W. (2013). Pesticides and Aquatic animals: A guide to reducing impacts on aquatic systems. Virginia Cooperative Extension, VSO, 420: 013.
- Mahdi, B. (2012). Adverse Effect of Insecticides on various Aspects of fish's Biology and Physiology, Insecticides-Basic and other Applications, Dr. Sonia Solneski (Ed.); ISBN: 978-953-51-0007-2, Intech, Available from <http://www.intechopen.com/books/insecticides-basic-and-other-application/adverse-effect-of-insecticides-on-varous-aspects-of-fish-s-biology-and-physiology>. (Accessed on October 29<sup>th</sup>, 2019).
- Majumder, R. and Kaviraj, A. (2017). Cypermethrin induced stress and changes in growth of freshwater fish *Oreochromis niloticus*. *International Journal of Aquatic Research*, 9:117–128.
- Maksymiv, I. V., Husak, V. V., Mosiichuk, N. M., Matviishyn, T. M., Sluchyk, I. Y., Storey, J. M., Storey, K. B. and Lushchak, V. I. (2015). Hepatotoxicity of herbicide Sencor in goldfish may result from induction

- of mild oxidative stress. *Pesticide, Biochemistry and Physiology*, 122: 67–75.
- Malarvizhi, A., Kavitha, C., Saravanan, M. and Ramesh, M. (2012). Carbamazepine (CBZ) induced enzymatic stress in gill, liver and muscle of a common carp, *Cyprinus carpio*. *Journal of King Saud University*, 24:179–186.
- Malik A, Ojha P. and Singh K. (2008). Levels and distribution of persistent organic pesticide residue in water and sediments of Gomti River (India): a tributary of the Ganges River. *Environmental Monitoring and Assessment*. 148 (1-4):421–435
- Matagi S. V., Swai D. and Mugabe, R. (1998). A review of heavy metal removal mechanisms in wetlands. *African Journal of Tropical hydrobiology and Fisheries*, 8: 23-35.
- McGowan, M. W., Artiss, J. O., Strandbergh, D. R. and Zak, B. (1983). A Peroxidase-Coupled Method for the Colorimetric Determination of Serum Triglycerides. *Clinical Chemistry*, 29, 538-542.
- Mohamed F. A. S. (2009). Histopathological Studies on *Tilapia zillii* and *Solea vulgaris* from Lake Qarun, Egypt. *World Journal of Fish and Marine Sciences*, 1 (1): 29-39.
- Tudi, M., Daniel Ruan H., Wang, L., Lyu, J., Sadler, R., Connell, D., Chu C., and Phung, D. T. (2021). Agriculture Development, Pesticide Application and Its Impact on the Environment. *International Journal of Environmental Research and Public Health*, 18(3): 1112 - 1135.
- Murray, H. T. (2018). *Water Science*. Available at <http://www.usgs.gov/special-topic/water+science+school> (Accessed December 3<sup>rd</sup>, 2019).
- Murray R. K. (1991). *Harpers Biochemistry* 22nd edn, Prentice Hall International Inc., 678p
- N'Guessan R. and Rowland, M. (2007). Chlorfenapyr: A pyrethroid insecticide for the control of pyrethroid or DDT resistant *Anopheles gambiae* (Diptera: Culicidae) mosquitoes. *Acta Tropica*, 120 (1): 69-78.
- Okonkwo, F. O., Ejike, C. E. C., Anoka, A. N. and Onwurah, I. N. E. (2013). Toxicological Studies on the Short Term Exposure of *Clarias albopunctatus* (Lamonte and Nichole 1927) to Sublethal Concentrations of Roundup. *Pakistan Journal of Biological Sciences*, 16 (18): 939-944.0
- Olaniyi, K. (2020). Histopathology Studies of Selected Organs of *Hemichromis fasciatus* Inhabiting Igun Gold Mining and Opa Reservoirs, South Western Nigeria: A Comparative Study. *International Journal of Advanced Life Sciences and Technology*, 4 (1): 1–10.
- Rahman, A. N. A., ElHady, M., Hassanin, M. E., Mohamed, A. A. R. (2019). Alleviative effects of dietary Indian lotus leaves on heavy metals-induced hepato-renal toxicity, oxidative stress, and histopathological alterations in Nile tilapia, *Oreochromis niloticus* (L.). *Aquaculture*, 509: 198–208.
- Rand, G. M. (2004). Fate and effects of the insecticide-miticidechlorfenapyr in outdoor aquatic microcosms. *Ecotoxicology and Environmental Safety*, 58 (1): pp 50-60.
- Ross, B and Wilson, J. (2018). *Anatomy and Physiology in Health and illness*. 13<sup>th</sup> Edition, Elsevier, USA. 560pp.
- Sharma, R. K. and Agrawal, M. (2005). Biological effects of heavy metals: An overview. *Journal of Environmental Biology*. 26: 301-313.
- Sheppard, Graig D. and John, A. Joyce (1998). Increased susceptibility of Pyrethroid-Resistant Horn flies (Diptera: Muscidae) to Chlorfenapyr. *Journal of Economic Entomology*, 9 (2): 398-400.
- Somdare P. O., Nwani C. D., Nwadinigwe A. O., Nwani J. C., Odo G. E., Ugbor O. N., Ukonze J. A. and Ezeibe A. C. A. (2015). Fenthion induced toxicity and histopathological changes in gill tissue of freshwater African catfish, *Clarias gariepinus* (Burchell, 1822). *African Journal of Biotechnology* 14 (25): 2103-2113.
- Sprague J. B. (1972). The ABC's of pollutant bioassay a paper presented on environment monitory in Los Angeles, California, June 27-28 (ASTM)
- Sun, H., Xu, X.-L., Xu, L.-C., Song, L., Hong, X., Chen, J.-F., Cui, L.-B., Wang, X.-R., 2007. Antiandrogenic activity of pyrethroid pesticides and their metabolite in reporter gene assay. *Chemosphere* 66, 474–479.
- Tomlin C. D. S. (2000). *The Pesticide Manual, a World compendium*, 12<sup>th</sup> Edition. British Crop Protection Council, London.
- Webb, D., Gagnon, M. M. and Rose, T. (2005). Metabolic enzyme activities in black bream, *Acanthopagrus butcheri* from the swan canning estuary, Western Australia. *Comp. Biochem. Physiol. C. Toxicol Pharmacol*. 141 (4): 356–365.
- WHO (2017). Chlorfenapyr – World Health Organisation. Available at <http://www.who.int>chlorfenapyr-specs-eval-WHO-December-2017>. (Accessed on November 14<sup>th</sup>, 2019).
- Wilki, M. P. and Wood, E. (1991). Nitrogenous waste excretion acid base regulation and ion regulation in rainbow trout *Oncorhynchus mykiss* exposed to extremely alkaline water. *Physiological Zoology Journal* 64: 1069-1074.
- Xing, H., Li, S., Wang, Z., Gao, X., Xu, S., Wang, X. (2012). Histopathological changes and antioxidant response in brain and kidney of common carp exposed to atrazine and chlorpyrifos. *Chemosphere* 88: 377–383.
- Zhao Y and Mu W (2018). Sub-lethal effects of Chlorfenapyr on the life table parameters, nutritional, physiological and enzymatic properties of *Bradysia doriphaga* (Diptera: Sciaridae). *Pesticide Biochemistry and Physiology*, 148: 93-102