



### Surgically Induced Necrotising Scleritis after Pterygium Excision

*Sclérite nécrosante induite par la chirurgie après excision d'un Ptérygion*

J. F. A. Owoeye\*, O. O. Ayorinde

#### ABSTRACT

**BACKGROUND:** Surgically induced necrotising scleritis (SINS) presents as a focal area of intense scleral inflammation next to the site of previous scleral or limbal excision. There may be or no associated connective tissue disease. It may also follow Pterygium excision with use of antimetabolites.

**OBJECTIVE:** To report an uncommon complication following pterygium excision, one of the commonest surgeries performed by Ophthalmologists.

**CASE REPORT:** Our patient was a 62-year-old retired teacher who had a left eye nasal primary pterygium excised with Mitomycin C (MMC) dab topically. He presented 20 months later with signs and symptoms of SINS in the left eye. Systemic and laboratory examinations were normal. The scleral defect was covered with mucous membrane graft (MMG) obtained from the lower lip. The choice of MMG was due to non-availability of amniotic membrane graft (AMG) in our centre. The patient was also placed on pulsed injection of methylprednisolone 1000mg daily in slow intravenous (IV) infusion for three days, IV cyclophosphamide 500mg on the 4th day and then on a monthly basis for six months; the graft remained intact thereafter with no further signs of inflammation over a period of six months of follow up.

**CONCLUSION:** SINS should be recognised as a possible complication of pterygium excision. The use of MMG as an alternative for sclera patch graft in the absence of AMG is suggested. *WAJM 2012; 31(2): 142–144.*

**Keywords:** Pterygium, Necrotising scleritis, Mucous membrane, Immunosuppressive, Antimetabolite.

#### RÉSUMÉ

**CONTEXTE:** La sclérite induite par la chirurgie (SINC) se présente comme une zone focale d'intense inflammation de la sclère près du site d'une excision antérieure de la sclère ou de la limbe. Elle survient avec ou sans connectivite associée. Elle peut aussi faire suite à l'excision d'un ptérygion avec ou sans usage d'anti métabolites.

**OBJECTIF:** Rapporter un cas inhabituel de complication suite à l'excision d'un ptérygion qui fait partie des interventions les plus fréquemment réalisées par les ophtalmologues.

**CAS CLINIQUE:** Notre patient est un homme de 63 ans, enseignant à la retraite qui présentait un ptérygion primitif naso oculaire gauche excisé avec application de Mithomycin C topique. Il s'est présenté 20 mois plus tard avec des symptômes et signes de SINC de l'oeil gauche. L'examen Clinique et les explorations de laboratoires étaient normaux. Le défaut de la sclère a été comblé par un lambeau muqueux prélevé à la lèvre inférieure. Le choix de ce lambeau était dû à la non disponibilité de lambeau de membrane amniotique dans notre centre. Le patient a aussi été mis sous injection pulsée de méthylprednisolone 1000 mg/jour en perfusion IV veineuse lente pendant 3 jours et 500 mg de cyclophosphamide au 4<sup>e</sup> jour puis tous les mois pendant 6 mois. Le lambeau avait bien tenu par la suite sans autre signe d'inflammation après 6 mois de suivi.

**CONCLUSION:** La SINC devrait être reconnue comme complication potentielle de l'excision d'un ptérygion. L'utilisation d'un patch de lambeau muqueux comme alternative au lambeau de membrane amniotique est conseillée. *WAJM 2012; 31(2): 142–144.*

**Mots clés:** Ptérygiom, Sclérite nécrosante, Membrane muqueuse, Immunosuppression, Antimétabolite.

**INTRODUCTION**

Over the years, there have been many surgical techniques for pterygium including bare sclera resection, or simple conjunctival closure.<sup>1-3</sup> Pterygium excision is one of the commonest surgeries performed by Ophthalmologists.<sup>4</sup> Pterygium recurrence following excision without the use of conjunctival auto graft or Mitomycin C (MMC) has been found to be 6 and 25 times higher respectively, thereby discouraging the use of a bare sclera as the main surgical technique for primary pterygium.<sup>2</sup> Many adjunct therapies, such as MMC,<sup>3</sup>  $\beta$ -irradiation<sup>5</sup> and amniotic membrane<sup>6,7</sup> have been used to reduce the rate of recurrence. Use of these adjunct therapies has also been associated with their own complications.<sup>8</sup>

Surgically induced necrotising scleritis (SINS) presents as a focal area of intense scleral inflammation next to the site of previous scleral or limbal excision.<sup>9,10</sup> There may be or no associated connective tissue disease. Other causes of scleral necrosis should be excluded when making a diagnosis of SINS. Treatment could be with membrane graft or immunosuppression.

We report a case of SINS following primary pterygium excision in the left eye with the use of MMC. The patient had no serological evidence of connective tissue disease. The patient was successfully treated with MMG and immunosuppression. To the best of our knowledge, this would be the first of such a report from our centre.

**CASE REPORT**

Our patient was a 62-year old retired teacher, on topical antiglaucoma medication, who had primary pterygium excision on the left eye with MMC dab in 2006. A bare sclera technique was used for the pterygium excision with minimal cauterisation with a wet field cautery. Post operatively, the patient was placed on oral non-steroidal anti-inflammatory drugs and topical steroidal medications. The patient defaulted from regular clinic follow up visits. He re-presented 20 months later with a complaint of severe pain on the left eye. The visual acuity in the right eye washand motion (HM) and in the left eye was 6/18 but improved to

6/12 with pinhole; there was advanced disc cupping bilaterally.

The scleralbed of the left eye at the site of the excised pterygium showed significant thinning and uveal show (Fig. 1). The sclera next to the excision site was inflamed. There was no evidence of active corneal melting or posterior scleritis on ocular ultrasonography. Systemic and laboratory examinations including full blood count (FBC) with erythrocyte sedimentation rate (ESR), electrolyte and urea (E&U), fasting blood sugar (FBS), anti-nuclear antibody test, Hepatitis B surface antigen and liver function test (LFT) were normal. Rheumatoid factor was also negative. We did not consult a Rheumatologist because we do not one in our institution.

A diagnosis of a left surgically induced necrotising scleritis (SINS) was made. The left eye (LE) scleral defect was covered with mucous membrane graft

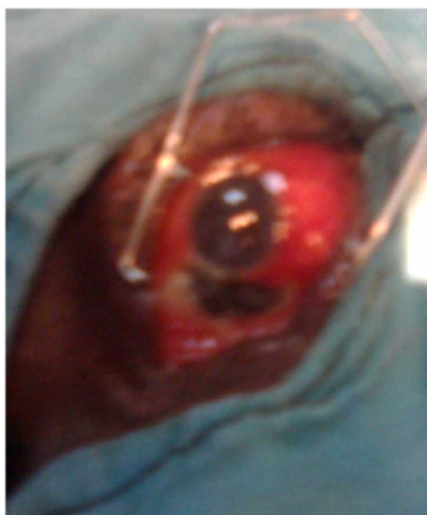(MMG) obtained from the lower lip. The patient was subsequently placed on pulsed injection of methylprednisolone 1000mg daily in slow IV infusion for three days. On the 4<sup>th</sup> day, he had IV cyclophosphamide 500mg and afterward on a monthly basis for six months. The scleral inflammation subsided at one month of commencement of the immunotherapy. The MMG remained attached with a slight elevation above the adjacent conjunctiva. No signs or symptoms of corneal dellen were, however, noticed; recurrence of inflammation was also not noticed over a period of six months follow up (Fig. 2). The visual acuity on the left eye at the last clinic visit was 6/18 but improved to 6/9 with pinhole.

**DISCUSSION**

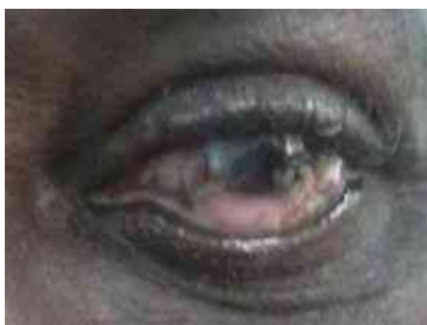
Surgically induced necrotizing scleritis (SINS), though rare, appears as an intense scleral inflammation at or next to the site of the previous surgery.<sup>9,10,15</sup> It has been found to occur after cataract, squint, glaucoma and retinal detachment surgery<sup>9,10</sup> and has a variable latent period of one day to 40 years between surgery and presentation of symptoms.<sup>10</sup> Clinical and or serological markers have been found in some cases.<sup>9,10</sup> Inhibition of wound healing with the use of  $\beta$ -irradiation and MMC<sup>8</sup> and inducement of ischaemic scleral necrosis following excessive cauterisation<sup>12</sup> in bare scleral technique have been implicated in scleralnecrosis post pterygium surgery.

The development of SINS has been associated with autoimmunity or hypersensitivity with immune complexes found in adjacent episcleral vessel walls.<sup>11</sup> The use of systemic immunosuppressives among others has been successful in the treatment of SINS.<sup>9,10,13,14</sup> Surgical management includes scleral patch grafts with amniotic membrane.<sup>15</sup>

Our patient presented with SINS following pterygium excision on the left eye with the use of topical MMC. The inflammation was noted adjacent to the surgical site. There was no clinical or serological evidence of connective tissue disease; the liver function test was normal. The patient showed a good response to scleral patch with MMG and



**Fig. 1: Thin Scleral Bed with Uveal show (LE)**



**Fig. 2: LE with MMG**

immunosuppressive therapy. The anticipation for a trabeculectomy on the left eye in the future prevented harvesting a conjunctival graft to cover the scleral defect. Availability and use of an amniotic membrane graft (AMG) in our environment is also not yet widespread. SINS should be considered as a differential diagnosis in cases of scleritis or scleral necrosis following pterygium excision with or without the use of an antimetabolite. The patient may not show clinical or laboratory evidence of connective tissue disorder. Early diagnosis is important. Immunosuppressant therapy and scleral patch with MMG is successful in the management.

#### REFERENCES

- Hirst LW. The treatment of pterygium. *Surv Ophthalmol* 2003; **48**: 145 – 80.
- Sanchez-Thorin JC, Rocha G, Yelin JB. Meta-analysis on the recurrence rates after bare sclera resection with and without mitomycin C use and conjunctival autograft placement in surgery for primary pterygium. *Br J Ophthalmol* 1998; **82**: 661–5.
- Manning CA, Kloess PM, Diaz MD, Yee RW. Intraoperative mitomycin in primary pterygium excision: a prospective randomised trial. *Ophthalmology* 1997; **104**: 844–8.
- Owoeye JFA, Ademola-Popoola DS, Adepoju FG, Adido J, Uyanne IA, Ogundimu KO *et al.* Ophthalmic Surgical Practice in Ilorin, Nigeria in the 1990s. *The Trop J Health Sci* 2006; **13**: 31–34.
- Simsk T, Gunalp I, Atilla H. Comparative efficacy of beta-irradiation and mitomycin-C in primary and recurrent pterygium. *Eur J Ophthalmol* 2001; **11**: 126–32.
- Luanratanakorn P, Ratanapakorn T, Suwan-Apichon O, Chuck RS. Randomised controlled study of conjunctival autograft versus amniotic membrane graft in pterygium excision. *Br J Ophthalmol* 2006; **90**: 1476–80.
- Solomon A, Pires RT, Tseng SC. Amniotic membrane transplantation after extensive removal of primary and recurrent pterygia. *Ophthalmology* 2001; **108**: 449–60.
- Rubinfeld RS, Pfister RR, Stein RM, Foster CS, Martin NF, Stoleru S, *et al.* Serious complications of topical mitomycin-C after pterygium surgery. *Ophthalmology* 1992; **99**: 1647–54.
- Galanopoulos A, Snibson G, O'Day J. Necrotising anterior scleritis after pterygium surgery. *Aust NZJ Ophthalmol* 1994; **22**: 167–73.
- O' Donoghue E, Lightman S, Tuft S, Watson P. Surgically induced necrotising sclerokeratitis (SINS) – precipitating factors and response to treatment. *Br J ophthalmol* 1992; **76**: 17–21.
- Fong LP, Sainz de la Maza M, Rice BA, Kupferman AE, Foster CS. Immunopathology of scleritis. *Ophthalmology* 1991; **98**: 472–9.
- Alsagoff Z, Tan DT, Chee SP. Necrotising scleritis after bare sclera excision of pterygium. *Br J Ophthalmol* 2000; **84**: 1050–2.
- Vagefi MR, Hollander DA, Seitzman GD, Matgolis TP. Bilateral surgically induced necrotising scleritis with secondary superinfection. *Br J Ophthalmol* 2005; **89**: 124–5.
- Young AL, Wong SM, Leung AT, Leung GY, Cheng LL, Lam DS. Successful treatment of surgically induced necrotising scleritis with tacrolimus. *Clin Exp Ophthalmol* 2005; **33**: 98–9.
- Sridhar MS, Bansal AK, Rao GN. Surgically induced necrotising scleritis after pterygium excision and conjunctival autograft. *Cornea* 2002; **21**: 305–7.