



Methotrexate-Induced Erythema Multiforme: A Case Report and Review of the Literature

Induite par le méthotrexate érythème polymorphe: Un rapport de cas et revue de la littérature

F. O. Omoregie*, M. Ukpebor, B. D. O. Saheeb

ABSTRACT

BACKGROUND: Mucosal affectation may be a direct cytotoxic or cytostatic effect of methotrexate.

OBJECTIVE: To highlight the diagnostic procedure and treatment intervention erythema multiforme complicating methotrexate-induced allergic stomatitis.

CASE REPORT: The patient was a 60-year-old man suffering from stomatitis that rapidly developed into erythema multiforme. The patient had been prescribed methotrexate to treat rheumatoid arthritis. The patient presented with painful ulceration of the vermillion border of the upper and lower lips covered with necrotic tissues. We made a tentative diagnosis of methotrexate induced allergic stomatitis. On the patient's second visit to the clinic, the lesion had developed into crusted and haemorrhagic ulceration with erythematous patches on the lips. The patient was now complaining of weakness, fever and occasional seizure attack. Examination of the upper and lower extremities revealed bilateral bullous eruptions. The definitive diagnosis was that of erythema multiforme complicating methotrexate induced allergic stomatitis. Withdrawal of the methotrexate yielded positive result with complete resolution of the lesions after 12 days of drug withdrawal.

CONCLUSION: Early diagnosis of adverse drug reactions is essential for effective treatment, to avoid untoward systemic complications. *WAJM 2011; 30(5): 377–379.*

Keywords: Methotrexate, Allergic Stomatitis, Erythema multiforme, complications.

RÉSUMÉ

CONTEXTE: l'affectation des muqueuses peut être un effet cytotoxique direct ou cytostatique de méthotrexate.

OBJECTIF: Pour mettre en évidence la procédure de diagnostic et d'érythème polymorphe de traitement d'intervention compliquée induite par le méthotrexate stomatite allergique.

RAPPORT DE CAS: Le patient était un homme de 60 ans souffrant de la stomatite qui a rapidement développé en un érythème polymorphe. Le patient avait été prescrit méthotrexate pour traiter l'arthrite rhumatoïde. Le patient s'est présenté avec une ulcération douloureuse de la frontière vermillon des lèvres supérieures et inférieures couvertes de tissus nécrosés. Nous avons fait un diagnostic provisoire de méthotrexate induit stomatite allergique. Sur la deuxième visite du patient à la clinique, la lésion s'est développée en une ulcération croûteuse et hémorragique avec des plaques érythémateuses sur les lèvres. Le patient a été maintenant se plaindre de la faiblesse, la fièvre et la saisie attaque occasionnelle. L'examen des extrémités supérieures et inférieures ont révélé bilatéraux éruptions bulleuses. Le diagnostic définitif était celui de l'érythème polymorphe compliqué méthotrexate induit stomatite allergique. Retrait de la méthotrexate a abouti à des résultats positifs avec une résolution complète des lésions après 12 jours de retrait du médicament.

CONCLUSION: Le diagnostic précoce des réactions indésirables aux médicaments est essentiel pour un traitement efficace, afin d'éviter des complications systémiques indésirables. *WAJM 2011; 30(5): 377–379.*

Mots-clés: méthotrexate, stomatite allergique, érythème polymorphe, de complications.

INTRODUCTION

Allergic stomatitis is a known side effect of methotrexate administered either orally or parenterally.¹ The mucosal alteration in this lesion may result from direct cytotoxic or cytostatic effect of the drug on the dividing epithelial cells, myelosuppression or alteration of microbial flora. The condition presents clinically as painful, erythematous, erosive or ulcerative lesion, with the nonkeratinized mucosa often affected. Pseudomembranous necrotic surface, with widespread sloughing and ulceration may arise within days of commencement of cytotoxic drug therapy. Treatment of the lesion is by identification and withdrawal of the offending drug. Systemic corticosteroid therapy in cases with mucosal reactive lesion gives excellent prognosis.²

The name 'erythema multiforme' originated from Von Hebra.³ The development of erythema multiforme (EM) is a rare adverse reaction to methotrexate.² EM presents as acute mucocutaneous inflammatory and hypersensitivity reaction characterised by a skin eruption; with symmetric erythematous, oedematous or bullous lesions of the skin or mucous membranes.⁴ Although, the lesion has "multiple forms",^{5,6} it is divided into two overlapping subgroups – the minor and major types. EM minor represents a localized eruption of the skin with mild or no mucosal involvement, corresponding to the initial description of Von Hebra.³ EM major or Stevens-Johnson syndrome (SJS) is more severe; classically involving two or more mucous membranes, with more variable skin involvement. This latter form is a potentially life-threatening disorder.⁷

Although the pathogenesis of the disease is unknown, there are many implicated precipitating factors, particularly herpes simplex infection.^{1,8} EM may occur due to drug therapy such as sulphonamides, barbiturates, antibiotics, phenolphthalein-containing laxatives,^{5,6,9} anticonvulsants, non-steroidal anti-inflammatory drugs, chlormezanone and allopurinol.¹⁰ However, patients with EM rarely give a positive drug history. Another possible trigger for the development of EM is

radiation therapy.¹¹ EM can be an immune mediated reaction possibly related to circulating immune complexes.¹² Nevertheless, many cases of EM appear to arise spontaneously.

We report a case of erythema multiforme complicating an initially diagnosed methotrexate induced allergic stomatitis, in a 60-year-old patient that was receiving treatment for rheumatoid arthritis, to highlight the diagnostic procedure and treatment intervention of this rare case.

CASE REPORT

A 60-year-old male patient presented at the Oral and Maxillofacial Surgery and Pathology Clinic of the University of Benin Teaching Hospital, Benin City, Nigeria with a painful ulceration of the vermilion border of the upper and lower lips and oral mucosa [Figure 1]. The lesion had a surface covered by pseudomembranous necrotic tissue. A detailed history revealed that the patient was suffering from rheumatoid arthritis and placed on a daily dose of 5mg of methotrexate for over two weeks by an orthopedic surgeon.

An initial diagnosis of methotrexate-induced allergic stomatitis was made and the patient placed on warm saline mouth rinse eight times daily for two weeks, soft diet and 12.5mg promethazine eight hourly for a week. In addition, amoxycillin 500mg and methronidazole 400mg were administered 8 hourly daily for five days. We informed the orthopaedic surgeon that the patient was probably reacting adversely to methotrexate and advised a change of medication. We also took oral swab for microscopy, culture and sensitivity.

On the patient's second visit to the clinic, the lesion had developed into crusted and hemorrhagic ulceration with erythematous patches on the lips. The patient was now complaining of weakness, fever and occasional seizure attacks. Examination of the upper and lower extremities revealed bilateral bullous eruptions [Figure 2]. The definitive diagnosis was that of erythema multiforme complicating methotrexate induced allergic stomatitis. The oral swab culture revealed that there was a secondary infection by *Staphylococcus*

aureus sensitive to the drug ciprofloxacin. We placed the patient on ciprofloxacin 500mg 12 hourly for five days. In addition to this treatment, an advice to the orthopaedic surgeon to withdraw the drug yielded positive result with complete resolution of the skin and oral mucosal lesions after 12 days of drug withdrawal [Figure 3].

DISCUSSION

The hallmark of EM is a target lesion with variable mucous membrane involvement; mucosal involvement is usually limited to the oral mucosal.¹³ Similarly, this report showed an initial oral mucosal involvement, followed by cutaneous lesions affecting both the upper and lower extremities. The lesion presented as methotrexate induced

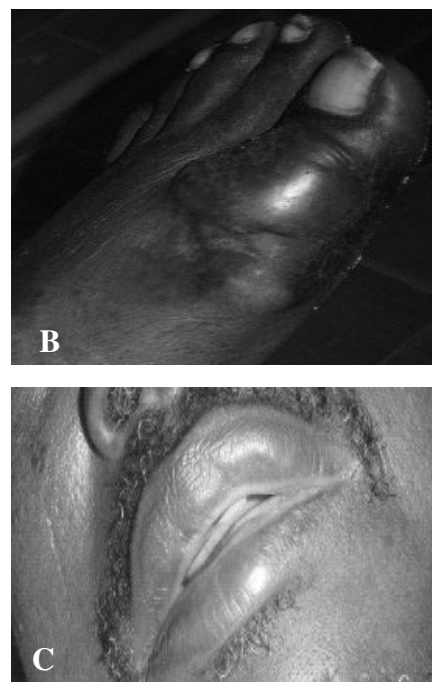


Fig. 1: Ulceration of the vermilion border of upper and lower lips, and other oral mucosa sites

allergic stomatitis and rapidly developed into EM within a few days. Although, literature reports vary from 0% to 18% association of EM with medications.^{9,10} This is the first reported case of EM arising as a complication of methotrexate therapy in our centre. Erythema multiforme is a known adverse reaction to methotrexate.¹⁴ The adverse cutaneous drug eruptions may vary from benign maculopapular rash to Lyell syndrome, which depends mainly on the host response to the drug. Although the precise pathogenesis is still unknown, EM appears to be the consequence of a cytotoxic immunological reaction against the keratinocytes expressing non-self antigens.¹⁵

Our report showed that the lesion occurred in a 60-year-old male patient, in contrast to previous reports that clearly identified the lesion frequently in younger individuals.^{2,5,6,10} Although EM frequently occurs in males, the incidence of drug-related EM is similar in males and females.⁷ Soteris *et al*¹⁶ reported a similar case of methotrexate induced EM with lip swelling and generalised rash following oral administration of methotrexate. The rashes resolved after withdrawal of methotrexate therapy and several days of administering diphenhydramine. However, the clinical presentation of this case was severe compared to those reported by Soteris *et al*.¹⁶ Similarly, there was complete resolution of the skin and mucosal lesions within 2 weeks of initial presentation, following antihistamine therapy and withdrawal of the causative drug. We support a change to alternative medication following withdrawal of methotrexate, especially for treatment of neoplastic lesions, as recommended by Taylor *et al*.¹⁴

The oral microbiological diagnosis of the infective organism suggests that there was secondary infection, whereas the known primary infective organisms

in EM are herpes simplex virus and mycoplasma pneumoniae.^{2,13,17}

In conclusion, this report highlights the diagnostic procedures and treatment intervention to control methotrexate-induced erythema multiforme, a rare adverse drug reaction. Early diagnosis of adverse drug reactions is essential for effective treatment, to avoid untoward systemic complications.

ACKNOWLEDGEMENT

We wish to acknowledge the American Association for Dental Research and International Association for Dental Research, for granting us the opportunity to carry out a poster presentation of this case at the April 2nd to 5th 2008 Conference in Dallas, Texas, U.S.A.

REFERENCES

1. Drug information online. Methotrexate side effects. Available at <http://www.drugs.com/sfx/methotrexate-side-effects.html>. (Accessed 17 Jan. 2008).
2. Sciubba JS, Regezi JA, Rogers III RS. Inflammatory Diseases. PDQ oral disease, diagnosis and treatment. B C Decker Inc. 2002; 288–289.
3. Von Hebra F. On diseases of the skin including the exanthemata translated by CH Fagge. London: New Sydenham Society. 1866; 285–289.
4. Carder RK. Hypersensitivity reactions in neonates and infants. *Dermatol Ther*. 2005; **18**: 160–175.
5. Huff J C, Weston WL, Tonnesen MG: Erythema multiforme: a critical review of characteristics, diagnostic criteria, and causes. *J Am Acad Dermatol* 1983; **8**: 763–775.
6. Cawson R A, Odell E W, Porter S. Disease of the oral mucosa: non-infective stomatitis. Cawson's Essentials of Oral Pathology and Oral Medicine. Elsevier press, 7th ed. 2002; 205–206.
7. Isik S R, Karakaya G, Erkin G, Kalyoncu A F. Multidrug-induced erythema multiforme. *J Invest Allergol Clin Immunol*. 2007; **12**: 196–198.

8. Huff J C: Erythema multiforme and latent herpes simplex infection. *Semin Dermatol* 1992; **11**: 207–210.
9. Carrozo M, Togliatto m, Galdolfo S. Erythema multiforme: a heterogenous pathologic phenotype. *Minerva stomatol* 1999; **48**: 217–226.
10. Assier H, Bastuji-Garin S, Revuz J, Roujeau JC: Erythema multiforme with mucous membrane involvement and Stevens-Johnson syndrome are clinically different disorders with distinct causes. *Arch Dermatol* 1995 May; **131**: 539–543.
11. Chulabhorn P, MD; Lawrence AS, MD. Erythema multiforme. Available at http://www.emedicine.com/dermatology/publication_of_erythema_multiforme_1.mht. (Accessed 7 Jan 2008).
12. Kokuba H, Aurelian L, Burnett J. Herpes simplex virus associated erythema multiforme (HAEM) is mechanistically distinct from drug-induced erythema multiforme: interferon- is expressed in HAEM lesions and tumor necrosis factor- in drug-induced erythema multiforme lesions. *J Invest Dermatol*. 1999; **113**: 808–815.
13. Alissa RS, Kelvin MD, John L, Barret Z. Cutaneous reactions to drugs in children. *Pediatrics* 2007; **120**: 1082–1096.
14. Taylor SW, Barnhill DR, Barke TW, Linville WK, Yevich I. Methotrexate-induced erythema multiforme. *Gynecol Oncol*. 1989; **33**: 376–378.
15. Inachi S, Mizutani H, Shimizu M. Epidermal apoptotic cell death in erythema multiforme and Steven-Johnson syndrome: contribution of perforin positive cell infiltration. *Arch Dermatol*. 1997; **133**: 845–849.
16. Soteris DF, El-Dahr JM. Reinstitution of methotrexate despite history of erythema multiforme and angioedema. *Jr of Allergy and Clinical Immunology*. 2004; **113**: 312.
17. Schallock PC, Dinulos JGH, Pace N, Schwarzemberger K, Wegner JK. Erythema multiforme due to Mycoplasma pneumoniae infection in two children. *Pediatr Dermatol*. 2006; **23**: 546–555.