



### Acute Retrocaecal Appendicitis: A Case Report

*Appendicite aigue rétrocoécale : a propos d'un cas*

T. T. Marchie\*, O. Ehimwenma

#### ABSTRACT

**BACKGROUND:** Acute abdomen is a clinical diagnosis and not a definitive one. The use of ultrasound in management and diagnosis of acute abdomen is rarely invoked in our environment. The importance of definite diagnosis in surgical and medical management cannot be overemphasized

**OBJECTIVE:** To report a case of ultrasound diagnosis of retro-caecal appendicitis.

**METHODS:** A nine-year-old male child presented with vomiting, vague abdominal pain, diarrhoea, and fever, which led to the following differential diagnoses; acute food poison gastro-enteritis, typhoid enteritis, malaria and acute appendicitis. He was investigated along these lines. He had abdominal ultrasonography and CT scan.

**RESULTS:** The ultrasound showed evidence of acute appendicitis. The findings on CT and surgery confirmed the diagnosis. Post-operatively, he made uneventful recovery.

**CONCLUSION:** The use of ultrasound in acute abdomen is rarely invoked in our environment which may lead to unquantifiable consequences both in management and complications. *WAJM* 2011; 30(2): 136–139.

**Keywords:** Ultrasonography, acute, abdomen, Appendicitis, appendix, paediatrics, computed axial tomography.

#### RÉSUMÉ

**CONTEXTE:** Le diagnostic d'un abdomen aigu est souvent clinique. L'échographie est rarement utilisée dans le diagnostic et la prise en charge de l'abdomen aigu dans notre environnement. Il importe d'obtenir un diagnostic définitif avant la prise en charge médicale ou chirurgicale de tout abdomen aigu.

**OBJECTIF:** Rapporter un cas d'appendicite aigue rétrocoécale diagnostiquée à l'échographie.

**METHODE:** Un enfant de 9ans était admis pour vomissements, douleurs abdominales vagues, diarrhée et fièvre faisant évoquer une toxi-infection alimentaire, gastroenterite, une fièvre typhoïde, une appendicite aigue, un paludisme. Il a bénéficié d'explorations paracliniques comportant une échographie et un scanner abdominal.

**RESULTATS:** L'échographie mettait en évidence des signes d'appendicite aigue qui sont confirmés par le scanner abdominal et l'exploration chirurgicale. Les suites opératoires étaient simples

**CONCLUSION:** L'échographie est rarement utilisée dans le diagnostic de douleurs abdominales aiguës dans notre environnement. Elle est d'un apport considérable dans le traitement et la prise en charge des complications. *WAJM* 2011; 30(2): 136–139.

**Mots Cles:** Ultrasonographie, Abdomen aigu, Appendicite, Pédiatrie, Tomodensitométrie.

## INTRODUCTION

This case report is to show the value of ultrasound in diagnosis and management of acute abdomen in our African setting, which is barely in use. The common causes of acute abdomen in paediatric age group in our environment are intestinal intussusceptions, volvulus and acute/ruptured appendicitis.<sup>1</sup> Ruptured bowel following typhoid enteritis is not very common following the advent and improvement in use of antibiotics.<sup>2</sup> This case report shows the use of ultrasonography (US) to determine the cause of the acute abdomen.<sup>3</sup> The appendix is a close ended, fingerlike pouch attached to the large intestine and located in the right lower aspect of the abdomen. It is attached to the caecum from which it develops embryologically and is located commonly in the right iliac fossa, corresponding to the McBurney's point which is at the junction of lower and middle third of a line joining the anterior superior iliac spine and the umbilicus on the surface of the anterior abdominal wall. Appendix is relatively long in children and the length varies between 2–23cm and with most being 7–12cm long. The tip of the appendix is variable in location but is most commonly retrocaecal, while the base is fairly constant in location, about 2cm distal to the ileocaecal valve.<sup>4</sup>

Appendicitis is an inflammation of the appendix, is a medical emergency and prompt and accurate diagnosis is necessary to reduce morbidity, especially in the pediatric age group.<sup>5</sup> Young children have fewer of the classic symptoms of nausea, vomiting and right iliac region pain and constipation than young adults and the risk of perforation is also higher in the pediatric population, especially those younger than 4 years. It is thus easy to miss the diagnosis and cause delay in management with potential consequences of perforation.<sup>6</sup> Radiodiagnostic imaging with ultrasound (US) and Computed Axial Tomography (CT) is very helpful and could make conclusive diagnosis.

The following is a case report of a 9 year old child with vague gastrointestinal complaints and non focal abdominal pain which was a physical diagnostic dilemma, resolved by ultrasonography. Confirma-

tion of the diagnosis was further substantiated with abdominal CT scan and later surgical findings.

## Case Report

The patient was a 9-year-old male presented at the Children's Emergency Unit of the University of Benin Teaching Hospital, Benin City, Nigeria with complaints of frequent stooling, vomiting and abdominal pain of a day's duration and fever that started an hour prior to presentation. Abdominal pain was periumbilical, and there was a strong history of consumption of yoghurt prior to onset of symptoms.

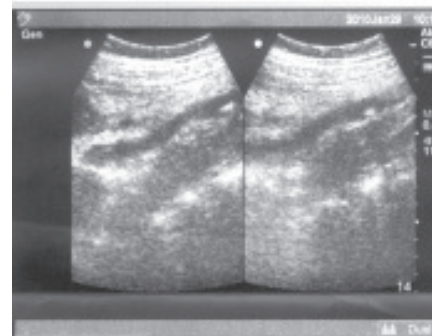
The patient was acutely ill looking, febrile (temperature 38.6°C), arterial pulse rate 110/minute; respiratory rate 32 cycles/minute, and had vague abdominal tenderness. He was mildly dehydrated. Other systems were essentially normal.

The following diagnostic differentials were contemplated acute food poison gastroenteritis, typhoid enteritis, malaria and possible acute appendicitis. There was significant delay in management of the patient in a bid to arrive at a diagnosis. The patient was referred to the Radiology Department for an abdominal ultrasound scan.

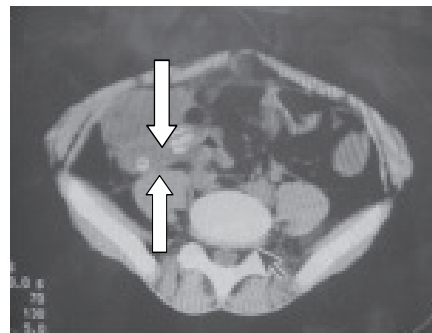
Abdominal ultrasound scan showed a dilated retrocaecal appendix with a diameter of 13.2mm and presence of an appendicolith casting distal acoustic shadow. There were multiple moderately dilated small bowel loops. There was no peri-appendicular collection or abscess. All other abdominal organs were essentially normal. Figure 1 shows the sonograms of the patient with the inflamed appendix labeled. The sonographic diagnosis of acute appendicitis was confirmed with CT-scan which showed dilated small bowel, oedematous appendix and appendicoliths at the base of the appendix. Figure 2.

The patient had an emergency appendectomy a few hours after the radiological diagnosis was made. Findings on surgery were that of an inflamed retrocaecal appendix measuring 120mm by 20mm containing 2 appendicoliths (fecolith) and bound by dense adhesions to the posterior wall of the caecum. Figure 3 shows the post operative specimen.

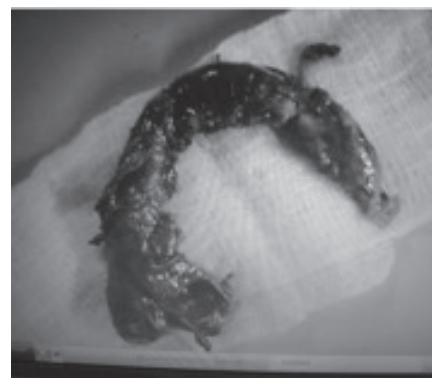Postoperatively, patient had fever for three days and was treated for malaria as a precautionary measure in malaria endemic region. Peritoneal aspirate sent for microscopy, culture and sensitivity (M/C/S) yielded no growth on culture. Patient was discharged seven days post operatively.



**Fig 1: Sonogram of hypo-echoic tubular edematous non compressible retrocaecal appendix (line arrow) with surrounding echogenic fat pad (two edge arrows) and appendicoliths (thick arrow) at the base of the appendix.**



**Fig. 2: CT-scan picture confirming retrocaecal appendicitis with 2 appendicoliths at base of the appendix. See thick arrow. The large arrow shows vertebra disc (the arrow is from CT-scan cursor which was mistakenly left in the picture).**



**Fig. 3: Post-operative specimen of inflamed appendix about to rupture.**

## DISCUSSION

Appendicitis in the pediatric age group is usually seen in infants older than five years as in our case but can occur at any age with atypical clinical findings seen in 30–50% of children especially the younger ones, and this often leads to delayed diagnosis.<sup>1</sup>

Younger children with this condition are unable to verbalize their symptoms or localize pain and thus pose a diagnostic dilemma. In addition they often present with non specific signs and symptoms. Thus delayed or incorrect diagnoses and complications such as appendiceal perforation can occur.<sup>6,7</sup> Appendicitis is a source of medical legal risk and the physician's diagnostic accuracy can be influenced by a clear understanding of the strengths and limitations of all tests.<sup>5</sup>

Accurate and precise diagnosis is obviously very important in the pediatric age group in whom imaging plays a key role in modern evaluation of suspected appendicitis.<sup>6–9</sup> Ultrasonography has many advantages as it is relatively inexpensive and available. A particular advantage in the pediatric age group is the lack of ionizing radiation. However a major drawback of ultrasonography is that it is operator dependent and the diagnosis may be missed in unskilled hands. The patient presented in this case had been scanned by residents outside working hours and was reported as normal.

The diagnosis of appendicitis is clinical. However a high negative laparotomy rate makes preoperative imaging diagnosis imperative as in the case presented. In a population based retrospective cohort study, Flum *et al*<sup>5</sup> studied 261,134 patients who underwent non-incidental appendectomies. They found that there are significant clinical and financial costs incurred by patients undergoing negative appendectomy (NA) during the treatment of presumed appendicitis. In the case presented, ultrasound scanning provided evidence based diagnosis of an inflamed appendix thus guiding the surgeon in performing surgery timely which undoubtedly reduced significant complication of morbidity and possibly mortality. The use of CTscan in this patient was to

douse the controversies that associate ultrasonography dependency on operator skill.

Ultrasound localization of the inflamed appendix in the retrocecal area in the case presented was also of significant value to the surgeon especially in decision of the method of appendectomy. A prospective study in 368 children with acute appendicitis by Ceres *et al*<sup>9</sup> found 92 with retrocecal appendicitis as was the case in our patient, suggesting retrocaecal appendix as infrequent occurrence. A correct diagnosis was made in 92.6 % of patients and in 94.5 % of those with retrocecal appendicitis.

US findings in acute appendicitis may include a blind ending tubular structure at the point of tenderness, which is non compressible with a diameter of 7cm or greater without peristalsis.<sup>10,11</sup> The other findings may include an appendicolith casting acoustic shadow, high echogenicity non-compressible surrounding fat pad, hypoechogenicity of surrounding fluid, abscess and oedema of the caecal pole. A high correlation has been found between the presence of a calcified appendicolith and appendicitis.<sup>10, 11</sup>

The technique of ultrasound evaluation of acute appendicitis using graded compression was first described by Puylaert<sup>12</sup> in which sixty consecutive patients with clinical signs of acute appendicitis were sonographically examined. The inflamed appendix was visualized by US in 25 (89%) of 28 patients with confirmed appendicitis and perforation was predictable in six of seven patients. The appendix was not visualized in 32 patients without appendicitis. The author found graded compression US the examination of choice if there is doubt whether an appendectomy should be performed.<sup>12</sup> Ang *et al*<sup>13</sup> in a retrospective review of 317 children who attended the emergency department of a children's hospital for acute abdominal pain found a positive predictive value of US for appendicitis of 0.92 and negative predictive value of 0.88.

The biggest drawback with US in the diagnosis of appendicitis is that negative findings at US do not exclude appendicitis unless a normal appendix is

visualized with a high degree of confidence.<sup>7</sup> Ultrasonography and Computed Axial Tomography (CT) are the frontline imaging modalities in such cases. It has been advocated that an effective imaging protocol should involve both US and CT. Inconclusive findings at US or failure to show the appendix should cause prompt use of enhanced CT.<sup>7</sup>

From a retrospective study by Wan *et al*<sup>15</sup>, using a Markov decision analytic model of pediatric appendicitis, the most cost effective method of imaging pediatric appendicitis was to start with a US study and follow each negative US examination with a CT scan. These were the reasons behind our protocol in radiological evaluation of our patient, even though the process is not routinely done in our environment.<sup>14, 15</sup>

## Conclusion

A case of retrocecal acute appendicitis in a nine-year-old child with confusing clinical picture diagnosed by US has been presented. The findings of an inflamed retrocecal appendix with appendicolith at US guided the surgeons to perform an emergency appendectomy. We suggest that routine use of ultrasound should be encouraged in management of acute abdomen with particular attention to diagnosis of acute appendicitis in our environment.

## REFERENCES

1. Rosendal K, Aukland SM, Forsee K. Imaging strategies in children with suspected appendicitis. *Eur Radiol* 2004; **14**: L 138–45.
2. Adesunkanmi AR, Oseni SA, Adejuyigbe O, Agbakwuru E. A. Acute generalized peritonitis in African children: assessment of severity of illness using modified APACHE II score. *ANZ J Surg.* 2003;**73**: 275–9.
3. Hernandez JA, Swischuk LE, Angel CA *et al*. Imaging of Acute Appendicitis: US as primary imaging modality. *Pediatric Radiology* 2005; **35**: 392–395.
4. Hamilton E.J. Editor: *Textbook of Human Anatomy* 2<sup>nd</sup> edition 1976 p 387
5. Flum DR, Koepsell T. The clinical and economic correlates of misdiagnosed appendicitis: nationwide analysis. *Arch Surg* 2002; **137**: 799–804.
6. Von Tittle SN, McCabe CJ, Ottionger LW. Delay appendectomy for appen-

- dicitis causes and consequences. *Am J Emerg Med* 1996; **14**: 620–622.
7. Taylor GA. Suspected appendicitis in children: In search for the single best diagnostic test. *Radiology*, 2004; **231**: 293–5.
  8. Vissers RJ, Lennarz WB. Pitfalls in appendicitis. *Emerg Med Clin North Am* 2010; **28**: 103–18.
  9. Ceres L, Alonso I, Lopez P, Para G, Echeverry J. Ultrasound study of acute appendicitis in children with emphasis on the diagnosis of retrocaecal appendicitis. *Pediatr Radiol* 1990; **20**: 258–61.
  10. Field S, Morrison I. The acute abdomen. In Textbook of Radiology and Imaging. Sutton D ed. Churchill Livingstone Elsevier Philadelphia USA, 2003 Vol2 p 683.
  11. Vegar-Zuboviæ S, Lincender L, Dizdareviæ S, Sefiæ I, Dalagija F. Ultrasound signs of acute appendicitis in children – clinical application. *Radiology and Oncology* 2005; **39**: 15–21 + 82
  12. Puylaert JB. Acute appendicitis: US evaluation using graded compression. *Radiology* 1986; **158**: 355–60.
  13. Ang A, Chong NK, Dareman A. Pediatric appendicitis in “real time”: the value of sonography in diagnosis and treatment. *Pediatr Emerg Care* 2001; **17**: 334–40.
  14. Chui-Mei Tiu, Yi-Hong Chou, Jen-Dar Chen, Yi-Yiou Chiou, Hong-Jen Chiou, See-Ying Chiou, *et al.* Ultrasound diagnosis of acute appendicitis: impact on cost and outcome in pediatric patients. *Journal of Medical Ultrasound* 2004; **12**: 69–74.
  15. Wan MJ, Krahn M, Ungar WJ, Caku E, Sung L, Medina LS, *et al.* Acute appendicitis in young children: cost effectiveness of US versus CT in diagnosis – a Markov decision analytic model. *Radiology* 2009; **250**: 378–86.