



Cerebellar Toxoplasmosis in HIV/AIDS: A Case Report

Toxoplasmose du cervelet dans le VIH / SIDA: Un rapport de cas

E. U. Emeka*, A. O. Ogunrin†, A. Olubunmi*

ABSTRACT

BACKGROUND: Toxoplasma encephalitis is a common presentation of Toxoplasma gondii infection of the central nervous system in the late stage of human immunodeficiency viral (HIV) infection. The definitive diagnosis requires demonstration of toxoplasma in brain tissue. However, neuro-radiologic demonstration (using Computed Tomography or Magnetic Resonance Imaging) of ring-enhanced multiple or single focal intracranial lesions in the presence of immunosuppression and prompt response to presumptive therapy are diagnostic in the absence of histological facilities. The rarity of toxoplasma lesions in the cerebellum prompts a high index of clinical suspicion and early institution of presumptive therapy in poor resource sub-Saharan countries like Nigeria.

OBJECTIVE: To illustrate the presentation of recurrent cerebellar toxoplasmosis in a patient with HIV/AIDS.

METHODS: A 34-year-old previously diagnosed HIV/AIDS male patient with right-sided cerebellar signs on neurological evaluation and a ring-enhancing lesion in the right cerebellar hemisphere on CT brain scan. An initial response to anti-toxoplastic drugs was short-lived due to poor compliance resulting in recurrence of lesion.

RESULTS: On initial evaluation a diagnosis of cerebellar space occupying lesion in a patient with HIV/AIDS was made. He responded to treatment with clindamycin, pyremethamine and pyridoxine. Following default in treatment for three months he represented with florid cerebellar features, but again responded rapidly to treatment.

CONCLUSION: Cerebellar toxoplasmosis is an infrequent complication of HIV/AIDS. Early diagnosis with neuro-imaging techniques and prompt institution of appropriate therapy results in remarkable improvement. *WAJM* 2010; 29(2): 123-126.

Keywords: Cerebellar; HIV/AIDS; toxoplasmosis; encephalitis.

RÉSUMÉ

CONTEXTE: Toxoplasma encéphalite est une présentation commune des *T gondii* infection toxoplasma du système nerveux central dans la phase tardive de l'immunodéficiência humaine virale (VIH). Le diagnostic définitif nécessite la démonstration de la toxoplasmose dans le tissu cérébral. Toutefois, la démonstration neuro-radiologie (en utilisant la tomodynamométrie ou imagerie par résonance magnétique) de l'anneau d'aide à l'unique ou multiple focal lésions intracrâniennes, en présence de l'immunosuppression et une réponse rapide au traitement présomptif sont de diagnostic en l'absence d'installations histologique. La rareté des lésions toxoplasmiques dans le cervelet provoque un indice élevé de suspicion clinique et l'établissement précoce d'un traitement présomptif en Afrique sub-saharienne des ressources des pays pauvres comme le Nigeria.

OBJECTIF: Afin d'illustrer la présentation de la toxoplasmose cérébelleux récurrents chez un patient avec le VIH / SIDA.

METHODES: A 34 ans déjà diagnostiqué le VIH / sida des patients de sexe masculin du côté droit des signes cérébelleux sur l'évaluation neurologique et une lésion d'amélioration de l'anneau dans l'hémisphère droit du cervelet sur scanner cérébral. Une première réponse à toxoplasmique médicaments anti fut de courte durée en raison de mauvaise observance résultant de la récurrence de la lésion.

RÉSULTATS: Sur l'évaluation initiale d'un diagnostic de lésion du cervelet l'espace d'occupation chez un patient avec le VIH / sida a été faite. Il a répondu à un traitement par la clindamycine, pyriméthamine et de la pyridoxine. Après une défaillance dans le traitement de trois mois, il a représenté avec floride caractéristiques cérébelleux, mais encore une fois réagi rapidement au traitement.

CONCLUSION: la toxoplasmose cérébelleuse est une complication rare du VIH / sida. Le diagnostic précoce de l'imagerie et les techniques de neuro institution rapide des résultats de la thérapie appropriée à l'amélioration remarquable. *WAJM* 2010; 29(2): 123-126.

Mots-clés: cérébelleuse, le VIH / SIDA; toxoplasmose, encéphalite.

*Dermatology Unit, Department of Medicine, University of Benin Teaching Hospital, Benin City, Nigeria, †Neurology Unit, Department of Medicine, University of Benin Teaching Hospital, Benin City, Nigeria

Correspondence: Dr. A. O. Ogunrin, Neurology Unit, Department of Medicine, PMB 1154, University of Benin, Benin City, Nigeria. E-mail: bunmifunmi@hotmail.com

Abbreviations: TE, Toxoplasmic encephalitis; HAART, Highly active anti-retroviral therapy; HIV, Human immunodeficiency viral; AIDS, Acquired immunodeficiency syndrome.

INTRODUCTION

Toxoplasmic encephalitis (TE) is the most common opportunistic infection causing encephalitis or focal cerebral lesions in HIV/AIDS occurring in about 3% to 40% of patients.^{1,2} This complication of AIDS is almost always observed in patients who have a chronic (latent) infection with *Toxoplasma gondii*. Therefore, patients who from the outset of their HIV infection or AIDS are known to have antibodies to *T. gondii* should be considered at risk for development of toxoplasmic encephalitis. In most cases, diagnosis is made on the basis of clinical symptoms and CT or MRI findings (contrast enhancing space occupying lesions of the brain).² Neuroradiologic studies may be highly suggestive of toxoplasmic encephalitis, but, at present, the definitive diagnosis can be made only by demonstration of *Toxoplasma* in brain tissue.³

The unique pathogenesis of toxoplasmic encephalitis in patients with AIDS makes intensive primary therapy followed by a lifelong suppressive regimen necessary.⁴ In tropical countries where CT is not readily available, the diagnosis may be based on clinical presentation and prompt response to therapeutic trial.^{4,5} Most cases of toxoplasmosis occurred in the cerebral hemispheres and the basal ganglia.⁶ There are few reports of cerebellar involvement presenting with tremors, ataxia and incoordination.⁶ The pattern of radiologic presentations of this complication has not been well documented among Nigerian patients with HIV/AIDS. We present a case of a male Nigerian with HIV/AIDS who had recurrent cerebellar toxoplasmosis.

Case Report

The patient a 34-year-old hotel manager residing in a metropolitan city of southern Nigeria presented at the Emergency Department of the hospital with a week's history of weakness of the right extremities, three days history of generalized throbbing headaches and a day's history of vomiting. The right-sided weakness was gradual in onset with associated gait disturbance and incoordination of the limbs especially of the hands and resultant inability to write.

In addition, he had vertigo. The headache, which was frontal and severe, was accompanied by visual blurring, photophobia and projectile vomiting. There was however no history of altered level of consciousness, seizures, antecedent head trauma, ear discharge or febrile illness. He has not been

previously diagnosed hypertensive or diabetic, nor used tobacco or alcohol. He had had unprotected intercourse with multiple sexual partners, and also received blood transfusion in the past.

General examination revealed a young man with oro-pharyngeal thrush but had no pallor, jaundice, pyrexia,

Table 1: Results of Laboratory Tests

Laboratory Test	Results	Normal range
Complete Blood Count		
Packed cell volume (%)	42	33–52
Haemoglobin (g/dl)	14	11–17
White cell count Differentials (%)		
Neutrophils	55	40–65
Lymphocytes	36	20–35
Eosinophils	9	2–4 mild eosinophilia
Platelets per mm ³	150 000	130 000–300 000
Erythrocyte sedimentation rate (mm/h)	60	12–32 (Westergren)
Fasting blood sugar (mg/dl)	96	50–110
Urea (mg/dl)	21	12–45
Electrolytes (mmol/L)		
Serum Sodium	128	120
Serum Potassium	3.7	3.2–4.5
Serum Chloride	100	90–110
Serum Bicarbonate	15	15–25
HIV screen (ELISA)	Positive	

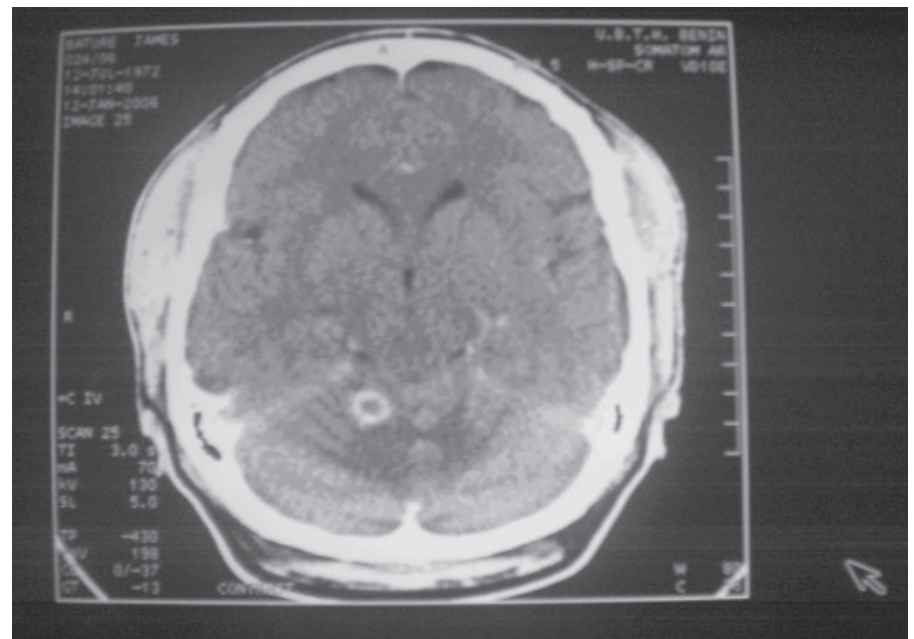


Fig. 1: Computerized brain scan showing a ring enhancing lesion in the right lobe of the cerebellum without associated peri-lesional oedema (arrow pointing at lesion). Possible differential diagnoses include cerebellar toxoplasmosis, pyogenic cerebellar abscess, and cerebellar tuberculoma.

dehydration, peripheral fluid retention or lymphadenopathy. The examination of the respiratory and abdominal systems was unremarkable. He had a mildly elevated blood pressure of 130/100mmHg with a pulse rate of 96/min.

Neurological evaluation revealed an intact sensorium with a slightly slurred speech, right ocular nystagmus, evidence of right-sided dysmetria in both upper and lower limbs (impaired finger-nose test and heel-knee-shin test), right-sided adiadochokinesia, broad-based (ataxic) gait with severely impaired tandem walk and tendency to fall to the right, and dysgraphia. There were no cranial neuropathy, signs of meningeal irritation or primitive reflexes. A clinical diagnosis of a possible cerebellar space demanding lesion in an immune-compromised patient was made. The results of investigations are as outlined in Table 1. Main laboratory abnormalities were eosinophilia, elevated ESR and positivity to HIV. Chest X-ray and urine tests were normal.

He was managed as a case of cerebellar toxoplasmosis complicating HIV/AIDS. He received clindamycin 300mg qid, pyrimethamine 50mg daily and pyridoxine 50mg daily. He improved remarkably with resolution of cerebellar signs and was discharged after seven days of hospitalization. He was enrolled into the highly active anti-retroviral therapy (HAART) as an out-patient but defaulted from the HIV/AIDS clinic for three months just before commencement of HAART. He presented again with florid cerebellar symptoms and was re-admitted. He responded to the anti-toxoplasmosis drugs within 10 days and was commenced on HAART thereafter.

DISCUSSION

Toxoplasmic encephalitis (TE) has been recognized as a major CNS complication in patients with AIDS and is the most frequent cause of focal intracerebral lesions in these patients.^{1,3} It is a life-threatening condition as an opportunistic infection in patients with acquired immunodeficiency syndrome (AIDS). A review of the literature reveals over 140 cases of toxoplasmosis in AIDS victims.⁵ Toxoplasmosis seems to be

more frequent in AIDS patients in Africa than those from Europe or America.⁷ In tropical countries, the frequency of TE in necropsy series of AIDS patients is high: 34% in Brazil, 23% in Côte d'Ivoire, and 19% in India.⁴ Risk factors for TE are a previous *Toxoplasma gondii* infection and a CD4+ cell count < 100/mm³.² Geographical differences in TE rates among patients with AIDS may be explained by the worldwide observed variation of *Toxoplasma* IgG seroprevalence.¹ Although serologic tests cannot distinguish active from latent infection, a patient who is seronegative for *Toxoplasma* antibodies is unlikely to have toxoplasmic encephalitis.

Toxoplasmic encephalitis presents with a constellation of symptoms and signs, of which only chorea is thought to be pathognomonic in patients with AIDS. Symptoms of TE range from lethargy to coma, ataxia to hemiparesis, loss of memory to severe dementia, and focal to major seizures.² A clinical review of 81 cases by Holliman³ revealed deterioration in mental status in 42, neurological signs in 39, fever in 36, and persistent headache in 31. In a Tanzanian population with HIV/AIDS,⁷ neurological disorders were among the main clinical features. Advanced and terminal AIDS cases were more likely to have neurological disorders than early AIDS patients with 10.5% having an obvious focal neurological disorder, including cranial nerve palsies, hemiparesis and paraparesis, while tremor and incoordination occurred in 19% of patients with neurological disease. When human immunodeficiency virus (HIV) infection is associated with slowly evolving dementia and the preservation of consciousness, toxoplasmosis typically results in an acute deterioration in mental state.⁸

In a study by Ho *et al.*⁶ the most commonly affected CNS region in TE was the cerebral hemisphere, followed by the basal ganglia, cerebellum and brain stem. In an autopsy study of 23 patients with TE, the rostral basal ganglion was the most frequently affected region.⁹ Although the presence of multiple ring-enhancing lesions with surrounding oedema and a positive serology is highly suggestive of TE, other common focal

brain lesions in HIV-infected patients must be considered and these include progressive multifocal leuco-encephalopathy, primary CNS lymphoma and tuberculosis. The less common causes include *Nocardia*, varicella zoster virus, *Aspergillus*, *Listeria*, *Treponema pallidum*, *Histoplasma* and *Cryptococcus* infections.¹⁰ In a series that assessed the method of diagnosis and response to therapy in 14 patients with evidence for toxoplasmosis based on routine histopathology, immunoperoxidase staining, or mouse inoculation, excisional biopsies showed tachyzoites on routine histology, but needle biopsies were usually negative unless mouse inoculation or immunoperoxidase staining was employed.¹¹

Pyrimethamine with sulfadiazine or clindamycin is the standard regimen for TE.¹² In addition, response to pyrimethamine and sulfadiazine therapy was often prompt, but therapy had to be continued for long periods of time to maintain a clinical response, and no alternative regimen of one or more drugs appeared to be effective in patients unable to tolerate both pyrimethamine and sulfadiazine.¹¹ It has been observed previously that TE may recur in patients who fail to comply with secondary prophylaxis and HAART.⁶ A prospective study³ that evaluated clinical and diagnostic findings in 20 cases of toxoplasmosis associated with the Acquired Immune Deficiency Syndrome (AIDS) in south-east England observed that sampling of the cerebrospinal fluid was rarely performed and was found to be of little clinical value and in addition, sulphonamide plus pyrimethamine was the treatment of choice in most cases and response to therapy was satisfactory, although a high incidence of toxicity was recorded. A poor response to toxoplasmosis treatment is associated with failure to reach an early diagnosis, late initiation of drug therapy, and the lack of contrast enhancement of lesions detectable by computerized tomography.

Adverse reactions to these medications are common, occurring in as many as 25% to 53% of patients.^{13,14} Alternative less toxic medications namely, azithromycin, clarithromycin, atovaquone, and trimethoprim-sulfa-

methoxazole (TMP-SMZ) are under investigation.¹⁵ In an open study that followed up 21 patients who were treated with TMP-SMZ (160 mg trimethoprim and 800 mg sulfamethoxazole three times daily by oral or intravenous route for 4 to 6 weeks), clinical and radiological improvements occurred in 94% of patients. Severe toxicity leading to alternative treatment occurred in two patients. Considering large availability, good tolerance, easy management, and low cost, TMP-SMZ seems a treatment of choice for TE in tropical countries.^{4,10} The choice of clindamycin in our patient is based on the high frequency of adverse drug reactions associated with the sulphonamides. In our practice we have observed acceptable side effect profile with pyrimethamine and clindamycin regimen. As most patients will respond to their primary therapy, those who fail to improve clinically and radiologically to therapy within 10 days should be evaluated for additional or alternative causes of their intracerebral pathology. This will often necessitate brain biopsy.

REFERENCES

- Porter, SB, and Sande, MA. Toxoplasmosis of the central nervous system in the acquired immunodeficiency syndrome. *N Engl J Med.* 1992; **327**: 1643–1648.
- Luft, BJ, and Remington, JS. Toxoplasmic Encephalitis in AIDS. *Clin Infect Dis.* 1992; **15**: 211–222.
- Holliman, RE. Toxoplasmosis and the Acquired Immune Deficiency Syndrome. *J Infect.* 1988; **16**: 121–128.
- Cabre, P, Smadja, D, Cabie, A, Newton, CRJC. HTLV-1 and HIV infections of the Central Nervous system in tropical areas. *J Neurol Neurosurg Psychiatry* 2000, **68**: 550–557.
- Israelski, DM, Remington, JS. Toxoplasmic encephalitis in Patients with AIDS. *Infect Dis Clin North Am.* 1988; **2**: 429–445.
- Ho, Y, Sun, H, Chen, M, *et al.* Clinical presentation and outcome of toxoplasmic encephalitis in patients with human immunodeficiency virus type 1 infection. *J Microbiol Immunol Infect.* 2008; **41**: 386–392.
- Howlett, WP, Nkya, WM, Mmuni, KA, *et al.* Neurological disorders in AIDS and HIV disease in the Northern zone of Tanzania. *AIDS.* 1989; **3**: 289–296.
- Grant, A.D., Djomand, G., De Cock, K.M. Natural history and spectrum of disease in adults with HIV/AIDS in Africa. *AIDS.* 1997; Suppl B: S43–54.
- Strittmatter, C, Lang, W, Wiestler, OD, Kleihues, P. The changing pattern of human immunodeficiency virus-associated cerebral toxoplasmosis: a study of 46 postmortem cases. *Acta Neuropathol.* 1992; **83**: 475–481.
- Skieft, DJ. Focal neurological disease in patients with acquired immunodeficiency syndrome. *Clin Infect Dis.* 2002; **34**: 103–115.
- Wanke, C, Tuazon, CU, Kovacs, A, *et al.* Toxoplasma encephalitis in patients with acquired immune deficiency syndrome: diagnosis and response to therapy. *Am J Trop Med Hyg.* 1987; **36**: 509–516.
- Montoya, J.G., and Liesenfeld, O. Toxoplasmosis. *Lancet* 2004; **363**: 1965–1976.
- Richards, FO, Kovacs, JA, Luft, B. Preventing toxoplasmic encephalitis in persons infected with human immunodeficiency virus. *Clin Infect Dis.* 1995; 21(supp 1): S49–S56.
- Lane, H.C., Laughon, B.E., Falloon, J., *et al.* Recent advance in the management of AIDS-related opportunistic infection. *Ann Intern Med.* 1994; **120**: 945–955.
- Canessa, A., Del Bono, V., De Leo, P., *et al.* Cotrimoxazole therapy of Toxoplasma gondii encephalitis in AIDS patients. *Eur. J. Clin. Microbiol. Infect. Dis.* 1992; **11**: 125–130.
- Modi, M., Mochan, A., Modi, G. Management of HIV-associated focal brain lesions in developing countries. *QJM* 2004; **97**: 413–421.