



Acute Perforated Duodenal Ulcer in Maiduguri: Experience with Simple Closure and *Helicobacter pylori* Eradication

Aiguë ulcère duodénal perforé à Maiduguri: Expérience avec Simple fermeture et l'éradication de Helicobacter pylori

A. Nuhu*, A. G. Madziga, B. M. Gali

ABSTRACT

BACKGROUND: Effective medical management of peptic ulcer disease (PUD) has reduced the incidence of gastric outlet obstruction (GOO) as a complication, but perforation especially in the elderly remains unchanged and is in fact on the increase. There is a changing trend in emergency surgery for perforated duodenal ulcer (PDU) from definitive anti-ulcer surgery to simple closure followed by *Helicobacter pylori* eradication. **OBJECTIVE:** To present our experience in managing PDU with simple closure followed by *Helicobacter pylori* eradication. **METHODS:** This was a chart review of patients managed for PDU over a nine-year period (Jan 1999–Dec 2007) using information obtained from ward admission registers, theatre operation registers, and patients' case files from the medical records department. The patient's biodata, clinical, and operative findings as well as treatment outcome were extracted for analysis.

RESULTS: Of 55 patients eligible for analysis, 44 (80%) were males and 11(20%) females (M: F=4:1). Their ages ranged between 18 and 65 years with a mean \pm SD of 39.9 \pm 13.5 years. Most of the patients [34 (61.8%)] were below 40 years of age and majority 39(71.0%) had a history suggestive of chronic peptic ulcer disease. Twenty-six (47.3%) patients presented within 24 hours of perforation, while nine (16.4%) presented more than 72 hours afterwards. The latter group accounted for most [five(55.6%)] of the mortality. All the perforations were anterior pyloroduodenal and all except one had simple closure with omental patch followed by a course of a proton pump inhibitor and *Helicobacter pylori* eradication therapy.

CONCLUSION: Simple closure with omental patch followed by *Helicobacter pylori* eradication is effective in managing PDU with low morbidity and mortality despite patients' late presentation in our center. This technique is recommended in place of a definitive ulcer surgery. *WAJM* 2009; 28(6): 384–387.

Keywords: *Helicobacter pylori*, duodenal ulcer, perforation of, management, open simple closure, outcome.

RÉSUMÉ

CONTEXTE: la gestion médicale efficace des ulcères gastro-duodénaux (UGD) a réduit l'incidence de l'obstruction gastrique (GOO) comme une complication, mais la perforation en particulier chez les personnes âgées demeure inchangé et est en fait en augmentation. Il ya un changement de tendance dans la chirurgie d'urgence pour un ulcère duodénal perforé (PDU) de droits antidumping définitifs, opération d'un ulcère à simple fermeture suivie par l'éradication d'*Helicobacter pylori*.

OBJECTIF: Présenter notre expérience dans la gestion des PDU avec simple fermeture suivie d'éradication de *Helicobacter pylori*.

MÉTHODES: Il s'agissait d'un examen des dossiers des patients pris en charge pour les PDU sur une période de neuf ans (janvier 1999-décembre 2007) en utilisant les informations obtenues à partir des registres d'admission Ward, les registres de salle d'opération, et les dossiers des patients du département des dossiers médicaux. Données biologiques du patient, clinique, et les constatations opératoires et les résultats du traitement ont été extraites pour analyse.

RÉSULTATS: Sur 55 patients éligibles pour l'analyse, 44 (80%) étaient des garçons et 11 (20%) femmes (M: F = 4:1). Leur âge variait entre 18 et 65 ans avec une moyenne \pm DS est de 39,9 \pm 13,5 ans. La plupart des patients [34 (61,8%)] ont été inférieures de 40 ans et la majorité 39 (71,0%) avaient des antécédents évocateurs d'une maladie chronique, l'ulcère gastro-duodéal. Vingt-six (47,3%) patients ont présenté dans les 24 heures de perforation, tandis que neuf (16,4%) ont présenté plus de 72 heures après. Ce dernier groupe a représenté pour la plupart des [cinq (55,6%)] de la mortalité. Toutes les perforations sont antérieures pyloroduodénale et tous sauf un avaient de fermeture simples avec le patch omentale suivie d'une formation d'un inhibiteur de pompe à protons et le traitement d'éradication d'*Helicobacter pylori*.

CONCLUSION: la fermeture simple avec le patch omentale suivie par l'éradication d'*Helicobacter pylori* est efficace dans la gestion des PDU avec faible morbidité et de mortalité, malgré la présentation tardive des patients dans notre centre. Cette technique est recommandée au lieu d'une chirurgie de l'ulcère de définitif. *WAJM* 2009; 28 (6): 384–387.

Mots-clés: *Helicobacter pylori*, ulcère duodéal, perforation, la gestion, la fermeture simple, ouvert, résultat.

Department of Surgery, University of Maiduguri Teaching Hospital, P.M.B. 1414, Maiduguri, Nigeria.

*Correspondence: Dr Ali Nuhu, E-mail: nuhualinwva@yahoo.com

Abbreviations: GOO, Gastric outlet obstruction; NSAID, Non-steroidal anti-inflammatory drugs; PDU, Perforated duodenal ulcer; PUD, Peptic ulcer disease.

INTRODUCTION

Acute peptic ulcer perforation is a frequent cause of generalized peritonitis in the Nigerian environment.³ Effective medical management of PUD with proton pump inhibitors and therapy to eradicate *Helicobacter pylori* has limited the operative management of this disease to its complications.¹⁻³ The operative management of PDU varies.^{4,5} There is a general shift from the traditional definitive peptic ulcer surgery to simple closure with pedicled omentum after Graham⁶ followed by a course of proton pump inhibitors and therapy to eradicate *Helicobacter pylori*.^{7,8} Definitive peptic ulcer surgery increases operative time and exposes the patient to prolonged anaesthesia. It also increases the risk of postoperative complications in the presence of generalized peritonitis.⁹ Because of these problems, the acceptable management principle seems to be avoidance of definitive acid reducing surgery in the presence of generalized peritonitis or peritoneal irritation. This is especially true in African patients who present late.⁹ We have managed patients with acute perforated duodenal ulcer by simple closure of the perforation with adequate peritoneal lavage followed by a postoperative course of proton pump inhibitors and antibiotics. This report is a review of the results of such treatment modality in our centre.

SUBJECTS, MATERIALS, AND METHODS

The records of patients managed for acute perforated duodenal at the University of Maiduguri Teaching Hospital (UMTH) in Maiduguri in Northern Nigeria, between January 1999 and December 2007 were reviewed. Their clinical records were obtained from the admission and discharge registers, theatre operation records and the medical records central library. Data extracted from the patient records included their bio-data, time of onset of symptoms, presentation, use of non-steroidal anti-inflammatory drugs (NSAIDs), history of peptic ulcer disease, resuscitative measures, operative findings, outcome of treatment and postoperative complications. Patients with other causes

of perforation were excluded from the study.

Diagnosis of peptic acid perforation was made from history, plain abdominal and chest radiographs, and confirmed at laparotomy; which was done after resuscitation with intravenous fluids and peri-operative antibiotics. Other investigations included haematological profile, serum urea and electrolytes and urinalysis. Adequate hydration was indicated by an hourly urine output of 30ml/hour. A naso- gastric tube was passed to decompress the stomach and maintained till bowel sounds returned.

Laparotomy was via an upper mid-line incision, where an exploration was carried out to identify the site of the perforation and an estimate of its size. The peritoneal cavity was copiously lavaged with warm normal saline and the perforation closed with deeply placed 2/0 chromic catgut sutures tied over a piece of pedicled or free omentum. Where the perforation was sealed, its integrity was ensured and the peritoneal cavity toileted as required. All the patients were on parenteral antibiotics for three days and continued for four days in those with purulent peritonitis. The abdomen was closed *en mass* with one nylon (polyamine) suture. Patients were discharged on oral omeprazole, metronidazole and amoxicillin for one month's treatment.

RESULTS

Demographic data and clinical features

Fifty-five patients had emergency surgery for acute perforated duodenal ulcer during the study period. These consisted of 44(80.0%) males and 11 (20.0%) females, giving a male to female ratio of 4:1. They were aged 18 – 65 years, with a mean age of 39.9±13.5 years. The peak frequency was in the fourth decade (31–40 years), see Fig 1. The duration of symptoms before presentation was a few hours to five days (mean 2.8 days). Twenty-six (47.3%) patients presented within twenty-four hours of onset of symptoms, 14 (circa 25%) between 24 and 48 hours and nine (16%) over three days after (Table 1. None of the perforations was associated with recent ingestion of

Table 1: Frequency of Signs and Symptoms in Acute Perforated Duodenal Ulcer

Clinical Feature	Number (%)
Severe abdominal pain	49(89.1)
Classical signs of peritonitis	46(83.6)
Abdominal distension	32(58.2)
Severe dyspepsia	32(58.2)
Fever	26(47.2)
Nausea	17(30.9)
Vomiting	14(25.5)
Constipation	3(5.4)
Shock	3(5.4)

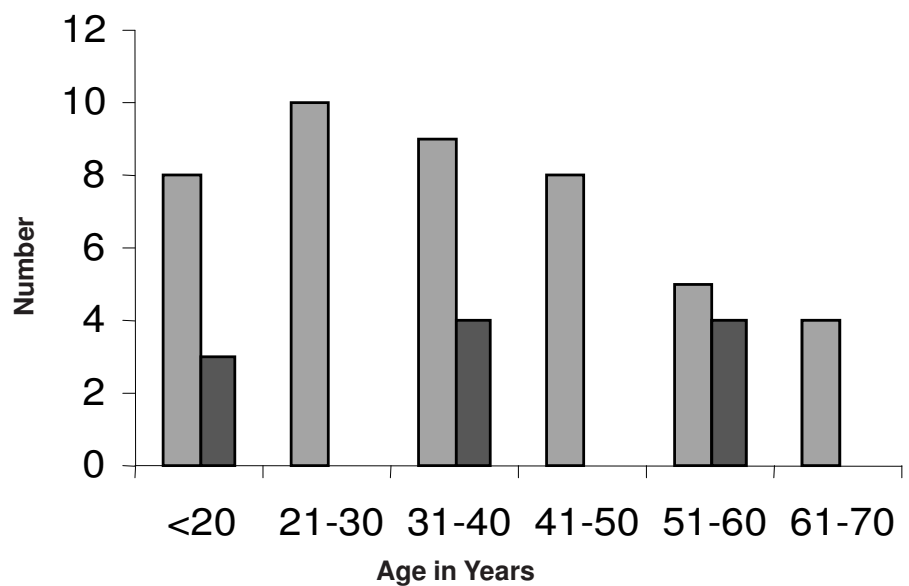


Figure: Distribution of Patients by Age and Sex Male Female.

NSAIDs. There was a history of chronic peptic ulcer disease in 39(71.0%) patients. The four commonest presenting symptoms were sudden onset of severe epigastric pain in 51(92.7%), vomiting in 19(34.5%), abdominal distention in 32 (58.2%) and fever in 16(29.1%). Abdominal tenderness and classical signs of peritonitis were demonstrable in 49(89.1%) and 46(83.6%) patients respectively, with three (5.4%) of the patients presenting in shock (systolic blood pressure \leq 80mmHg). Forty-nine (89.1%) of the patients had plain abdominal and chest radiographs done, with free gas under the diaphragm demonstrated in 32 (65.3%) of them.

Operative Findings

All the patients had anterior pyloroduodenal perforations with massive serous peritoneal fluid in 26 (47%), massive cloudy/opalescent peritoneal fluid in 12(22%) and frank peritoneal pus with fibrinoid adhesions in 17(31%) patients. Six of the perforations were found to be sealed while three were of minimal size (\leq 5 mm) and 43 were massive ($>$ 10mm).

Table 2: Frequency of Postoperative Complications following Omental Patch for Peptic Ulcer Disease.

Complication	Number (%)
Wound infection	12(21.8)
Postoperative fever	20(36.4)
Chest infection	11(20.0)
Intra-abdominal abscess	3(5.4)
Incisional hernia	3(5.4)
Wound dehiscence	3 (5.4)
Septicaemia	4(7.2)

Table 3: Relationship between Time of Presentation and Mortality.

Interval between Onset and Presentation (hours)	Number	Mortality N(%)
0 – 24	26	1(3.8)
24 – 48	14	2(14.3)
48 – 72	6	1(16.7)
$>$ 72	9	5(55.6)
Total	55	9(16.4)

Operative Procedures

Forty-eight (87.3%) of the patients had Graham's omental patch closure of the perforations. The simple closure was effected with either a pedicled omental patch (42 patients), or a free graft of omentum (six patients). Those with sealed perforations had peritoneal lavage with warm saline and mass closure of the abdomen. One patient had truncal vagotomy and roux-en-Y gastrojejunostomy in addition to simple closure.

Postoperative complications

The main postoperative complications were wound infection in 12 (21.8%), postoperative fever 20 (26.4%), chest infection 11 (20.0%) and incisional hernia in three (5.4%) patients, see (Table 2). There were four cases of leakage from the closure site that necessitated a re-exploration and closure. Three of these patients developed intra-abdominal abscesses that required open drainage. One of these patients developed peritonitis with septic shock that led to his demise.

Outcome

The relationship between mortality and duration before presentation is shown in Table 3.

The mean duration of hospital stay was 10 days (range 7–21 days) while the mortality rate was nine (16.4%). Causes of death included severe electrolyte derangement in three patients, septicaemia in four and acute renal failure in two others. There was no record of ulcer recurrence during a mean duration of follow-up of 5.2 month (range 2 weeks – 13).

DISCUSSION

Clinical Features

A total of 55 patients were treated for acute perforated duodenal ulcer in our hospital over a nine-year-period; giving an average of six cases per year which is a low incidence. This is similar to the four cases per year reported from Ile- Ife Southwestern Nigeria.¹⁰ Most of the patients [44(80%)] were males, similar to other studies where the male: female ratio ranged from 3.3:1 to 9:1.^{11,12} The

commonest age at presentation was between 21 and 40 years with a mean of 39.9 \pm 13.5 years which differs significantly from other reviews from Africa that had an average of 64.8 \pm 11.4 years.¹¹ In the Caucasian series, majority of the patients were above 60 years and the incidence higher in elderly females.¹³ Most of our patients 39(71.0%) had a past history of chronic peptic ulcer disease; this is in sharp contrast to 47% reported by Lawal and colleagues¹⁰ in south western Nigeria. The reason for this difference is not quite apparent. The diagnosis of acute PDU was mainly clinical in our series, with typical symptoms of perforation peritonitis manifesting especially in those with a past history of chronic peptic ulcer disease. However, a high index of suspicion supported by an abdominal paracentesis and the demonstration of free air under the diaphragm on a plain chest radiograph was needed to make a diagnosis in those with atypical features. In some, the final diagnosis was only made intraoperatively. There are well known risk factors for PDU such as corticosteroids ingestion, immunosuppression, alcohol, smoking and chronic ingestion of NSAIDs especially in elderly patients but none was a reason for perforation in our series. A report from Ghana showed that 47.7% of perforations seen were associated with the use of NSAIDs.¹¹ This may be related to the age composition of the patients in the Ghanaian study where, the mean age was above 60 years compared to our patients whose mean age was 39.9 years and 61.8% were below 40 years of age.

The time lapse between an episode of acute duodenal ulcer perforation and surgical intervention is a critical determinant of survival.¹⁴ Although 29(55.7%) of our patients had surgical intervention within 24 hours of presentation, and 23(44.2%) had theirs more than 24 hours afterwards, when this time is added to delays these patients had before presenting to hospital, it will be seen that majority of these patients actually had surgical intervention much more than 24 hours from time of perforation. A mean period of 22.15 hours between perforation and surgical intervention was reported in 156 patients

studied by Bin-Taleb and colleagues.¹⁵ A corresponding low overall mortality of 3.9% was reported in the same study compared to 16.4% in this study.

Operative Management

The findings at laparotomy vary depending on the site, size and duration of the perforation. All the patients in this study had anterior pyloroduodenal perforations; similar to other reported series.¹⁶ The size of the perforation determines the amount of peritoneal contamination.¹⁴ Forty-three (82.7%) of our patients had massive perforations, more than 10mm in approximate diameter. The degree of peritoneal soilage is crucial in patients with peritonitis due to acute duodenal ulcer perforation and early surgical intervention prevents further contamination of the peritoneal cavity and removes the source of infection.

Sealed perforations are a possibility at laparoscopy or laparotomy; the former was reported by Fujii and colleagues¹⁷ where it was managed conservatively with serial ultrasonography. This was seen in six (11.5%) of our patients. In our cases the peritoneum was thoroughly lavaged with three to five litres of warm normal saline, the site of the sealed perforation was inspected and its integrity ascertained, then the laparotomy wound was closed in-mass. The patients were subsequently managed on a four-week postoperative course of a proton pump inhibitor and therapy to eradicate *Helicobacter pylori* similar to those that had simple closure. Simple closure of perforated duodenal ulcer is generally accepted,^{12,18} particularly when there is delay in presentation and severe peritonitis has set in. This was the case in 29(52.9%) of our patients. The patients who presented within 24 hours of perforation were all treated by simple closure except one that had a definitive anti-ulcer surgery. These patients would have had one form of definitive anti-ulcer surgery or another to achieve a permanent cure for the ulcer diathesis; but currently with effective medical therapy using a course of proton pump inhibitors complimented with *Helicobacter pylori* eradication, this has become unnecessary. Simple closure has the added advantage of being easy,

quick, and safe and can be applied in most situations by most surgeons.

Postoperative Complications

The major postoperative complications were fever, wound infection, and chest infection (Table 4). The causes of these complications were multifactorial viz; delay in presentation, delay in surgical intervention, gross peritoneal soilage, septicaemia and shock. The delay in surgical intervention, after the patient presents to hospital, is usually due to the time taken to resuscitate these very ill patients. The mortality rate of 16.4% in our series is similar to the report by Barut and colleagues¹⁹ but low when compared to similar studies^{9,11} in the West African sub-region. This may be explained by the differences in age composition of the patients and other risk factors of perforation. The deaths were due to septicaemia and electrolyte derangements.

Conclusion

We conclude that simple closure with omental patch and proton pump inhibitors in combination with antibiotics to eradicate *Helicobacter pylori* the most common approach to treatment of acute perforated duodenal ulcer in Maiduguri is effective. Definitive ulcer surgery and treatment for *Helicobacter pylori* may be advocated in selected cases in the developing world where there may be doubt about compliance to drug therapy, follow-up and high chances of reinfection. Most of the mortality in this study was associated with late presentation.

REFERENCES

1. Dogo D, Yawe T, Gali BM. Gastric outlet obstruction in Maiduguri. *Afr J Med med Sci* 1999; **28**: 199–201.
2. Nasir H, Bernard K. G I Consult: perforated peptic ulcer. *Emerg Med* 2003; **35**: 17–19.
3. Jordan PH, Morrow C. Perforated peptic ulcer. *Surg Clin North Am*. 1988; **68**: 315–29.
4. Jordan PH Jr, Thornby J. Perforated pyloroduodenal ulcers, long term results with Omental patch and parietal cell vagotomy. *Ann Surg* 1995; **211**: 497–99.
5. Palanivelu C, Jani K, Senthilnathan P. Laparoscopic management of duodenal ulcer perforation: is it advantageous? *Indian J Gastroenterol* 2007; **26**: 64–6.

6. Graham RR. The treatment of perforated duodenal ulcers. *Surg Gynecol Obstet* 1937; **64**: 235.
7. Bose AC, Kate V, Ananthkrishnan N, Parija SC. *Helicobacter pylori* eradication prevents recurrence after simple closure of perforated duodenal ulcer. *J Gastroenterol Hepatol* 2007; **22**: 345–8.
8. Ng EK, Lam YH, Sung JJ, Yung MY, To KF, Chan AC, *et-al*. Eradication of *Helicobacter pylori* prevents recurrence of ulcer after simple closure of duodenal ulcer perforation: randomized controlled trial. *Ann Surg* 2000; **231**: 153–8.
9. Ersumo TW, Mesksl Y, Kotisso B. Perforated peptic ulcer in Tikur Anbessa Hospital: A review of 74 cases. *Ethiop Med J*. 2005; **43**: 9–13.
10. Lawal OO, Fadiran OA, Oluwale SF, Campbell B. Clinical pattern of perforated prepyloric and duodenal ulcer at Ile-Ife, Nigeria. *Trop Doct*. 1998; **28**: 152–5.
11. Ohene-Yeboah M, Togbe B. Perforated gastric and duodenal ulcers in an urban African population. *West Afr J Med*. 2006; **25**: 205–11.
12. Plummer JM, McFarlane ME, Newnham. Surgical management of perforated duodenal ulcer: the changing scene. *West Indian Med J*. 2004; **53**: 378–81.
13. Walt R, Katschinski B, Logan R, Ashley J. Rising frequency of ulcer perforation elderly people in the United Kingdom. *Lancet* 1986; **3**: 489.
14. Subedi SK, Afaq A, Adhikary S, Niraula SR, Agrawal CS. Factors influencing mortality in perforated duodenal ulcer following emergency surgical repair. *J Nepal M Assoc* 2007; **46**: 31–5.
15. Bin-Taleb AK, Razzaq RA, Al-Kathiri ZO. Management of perforated peptic ulcer in patients at a teaching hospital. *Saudi Med J*. 2008; **29**: 245–50.
16. Taj MH, Mohammad D, Qureshi SA. Outcome of omentopexy as primary repair in perforated duodenal ulcer. *J Coll Physicians Surg Pak*. 2007; **17**: 731–5.
17. Fujii Y, Asato M, Taniguchi N, Sheqeta K, Omoto K, Itoh K, *et al*. Sonographic Diagnosis and successful nonoperative management of sealed perforated duodenal ulcer. *J Clin Ultrasound* 2003; **31**: 55–8.
18. Gurleyik E. Changing trend in emergency surgery for perforated duodenal ulcer. *J Coll Physicians Surg Pak* 2003; **13**: 708–10.
19. Barut I, Tarhan OR, Cerci C, Karaguzel N, Akdeniz Y, Bulbul N. Prognostic factors peptic ulcer perforation. *Saudi Med J*. 2005; **26**: 1255–9.