



### Fournier's Gangrene Complicating Ruptured Richter's Inguinal Hernia

#### *Fournier's Gangrene compliquer rompu Richter hernie inguinale: Case Report*

U. U. Onakpoya, O. O. Lawal, O. D. Onovo, F. O. Oribabor

#### ABSTRACT

**BACKGROUND:** The deceptive entity of Richter's hernia typically presents with complications that are usually associated with high morbidity and mortality.

**OBJECTIVE:** The purpose of this case report is to highlight the association between Richter's groin hernia and Fournier's gangrene as demonstrated in a patient we managed recently.

**METHODS:** A case report of the management of an elderly patient who presented with Fournier's gangrene to a Nigerian tertiary institution following a neglected Richter's hernia on the right groin. The scrotal gangrene was managed by aggressive debridement and secondary closure while the ruptured caecal Richter's hernia was treated by a limited right hemicolectomy with end-to-end ileocolonic anastomosis and repair of the internal ring.

**REPORT:** We describe a rare case of Fournier's gangrene complicating a neglected caecal Richter's inguinal hernia in a 75-year-old Nigerian; highlighting the pathogenesis and management options.

**CONCLUSION:** Caecal Richter's hernia can be associated with Fournier's gangrene. *WAJM* 2007; 26(4): 316-318.

**Keywords:** *Fournier's gangrene; Richter's hernia; Nigeria; enterocutaneous fistula; hernia.*

#### RESUME

**CONTEXTE:** L'entité trompeur de Richter se présente généralement sous la hernie avec complications qui sont habituellement associées à des taux élevés de morbidité et de mortalité.

**OBJECTIF:** L'objectif de ce rapport de cas est de mettre en évidence l'association entre l'aine Richter hernie et Fournier gangrène comme l'a démontré un patient, nous sommes parvenus récemment.

**MÉTHODES:** A case report de la gestion d'un patient âgé qui a présenté avec Fournier gangrène un Nigérian à la suite d'une institution tertiaire négligé Richter hernie à l'aine droite. La gangrène scrotale était géré par le débridement agressif et secondaire, tandis que la fermeture de Richter s'est rompu caecal's hernie a été traitée par un droit limité hemicolectomy de bout-en-bout ileocolonic anastomose et la réparation de l'anneau interne.

**RAPPORT:** Nous décrivons un cas rare d'Fournier gangrène qui complique souvent négligée caecal Richter hernie inguinale en a 75-year-old nigériane; soulignant la pathogénèse et les options de gestion.

**CONCLUSION:** Caecal Richter hernie peut être associée à Fournier gangrène. *WAJM* 2007; 26(4): 316-318.

**Mots-clés:** *Fournier's gangrène; Richter hernie; Nigéria; fistules entéro; hernie.*

## INTRODUCTION

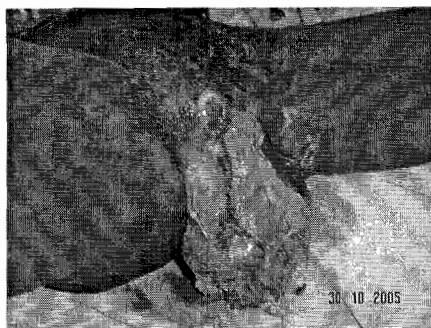
Richter in 1785,<sup>1</sup> described hernias in which only a portion of the circumference of the bowel was a content of the hernia sac such that when strangulated, bowel gangrene can occur without mechanical intestinal obstruction. Although atypical manifestations and complicated presentations in association with high morbidity and mortality are often encountered,<sup>2</sup> it is however rare for ruptured Richter's hernia to present with enterocutaneous fistulae leading to Fournier's gangrene.<sup>3</sup>

This report is about a rare case of neglected Richter's inguinal hernia complicated by Fournier's gangrene that was managed recently in our hospital.

## CASE REPORT

A 75-year-old Nigerian male farmer was admitted in October 2005 on account of a week old faeculent discharging and extensive right hemiscrotal ulcer. Earlier, he had carried for over two years, a right groin swelling which though painless and spontaneously reducible, had gradually progressed in size. Three weeks prior to presentation, the swelling suddenly became painful and irreducible and the patient had low-grade fever and vomiting. Two weeks later, the swelling ruptured and initially had a purulent discharge, which became faeculent later. About the same time, the scrotal sac became painful and swollen and dramatically ulcerated within 24 hours. He had not suffered chronic cough or dysuria nor had he any history suggestive of diabetes mellitus.

Physical examination revealed a dehydrated man but not in any distressful state otherwise. There was an ulcer in the right hemiscrotum measuring 20cm x 16cm with a perforated segment of bowel exposed at the neck of the scrotum, flush with the skin and discharging faeculent exudates (Figure 1). About 70% of the right scrotal wall was gangrenous and sloughed with foul-smelling discharge. A clinical diagnosis of ruptured Richter's inguinoscrotal hernia complicated by Fournier's gangrene was made. Pre-operative haematocrit, urinalysis, urea and electrolytes were within normal limits while scrotal wound swab grew coliform organisms. He was managed conserva-



**Figure 1: The patient, on presentation in the casualty, with an extensive right scrotal gangrene. The stoma is seen discharging faeculent exudates at the neck of the scrotum.**

tively with oral broad-spectrum antibiotics [ciprofloxacin 500mg bd and metronidazole 400mg tds], anti-tetanus prophylaxis and surgical scrotal debridement initially.

A full laparotomy carried out after he had been stabilized, revealed a 3cm x 2cm antimesenteric perforation of the caecum (on a mesentery) as the source of the faeculent discharge in the right groin wound. There were extensive adhesions within the inguinal canal. He had a limited right hemicolectomy with end-to-end ileocolonic anastomosis and the internal ring was repaired from within the peritoneal cavity.

The post-operative course was uneventful. The laparotomy wound healed primarily by the 7<sup>th</sup> day. The scrotal wound rapidly granulated and was secondarily closed two weeks after surgery. The patient was discharged home and was followed up in the clinic.

## DISCUSSION

The sublime course of Richter's hernia where strangulation of only part of the wall of the bowel in the sac occurs in the absence of mechanical intestinal obstruction had been reported as far back as 1785<sup>1</sup> by Richter himself. The usual presentation with a painful, tense, irreducible swelling which may be associated with fever, vomiting and sometimes diarrhea, were demonstrated by this patient. Unlike the findings of most reports where loops of ileum are commonly involved in Richter's hernia, it was the caecum that strangulated in this case. The unusual absence of lateral

fixation of the caecum and hence its mobility permitted it to be part of the content of the hernia sac which got strangulated in this patient. Although strangulated caecum in Richter's hernia is uncommon, Oluwole<sup>5</sup> and other workers<sup>6</sup> have reported similar cases. Rarer still is the occurrence of ruptured Richter's hernia on the groin being an aetiological factor in Fournier's gangrene as evidenced by a recent report of forty-one consecutive patients, in which no case of inguinal Richter's hernia was reported.<sup>3</sup> Indeed, based on Medline search and information, our patient, to the best of our knowledge, is the second case to be reported in the literature; the first being reported by Efem.<sup>4</sup>

The caeco-cutaneous fistula arising from the ruptured Richter's hernia in this patient, might have released an exudate rich in *Coliforms* amongst other bacteria which in the presence of bacterial endotoxin, streptokinase and hyaluronidase permeating through the plane between the external and internal spermatic fascias, set up an inflammatory reaction in the adjoining scrotum with consequent direct tissue damage, subcutaneous vessel thrombosis, scrotal skin ischaemia, necrosis and suppuration. This probably explains the complication of Fournier's gangrene with which he presented. The more common involvement of proximal ileal or jejunal loops with lesser bacterial counts in Richter's hernia may explain the infrequent concomitant occurrence of both Richter's hernia and Fournier's gangrene as seen in this patient.

Treatment of the Fournier's gangrene is fairly standard with systemic antibiotics, aggressive surgical debridement and scrotal cover.<sup>3</sup> Treatment of the predisposing factor is deemed important to ensure rapid healing of the scrotal wound.

More than half a century ago, Enna<sup>7</sup> advocated resection and primary anastomosis of the bowel, a practice commended itself for recommendation<sup>8</sup> because of the excellent post-operative outcome and obviation of the need for creating a stoma. Our patient did well on limited right hemicolectomy and end-to-end anastomosis of the ileum to ascending colon. The procedure was

simplified in this case by the absence of lateral fixation of the caecum and most of the ascending colon. Some other workers<sup>5</sup> have described complementary tube caecostomy particularly suitable for very ill patients as a less invasive and equally satisfactory alternative. Though this is appealing because of its simplicity, it is however a less attractive option in relatively stable patients who can withstand a resection and end-to-end anastomosis because of the attendant complications of the procedure such as leakage, post-operative intestinal obstruction as well as the psychological depression it may engender in a patient who previously had an enterocutaneous fistula. Tube care is also an added burden for the patient. Another surgical alternative especially in small bowel Richter's is a partial resection and transverse repair to prevent bowel stenosis.<sup>5,9</sup>

herniorrhaphy in the presence of an inflammatory process with oedema, haematoma and infection may lead to recurrence; just narrowing of the internal ring at the initial operation was adequate.<sup>8</sup> If required later, herniorrhaphy could then electively be performed.

In conclusion, caecal Richter's hernia can be associated with Fournier's gangrene.

REFERENCES

1. Steinke W, Zellweger R. Richter's hernia and Sir Frederich Treves: An original clinical experience, review and historical review. *Ann Surg.* 2000; **232**: 710-8.
2. Vervest AM, Eeftinck SM, Rietberg M. Richter's femoral hernia: A clinical pitfall. *Acta Chir. Belg.* 1998; **98**: 87-9.
3. Ayan F, Sunamak O, Paksoy SM, Polat SS, As A, Sakoglu N et al. Fournier's gangrene: A retrospective clinical study on forty-one patients. *ANZ J Surg.* 2005; **75**: 1055-8.

4. Efem SEE. Strangulated Richter's hernia presenting as Fournier's gangrene. *Postgrad. Doctor (Africa).* 1985; **7**: 181-2.
5. Oluwole SF. Complementary tube caecostomy in the management of strangulated Right Richter's inguinal hernia of the caecum. *J Natl Med Assoc.* 1982; **74**: 687-8.
6. Duari M. Stangulated femoral hernia- a Richter's type containing caecum and base of appendix. *Postgrad Med. J.* 1996; **42**: 726-8.
7. Enna CD, Guy E. Strangulated partial enterocoele within the femoral canal: Report of two cases treated by resection and primary anastomosis of the bowel. *J Kans Med Soc.* 1952; **53**: 4-8.
8. Limjoco UR, Grubbs JM, Thomas MD. Richter's hernia with bowel perforation [letter]. *Am Fam Physician.* 1998; **58**: 352, 354.
9. Kadirov S, Sayfan J, Friedman S, Orda R. Richter's hernia- a surgical pitfall. *J Am Coll Surg.* 1996; **182**: 60-2.

Since carrying out of formal inguinal

...the patient's condition with which he presented. The more common involvement of proximal ileal jejunal loops with lesser intestinal content in Richter's hernia may explain the infrequent occurrence of gangrene in Richter's hernia and Fournier's gangrene as seen in this patient.

...injury sustained with systemic antibiotics, systemic analgesia, abdominal and scrotal content, treatment of the predisposing factor is deemed important to ensure rapid healing of the scrotal wound.

...country also have advocated resection and primary anastomosis of the bowel (proctocolectomy) or resection of the caecum and proximal part of the ascending colon. On the other hand, the

...the post-operative course was unremarkable. The laboratory investigations were normal. The patient was discharged home two weeks after surgery. The patient was discharged home and was followed up in the clinic.

DISCUSSION

The aetiology of Richter's hernia is still controversial. It is a form of strangulated hernia in which only part of the wall of the bowel is incarcerated in the space of mechanical intestinal obstruction. It has been reported to be associated with a painful, tense, irreducible swelling which may be associated with fever, vomiting and abdominal distension. The diagnosis is usually made by the history of the hernia and the physical findings of a palpable, irreducible, tender mass in the groin.

...the patient's condition with which he presented. The more common involvement of proximal ileal jejunal loops with lesser intestinal content in Richter's hernia may explain the infrequent occurrence of gangrene in Richter's hernia and Fournier's gangrene as seen in this patient.

...injury sustained with systemic antibiotics, systemic analgesia, abdominal and scrotal content, treatment of the predisposing factor is deemed important to ensure rapid healing of the scrotal wound.