



Meigs' Syndrome Presenting as Haemorrhagic Pleural Effusion

Meigs le Syndrome Présentant avec Haemorrhagic d'Effusion Pleural.

E. I. Agaba*, C. C. Ekwempu[†], S. O. Ugoya*, G. O. Echejoh[‡]

ABSTRACT

BACKGROUND: The association of a benign ovarian tumor with ascites and hydrothorax that resolve after tumor resection, known as Meigs syndrome is a rare clinical entity. Rarer still is the haemorrhagic form of the syndrome

OBJECTIVE: To describe a case of benign ovarian tumour associated with ascites and bloody pleural effusion.

METHODS: A thirty-seven year old woman was referred for the further management of a pleural effusion. A detailed clinical evaluation was carried out, including pleural fluid cytology, chest CT scan and laparotomy. Treatment included antituberculous therapy and finally ovariectomy.

RESULTS: The physical examination and a pelvic ultrasonographic scan revealed ascites in addition to a right sided ovarian mass. A chest CT-scan did not show any intrathoracic mass. Repeated pleural fluid cytology showed mesothelial cells but was negative for malignancy. An ovariectomy was performed and histological examination revealed a thecoma fibroma. The pleural effusion and ascites resolved spontaneously thus confirming the diagnosis of Meigs' syndrome.

CONCLUSION: Meigs' syndrome should be considered in the differential diagnosis in female patients with hemorrhagic pleural effusion. *WAJM* 2007;26(3): 253 – 255.

Keywords: Meigs' syndrome; pleural effusion, haemorrhagic; thecoma fibroma; tuberculosis, misdiagnosis; ovariectomy.

RESUMÉ

Contexte: L'association d'une tumeur ovarienne bénigne avec ascites et hydrothorax qui résolvent après la résection de tumeur, connue comme le syndrome de Meigs est une entité clinique rare.

Rapport: Une dame de 37 ans a présenté avec une droite l'effusion pleurale, hémorragique et prise parti. Un examen physique et un balayage d'ultrasonographique pelvien ont révélé ascites en plus d'une droite a pris parti la masse ovarienne. Un CT-balayage de poitrine n'a pas montré de masse dans-thoracique. La cytologie fluide, pleurale et répétée a montré les cellules à mesothelial mais était négatif pour la malignité. Un ovariectomy a été exécuté et l'examen histologique a révélé un thecoma fibroma. L'effusion et ascites pleuraux ont résolu spontanément ainsi confirmant le diagnostic de Meigs le syndrome.

Conclusion: Meigs > le syndrome devrait être considéré dans le diagnostic différentiel dans les malades femelles avec l'effusion pleurale hémorragique. *WAJM* 2007;26(3): 253 – 255.

Mots clés: Meigs le syndrome, l'effusion pleural hémorragique, de fibroma de thecoma

Departments of *Medicine, [†]Obstetrics and Gynecology, and [‡]Histopathology, Jos University Teaching Hospital, Jos, Nigeria

Correspondence: Dr. Emmanuel I. Agaba, Department of Medicine, Jos University Teaching Hospital, P.M.B 2076, Jos, Nigeria.
E-mail: eiagaba@yahoo.com

Abbreviations: CA, Carbohydrate antigen; LE, lupus erythematosus

INTRODUCTION

The association of a benign ovarian tumor with ascites and hydrothorax that resolve after tumor resection is known as Meigs syndrome, and its importance was first emphasized by Meigs and Cass in 1937^{1,2}. It is a rare clinical entity. The associated features of ascites and hydrothorax are non-metastatic and the pathogenesis is at best speculative. The ascites is thought to result from filtration of interstitial fluid in the peritoneum through the tumor capsule, while the hydrothorax is believed to result from the diffusion to the pleural space, generally at the right side, through the diaphragm lymphatic vessels and the foramen of Bochdalek. The release of vasoactive substances (like endothelial growth factors and fibroblast growth factor) and interleukin-6 by the tumor have also been implicated as possible mechanisms. We present a case of Meigs' syndrome with haemothorax.

CASE REPORT

A 37-year old single P⁰⁺¹ pre-menopausal female university lecturer was referred on account of a two month history of right-sided hemorrhagic effusion. At the time of presentation, she had had four weeks of anti-tuberculous medications and systemic steroids. She had noticed a dull pleuritic ache on the right side of the chest 10 weeks before presentation at the referral hospital. She had no cough, shortness of breath, fever, night sweats, nor prolonged contact with persons with chronic cough but had lost weight. There was no history of trauma, joint pains, skin rashes or episodes of bleeding. She had not used any medications before onset of symptoms. Her menstrual cycle was regular but characterized by menorrhagia. She had a history of multiple sexual partners. She neither drank alcohol nor smoked cigarette.

Physical examination revealed an otherwise healthy looking lady with mild pallor. She was afebrile and was without significant peripheral lymphadenopathy. Her pulse was 80 beats per minute with a blood pressure of 110/70 mmHg. Chest examination showed stony dull percussion notes and reduced vesicular breath sounds over the mid and lower zones of the right hemi-thorax consistent

with pleural effusion. Thoracocentesis (performed three times) yielded a haemorrhagic aspirate that did not clot on standing. There was a vague pelvic mass on abdominal examination but no other organ enlargement was noted. The diagnosis of pulmonary tuberculosis was upheld in addition to that of an ovarian mass and the anti-tuberculous drugs were continued. A chest radiograph showed a right sided effusion (Fig. 1). Laboratory investigations showed a packed cell volume of 27% and a total white cell count of 5,200/ μ L (neutrophils 30%, lymphocytes 67% and eosinophils 3%). The erythrocyte sedimentation rate was 38mm/hr and the human immunodeficiency virus serology was unreactive. Rheumatoid factor and the LE cell preparation were negative. Tuberculin skin (Mantoux) test was 7mm. The pleural aspirate was exudative with a protein content of 32 g/L but negative for acid-

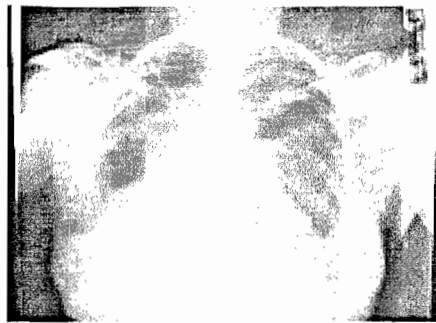

Figure 1: Chest radiograph showing right-sided pleural effusion

alcohol fast bacilli and yielded no growth on conventional culture media. Pleural fluid cytology showed mesothelial cells but was negative for malignancy. Abdomino-pelvic ultrasonography revealed a right mixed echogenic ovarian mass measuring 6.81 by 6.82 cm and ascites. A chest CT-scan showed pleural effusion but no intra-thoracic masses.

The anti-tuberculous therapy was discontinued after 10 weeks as there was no improvement in the pleural effusion. The suspicion of Meigs'syndrome was entertained and patient referred to the Gynecologist. At laparotomy, the findings were that of ascites and a right ovarian cyst for which she had ovariectomy performed. Ascitic fluid chemistry was not done as the fluid was not collected at

surgery. She had an uneventful recovery. Histology showed thecoma fibroma of the ovary (Fig. 2). A repeat chest radiograph taken eight weeks post




Figure 2: Histologic examination (H&E section) of the ovarian tissue showing thecoma fibroma of the ovary. Magnification x 40

surgery showed complete resolution of effusion confirming the diagnosis of Meigs' syndrome. She remained symptom free 10 months after surgery.

DISCUSSION

Meigs' syndrome is a rare clinical entity. The diagnosis of this syndrome depends on the resolution of ascites and pleural effusion following the surgical removal of ovarian thecoma fibroma¹ hence it is done in retrospect. It typically presents with serous transudative effusion; but hemorrhagic cases as observed in this patient have been reported². The pleural effusion is most commonly right-sided although it can involve the left only or can be bilateral. The differential diagnoses of tuberculosis, vasculitides, bronchogenic carcinoma and endometriosis need to be excluded in these patients, especially those presenting with hemothorax. The various screens for these illnesses turned out negative in our patient. A chemotherapeutic trial with anti-tuberculous agents was unrewarding as the effusion further worsened. Resolution of pleural effusion following resection of tumor is confirmatory and tumor removal remains the only treatment¹.

Varying levels of the tumor marker, serum carbohydrate antigen (CA 125), have been reported in Meigs'

syndrome and elevated levels have not been found to be suggestive of malignancy⁵⁻⁸. As such, this was not assayed in our patient as it does not aid the diagnosis of Meigs' syndrome. Other benign conditions associated with elevated levels of CA 125 include endometriosis, pelvic inflammatory disease and uterine leiomyoma⁹.

The ovarian fibromas and fibrothecomas are the commonest causes of Meigs' syndrome accounting for over 90% of the cases¹⁰. They present usually in the 5th and 6th decades of life. Other ovarian tumors associated with this syndrome include benign granulosa cell tumors and Brenners tumors. Hydrothorax and ascites have also been described in other pelvic tumors (ovarian and non-ovarian, benign and malignant), the so-called Pseudo (atypical) Meigs' syndrome¹¹⁻¹⁴. Similarly, tumor removal results in complete resolution of these features and is the only treatment.

This is one of the few cases of Meigs' syndrome to be reported in Nigeria to the best of our knowledge. It demonstrates that Meigs' syndrome, though rare, should be considered in the differential diagnosis of haemothorax in female patients. A high index of suspicion for is there fore needed.

REFERENCES

1. Meigs JV, Cass JW. Fibroma of the ovary with ascites and hydrothorax, with report of 7 cases. *Am J Obstet Gynecol.* 1937; **33**: 249 – 267.
2. Meigs JV. Fibroma of the ovary with ascites and hydrothorax - Meigs syndrome. *Am J Obstet Gynecol.* 1954; **67**: 962 – 987.
3. Abramov Y, Anteby SO, Fasouliotis SJ, Barak V. Markedly elevated levels of vascular endothelial growth factor, fibroblast growth factor and interleukin-6 in Meigs syndrome. *Am J Obstet Gynecol.* 2001; **184**: 354 – 355.
4. Abad A, Cazorla E, Ruiz F, Aznar I, Asins E, Llixiona J. Meigs' syndrome with elevated CA125: case report and review of the literature. *Eur J Obstet Gynecol Reprod Biol.* 1999; **82**: 97 – 99.
5. Siddiqui M, Toub DB. Cellular fibroma of the ovary with Meigs' syndrome and elevated CA-125. A case report. *J Reprod Med.* 1995; **40**: 817 – 819.
6. Jones OW 3rd, Surwit EA. Meigs syndrome and elevated CA 125. *Obstet Gynecol.* 1989; **73**(3 Pt 2): 520 – 521.
7. Shiau CS, Chang MY, Hsieh CC, Hsieh TT, Chiang CH. Meigs' syndrome in a young woman with a normal serum CA-125 level. *Chang Gung Med J.* 2005; **28**: 587 – 591.
8. Nemeth AJ, Patel SK. Meigs syndrome revisited. *J Thorac Imaging.* 2003; **18**: 100 – 103.
9. Vieira SC, Pimentel LH, Ribeiro JC, de Andrade Neto AF, de Santana JO. Meigs' syndrome with elevated CA 125: case report. *Sao Paulo Med J.* 2003; **121**: 210 – 212.
10. Majzlin C, Stevens FL. Meigs' syndrome: Case report and review of literature. *J Int Coll Surg.* 1964; **42**: 625 – 630.
11. Migishima F, Jobo T, Hata H, Sato R, Ikeda Y, Arai M et al. Uterine leiomyoma causing massive ascites and left pleural effusion with elevated CA 125: a case report. *J Obstet Gynaecol Res.* 2000; **26**: 283 – 287.
12. Sinawat S, Seejorn K. Pseudo-Meigs' syndrome secondary to subserous myoma uteri: a case report. *J Med Assoc Thai.* 2002; **85**: 1240 – 1243.
13. Tessmer CS, Barcellos FC, Falchi LC. Pseudo-Meigs' syndrome associated to renal pelvis tumor. *Int Braz J Urol.* 2005; **31**: 256 – 258.
14. Junaid I, Paz R, Salihu HM, Sharma PP, Aliyu ZY. Pseudo-Meig's syndrome with multiple synchronous benign and malignant pelvic tumors. *Arch Gynecol Obstet.* 2006; **273**: 315 – 318.