



Childhood Wilms' Tumour: Prognostic Factors in North Central Nigeria

Wilms d'enfance > la Tumeur : Les Facteurs pronostiques dans Nigéria Central du nord

A. F. Uba, L. B. Chirdan

ABSTRACT

BACKGROUND: Childhood Wilms' tumour or nephroblastoma represents one of the challenges for paediatric oncologists in developing countries.

OBJECTIVE: To review the clinical characteristics and outcome of management of childhood nephroblastoma in North- Central Nigeria.

METHODS: The clinical, operative and histological records of children aged 15 years and below, that were managed for Wilms' tumour at the Jos University Teaching Hospital between 1998 and 2005 were retrospectively reviewed.

RESULTS: There were 32 children (M:F=1.9:1) with histologically confirmed nephroblastoma seen over the 7-year period. Their median(range) age was 4 (3-15) years. The patients invariably presented with a palpable abdominal mass, but haematuria was exceptional. The neoplasm tended to be larger on average than those reported previously among Caucasian children. At presentation, 1(3.1%) patient was in stage I, 8(25%) stage II, 11 (34.4%) stage III and 12 (37.5%) stage IV. About 72% of the patients presented with stage III-IV disease. Poorly differentiated neoplasm was more common in male than in female patients. Nephrectomy and chemotherapy were the modality of treatment. Fifteen (46.9%) of the patients received little or no induction chemotherapy due to unavailability of drugs while only 12(37.5%) received the prescribed maintenance treatment with the remainder getting erratic or no treatment. Overall, only 43.8% were alive between 1 and 9 months (median: 6 months) of follow-up period, but there was no survivor at two years after treatment.

CONCLUSION: Childhood nephroblastoma has a high mortality rate in north central Nigeria because of late clinical presentation with advanced disease, poor availability of cytotoxic drugs and frequent interruptions in treatment and inadequate follow-up. *WAJM 2007; 26(3): 222 – 225.*

Keywords: Wilms' tumour, Nephroblastoma, Children, Prognosis, Northern Nigeria

RESUMÉ

Contexte: Wilms d'enfance > la tumeur ou nephroblastoma représentent un des défis pour les oncologues pédiatriques dans les pays en voie de développement.

Objectif: Pour réexaminer les caractéristiques et l'issue cliniques de direction de nephroblastoma d'enfance dans le Nord- Nigéria Central. **Méthodes:** Les enfants de dossiers de cliniques, opératifs et histologiques ont vieilli 15 années et au dessous, cela a été géré pour Wilms > la tumeur à l'Université de Jos Enseignant l'Hôpital entre 1998 et 2005 a été rétrospectivement réexaminé.

Résultats: Il y avait 32 enfants (M:F=1.9:1) avec avec nephroblastoma histologiquement confirmé vu par-dessus la période de 7 ans. Leur médiane (la gamme) l'âge était 4 (3-15) les années. Les malades ont présenté inmanquablement avec un tangible abdominal massif, haematuria était exceptionnel. Le néoplasme a eu tendance à être plus grand en moyenne que ces rapporté précédemment parmi les enfants caucasiens. A la présentation, 1(3.1%) patient was in malade était dans l'étape je, 8(25%) monter deux, 11 (III d'étape de) stage III and de 34.4%) stage III and et 12 (IV d'étape de) de 37.5%). Environ 72% des malades présentés avec monte la maladie d'III-IV. Le néoplasme mal différencié était plus commun dans le mâle que dans les malades femelles. Nephrectomy et la chimiothérapie étaient la modalité de traitement. Quinze (46.9%) of the patients) of the patients des malades a reçu très peu de chimiothérapie d'induction en raison de l'indisponibilité de drogues pendant que seulement 12(37.5%) received the prescribed a reçu le traitement d'entretien prescrit avec le reste obtenant irrégulier ou aucun traitement. Général, seulement 43,8% était vivant entre 1 et 9 mois (la médiane : 6 mois) de période de suite, mais il n'y avait pas de survivant à deux années après le traitement.

Conclusion: Nephroblastoma d'enfance a un haut taux de mortalité dans Nigéria central du nord à cause de la présentation clinique dernière avec la maladie avancée, la disponibilité pauvre de drogues de cytotoxique et fréquente des interruptions dans le traitement et suit-up. *WAJM 2007; 26(2): 222 – 225.*

Mots clés: Wilms la tumeur, Nephroblastoma, les Enfants, le Prognostic,, Nigéria

Paediatric Surgery Unit, Department of Surgery, Jos University Teaching Hospital, P.M.B. 2076, Jos, Nigeria

Correspondence: Dr Uba A. F., Paediatric Surgery Unit, Department of Surgery, Jos University Teaching Hospital, P.M.B 2076, Jos, Nigeria.
E-mail: afranu@yahoo.com

Abbreviations: NWTs; National Wilm's Tumour Study, WT; Wilms's Tumour

INTRODUCTION

Nephroblastoma (Wilms' tumour) is the most common malignant kidney tumour in childhood¹. Sometimes considered to be an 'index cancer of childhood' and like every other childhood cancer, Wilms' tumour (WT) is fast becoming an important paediatric problem in several parts of Africa². The management of childhood WT represents one of the challenges for paediatric oncologists in developing countries³. Although there have been improved survival rates from Wilms' tumour in the developed countries⁴⁻⁶, the same cannot be said of developing countries where late clinical presentation with advanced disease, poor availability of cytotoxic drugs, inadequate and frequent treatment interruptions abound⁷.

We examined the factors that affect prognosis of childhood nephroblastoma at Jos University Teaching Hospital, Jos in Nigeria, and this formed the basis of this report.

PATIENTS AND METHODS

The case records of all children aged 15 years or less with Wilms' tumor who were managed at the Jos University Teaching Hospital (JUTH), Jos, in Nigeria, from January 1998 to December 2005 were reviewed. The data were extracted from the clinical, operative and histological records. The preoperative diagnosis was based on the clinical, abdominal ultrasonographic and typical intravenous urographic findings. The work-up was based on abdominal ultrasound and chest X-ray. Tumour staging was according to National Wilms' Tumour Study Group 4 (NWTS-4).⁸ The data were analysed for age, gender, clinical features, treatment and outcome of treatment.

RESULTS

Thirty-two patients with histologically confirmed nephroblastoma were managed at the Jos University Teaching Hospital over the 7-year period, and this constituted 43.2% of all childhood intra-abdominal tumours managed within the period. Twenty (62.5%) were females and 12 (37.5%) were males (F: M=1.9:1); the median age-at-diagnosis of the patients was four years (range: 3-15 years). Eighteen (20.9%)

Table 1: Frequency of Clinical and Associated Features found in children with Wilms' tumour

Feature	Number (%) of patients
Abdominal mass	32 (100)
Fever	18 (56.3)
Abdominal pain	13 (40.6)
Cough	9 (18.8)
Hypertension	4 (12.5)
Epistaxis	3 (9.4)
Haematuria	3 (9.4)
Weight loss	3 (9.4)
Associated Features	
Hypospadias	3 (9.4)
Cryptorchidism	2 (6.3)
Aniridia	1 (3.1)

patients initially thought to have Wilms' tumour turned out to be neuroblastoma and so were excluded from the study.

Abdominal mass was the main symptom at presentation in all of them (100%), Fig 1. Haematuria was present in 3 (9.4%) patients. Eight (25%) patients had metastases to the lungs at presentation. One other patient had metastasis to the urinary bladder. The clinical features are summarised in Table 1. Four (12.5%) patients were hypertensive at presentation, with a mean blood pressure of 150/95 mmHg (range: 140/90 – 185/110 mm Hg).

Abdominal ultrasonography showed masses in all patients, with sensitivity of 100% and specificity of 85%. Intravenous urography showed sensitivity of 75% and specificity of 95%. Chest X-Rays confirmed pulmonary metastasis in 8 (25%) patients. Serum pulmonary metastasis in eight (25%)

patients. Serum electrolyte and creatinine levels were generally within normal range.

The tumour bulk varied in weight from 75g to 3.55 kg (average: 2.65kg) (Figs. 1-3). Twenty-three (71.9%) patients presented with stage III-IV disease (Table 2). One (3.1%) patient was in stage I, 8 (25%) in stage II, 11 (34.4%) in stage III and 12 (37.5%) in stage IV. The histologic variants were favourable in 23 and unfavorable in nine patients. The unfavourable types were anaplastic in seven (21.9%) patients (5 males, 2 females) and sarcomatous in two (6.3%), all males.

Two patients were discharged against medical advice even before any treatment could commence. Treatment was not randomized. Thirty (93.8%) patients had nephrectomy, 11 (34.4%) of whom had preoperative multi-agent chemotherapy (Vincristine 5mg/m², Actinomycin D 15 µg/m², Cyclophosphamide 1g/m², and Doxorubicin 20 mg/m²), using a modification of the protocol for treatment of Wilms' tumour in the recently completed NWTS-4⁹ (Table 3). In 15 (46.9%) patients, chemotherapy was commenced only postoperatively about a week later (even before the histology results became available about 2-3 weeks later) because of delay in the provision of cytotoxic drugs. Four (12.5%) other patients received no chemotherapy either because patients could not afford the prescribed drugs or months follow up period (P < .001). At a median follow-up period of 12 months (range: 1 to 18 months) there were only 2 (18.8%) survivors but had relapsed disease and with metastasis to the lungs. There were no survivors at 24 months of

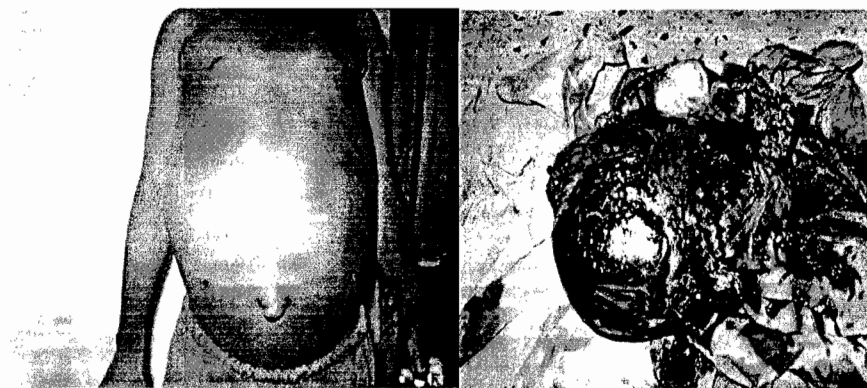


Fig 1. Abdominal appearance of a huge Wilms' tumour in the right kidney in a five-year old girl (left panel). The resected tumour in the same girl (right panel)

Table 2: Distribution of patients according to patient's age and stage of Wilms' Tumour

Age group (yrs)	Number of Patients Disease Stage				Total
	I	II	III	IV	
1 – 5	1	5	2	4	12
6 – 10	0	3	6	2	11
11 – 15	0	0	3	6	9
Total	1	8	11	12	32

Table 3: Details of chemotherapy regimen used for the treatment of Wilms' tumour

Disease Stage	Histology	Treatment Regimen
Stage I	Favourable histology; and unfavourable histology	<ul style="list-style-type: none"> • Vincristine (1.5 mg/m²) is given once in a week for 8-10 weeks; then at the beginning and end of each course of Actinomycin D; • Actinomycin D (15 µg/kg) is given on days 1-5.
Stage II	Favourable histology	<p>Same as in Stage I</p> <ul style="list-style-type: none"> • Doxorubicin (20 mg/m²) is given on days 1 – 3 beginning at the second course of Actinomycin D
Stage II	Unfavourable	
Stage III	Favourable histology; and unfavourable histology	Vincristine and Actinomycin D as in (1) above; plus • Doxorubicin (20 mg/m ²) is given on days 1-3 beginning at the second course of Actinomycin D
Stage IV	Favourable histology; and unfavourable histology	As in Stage III above plus Cyclophosphamide (1g/m ²) once in a week for 6 – 8 weeks:

Note: A course is repeated every 6 weeks for 18-24 weeks in stage I (FH or UFH) or Stage II (FH), and up to 66 weeks in stage III - IV (FH/UFH) & anaplastic variant. FH, favourable histology; UFH, unfavourable histology

follow-up. A highly significant difference in survival was noted when patients were stratified according to age-at-diagnosis. Stratification into age brackets demonstrated a strong correlation of diminishing survival with increasing age-at-diagnosis (Fig. 3). Nine-month survival rate in

patients within five years of age at diagnosis was 25.0%, whereas if the age-at-diagnosis six years or older the survival rate was 18.8% (p<.0001). Higher tumour stage and presence of distant metastasis were also factors predictive of a poor survival rate.

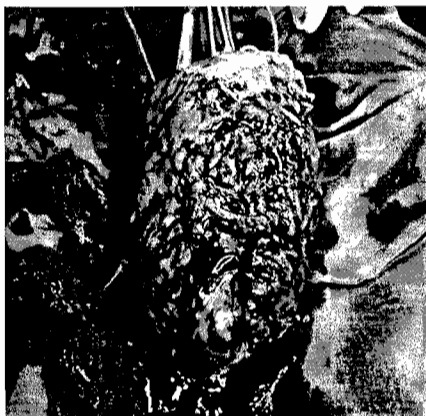

Figure 2: An excised advanced Wilms' tumour that had invaded inferior vena cava and other surrounding structures

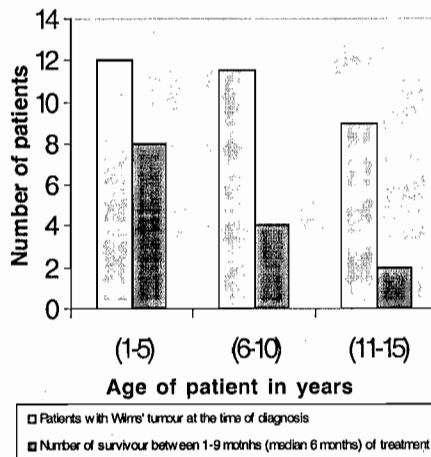


Figure 3: Relationship between age at diagnosis and period of survival in the course of treatment of Childhood

DISCUSSION

Nephroblastoma is a common childhood tumour, affecting approximately one child per 10,000 worldwide before the age of 15 years¹⁰. The incidence rates of WT appear to be higher in Blacks of U.S. and African origin compared to Whites, and only half as much among Asians¹. The tendency for Wilms' tumour to vary along ethnic rather than geographical lines suggests that genetic predisposition is important in its aetiology. WT constituted 43.2% of all childhood cancers in the present study. This rate is higher than those previously reported from other parts of Nigeria and the rest of Africa¹¹⁻¹⁷.

The female preponderance in this study agrees with the report by Akang et al¹⁸. Other studies reported either equal gender distribution³ or male preponderance^{1, 19}. The peak age of presentation is between two and three years in the developed countries^{1, 20}. The pattern of childhood WT in this study as in other tropical African countries is characterized by late presentation. For instance the majority of our patients presented late at a median age-at-diagnosis of around 4 years. This compares with the mean age of 3 years and 9 months reported from Tunisia²¹, but even lower than the 7.9 years reported from Congo Brazzaville¹⁹. The report by Nkrumah et al²² where two-thirds of their patients in Zimbabwe were younger than 4 years of age, is exceptional.

It is clear from the present study that age at diagnosis is an important prognostic factor in the management of childhood WT, because late presentation has a negative impact on the outcome of WT²³. Despite the favourable histology in majority of our cases, the prognosis was poor in part because of the advanced nature of the tumours which could have been caused partly due to late presentation. In a report by Abdallah and colleague⁷ where majority presented late with advanced disease, only about 34% remained disease-free two years from time of diagnosis.

History, physical examination and radiological findings are necessary elements in the differential diagnosis of the different renal tumors³. WT usually presents as painless, palpable abdominal

mass in an otherwise well child as was the case in the present study. In this study the neoplasms tended to be larger on average than those reported previously among Caucasian children¹⁸, but haematuria was uncommon. Poorly differentiated neoplasms were more common in male than in female patients, a similar trend that was reported by Akang et al¹⁸. The outcome of this group of poorly differentiated tumours was uniformly fatal.

Surgery remains the cornerstone of the management of Wilms' tumour²⁰. Dramatic improvement in overall survival rate in WT is ascribed to coordinated use of multimodal or multivariant approach to management comprising surgery, multiple drug chemotherapy and radiation therapy^{5, 21, 24}. Unfortunately our centre, as in many other centres in developing countries, lacks radiotherapy services. The outcome of WT in this study was especially poor. Factors of poor prognosis observed in our patients included advanced tumour stage, age greater than 5 years, unavailability of multimodal treatment facility and erratic or interrupted antimitotic treatment. A similar trend has been reported from Kenya⁷. One vital aspect of management of childhood WT is to monitor the therapeutic course in the postoperative period during follow up to verify tumor response; in many of our patients this was not possible because the patients were either lost to follow up or their compliance to treatment was too erratic due to frequent interruptions.

Late clinical presentation with advanced disease, lack of multidisciplinary treatment, poor availability of cytotoxic drugs, defaults and frequent interruptions of treatment with poor compliance are poor prognostic factors for childhood Wilms' tumour.

ACKNOWLEDGEMENT

This paper was presented at the 46th International Conference of West

African College of Surgeons, which took place in Accra, Ghana, from 5th-12th February, 2006.

REFERENCES

1. Stillier CA, Parkin DM. International variations in the incidence of childhood renal tumours. *Br J Cancer*. 1990; **62**: 1026 – 1030
2. Williams AO. Tumours of childhood in Ibadan. *Cancer*. 1975; **36**: 370 – 378.
3. Madani A, Zafad S, Harif M, Yaakoubi M, Zamiaty S, Sahraoui S et al. Treatment of Wilms' tumour according to SIOP protocol in Casablanca. *Pediatr Blood Cancer*. 2006; **46**: 472 – 475.
4. Fukuzawa M. Treatment strategy for children with Wilms' tumour. (Abstract). *Nippon Geka Gakkai Zasshi*. 2005; **106**: 422
5. Ohnuma N, Yoshida H, Matsunaga T, Kouchi K, Hishiki T, Yamada S, et al. Treatment strategy for malignant solid tumours in childhood. (Abstract). *Nippon Geka Gakkai Zasshi*. 2005; **106**: 413
6. Perlman E, Boccon-Gibod L. kidney tumours in childhood. *Ann Pathol*. 2004; **24**: 516 – 535.
7. Abdallah FK, Macharia WM. Clinical presentation and treatment outcome in children with nephroblastoma in Kenya. *East Afr Med J*. 2001; **78**: S43 – S47.
8. Green DM: Paediatric oncology update: Wilms' tumour. *Eur J Cancer* 1997; **33**: 409 – 418.
9. Othersen HB, Jr., Tagge PE, Garvin AJ. Wilms' tumour. In O'Neill JA, Jr, Rowe MI, Grosfeld JL, et al. (Editors) *Pediatric Surgery* 5th edition. Boston. Mosby. 1998; 391 – 403.
10. Breslow N, Oslhan A, Beckwith JB, Green DM. Epidemiology of Wilms' tumour. *Med Pediatr Oncol*. 1993; **21**: 172 – 181.
11. Obioha FI, Ikerionwu SE, Obi GO, Ulasi TO. The pattern of childhood malignancy in eastern Nigeria. *Ann Trop Paediatr*. 1989; **9**: 261 – 265.
12. Tijani SO, Elesha SO, Banjo AA. Morphological patterns of paediatric solid cancer in Lagos, Nigeria. *West Afr J Med*. 1995; **14**: 174 – 180.
13. Welbeck JE, Hesse AA. Pattern of childhood malignancy in Kole Bu Teaching Hospital, Ghana. *West Afr J Med*. 1998; **17**: 81 – 84.
14. Patil PS, Elem B, Gwavava NJ, Urban MI. The pattern of paediatric malignancy in Zambia (1980–1989): a hospital-based histopathological study. *J Trop Med Hyg* 1992; **95**: 124 – 127
15. Fischer PR, Ahuka LO, Wood PS, Lucas, S. Malignant tumors in children of northeastern Zaire. A comparison of distribution patterns. *Clin Pediatr (Phila)*. 1990; **29**: 95 – 98
16. Eke FU, Eke NN. Renal disorders in children: a Nigerian study. *Pediatr Nephrol*. 1994; **8**: 383 – 386
17. Hesseling PB, Wessels G, van Riet FA. The Tygerberg Hospital children's tumour Registry 1983-1993. *Eur J Cancer*. 1995; **31**: 1471 – 1475.
18. Akang EE, Okpala JU, Iliyasu Y, Lawani J. Clinicopathological study of nephroblastomas in Ibadan. *Br J Urol*. 1992; **70**: 381 – 321.
19. Peko JF, Moyon G, Gombe-Mbalawa C. Malignant solid tumours in Brazzaville children: epidemiological and anatomic-pathological aspects. *Bull Soc Pathol Exot*. 2004; **97**: 117 – 118.
20. Duffy PG, Ransley PG. Surgical management of Wilms' tumour. In: Spitz L, Coran AG. (Editors) *Rob & Smith's Operative Surgery*. 5th edition. London. Chapman & Hall Medical. 1995; 590-595.
21. Amel L, Leila BF, Lamia K. Histologic and prognostic study of nephroblastoma in central Tunisia. *Ann Urol (Paris)*. 2003; **37**: 164 – 169.
22. Nkrumah FK, Danzo AK, Kumar R. Wilms' tumour (nephroblastoma) in Zimbabwe. *Ann Trop Paediatr*. 1989; **9**: 89 – 92
23. Aguehounde C, da Silva-Anoma S, Roux C. Nephroblastoma at the hospital unit in Abidjan. Apropos of 60 cases. *J Urol (Paris)*. 1994; **100**: 196 – 199
24. Wu HY, Snyder HM 3rd, D'Angio GJ. Wilms' tumour management. *Curr Opin Urol*. 2005; **15**: 273 – 276.