



## Ocular Manifestations of Burkitt's lymphoma: Experience in Ile-Ife South Western Nigeria.

Manifestations Oculaires du lymphome de Burkitt: Un cas à Ilé -Ifé dans les Sud Ouest du Nigéria.

A.O.Adeoye\*, M.A.Durosinmi†, O.O.Adeodu‡, <sup>2</sup>M.B.Kagu†, S.O.Olateju\* , W.A.Olowu‡, IL. Salawu†, O.D. Kazeem†

### ABSTRACT

**BACKGROUND:** Burkitt's lymphoma is the most common childhood tumour in subSaharan Africa that typically affects the jaws and abdomen. Ocular involvement with blindness has been documented in some studies.

**Objective:** This was to evaluate the role of Burkitt's lymphoma (BL) as a cause of blindness in Nigerian children.

**METHODS:** Cases of BL seen in the hospital between 1986 and 2003 were studied retrospectively. Some of the patients with orbital disease at presentation underwent ultrasonographic examination of the eyes.

**RESULTS:** Forty-three (16.5%) of the 260 patients seen presented with orbital tumours; 29 (67.4%) of the 43 patients had full ophthalmic examination. The patients studied comprised 22 males and 7 females with a M: F ratio of 3:1, and median(age range) of 7(3-15) years. Orbital tumours occurred concurrently with jaw masses on the same side in 19(65.5%) of 29 patients; the eye diseases were unilateral in 23 (79.3%) and bilateral in six (20.7%) of the cases. Proptosis was the ocular presentation in 27(93%) of patients and it was associated with conjunctival injection in nine, chemosis in 11 and exposure keratopathy in five. Fourteen (48.3%) patients had associated blindness; 12 (85.7%) remained blind in the affected eye(s) and one regained vision to 6/36 after chemotherapy. The patients underwent Cyclophosphamide-Oncovin-Methotrexate (COM) regimen with intrathecal therapy. Eight (27.6%) patients had concomitant CNS disease; these included cases of 6th and 7th nerve palsies, one case of intra-cerebral extension of tumour and another case of total ophthalmoplegia.

**CONCLUSION:** Burkitt's lymphoma is an important cause of childhood blindness in Nigeria and the orbital disease is mainly extra ocular. WAJM 2007; 26(1): 48 – 52.

**Keywords:** Burkitt's lymphoma; orbital tumour; extraocular disease; blindness.

### RESUMÉ

**Contexte:** Le Lymphome de Burkitt est la tumeur infantile la plus commune en Afrique Sud-Saharienne qui affecte généralement les mâchoires et l'abdomen. L'implication oculaire avec la cécité visuelle ont été documenté dans quelques études.

**Objectif:** Le but de cette etude est d'évaluer le role du lymphome de Burkitt (BL) comme étant une cause de la cécité visuelle chez les enfants Nigériens.

**Méthodes:** Les cas du Lymphome de Burkitt (BL) observés dans les hôpitaux de 1986 à 2003 ont été restrospectivement étudiés. Certains patients avec les maladies à présentation orbitaires ont suivi des examens échographiques des yeux.

**Résultats:** Quarante-trois (16.5%) des 260 patients examinés ont présenté des tumeurs orbitaires; 29 (67.4%) des 43 patients ont eu des examens ophthamologiques complets. Cet etude comprenait 22 hommes et 7 femmes avec un rapport de 3 hommes pour une femme, et la médiane est de 7(3-15) ans. Les tumeurs orbitaires se produisent simultanément avec les masses de mâchoire du même côté chez 19(65.5%) des 29 patients, les maladies de yeux a été unilatérale chez 23 (79.3%) et bilatérale chez 6 (20,7%) des cas. La proptose était la présentation oculaire chez 27 (93%) des patients et elle était associée a l'injection conjontivite chez 9 des cas, la chemose dans 11 des cas et l'exposition Keratopathique dans 5 cas. Quatorze (48.3%) des patients avaient une cécité associée; 12 (85.7%) sont restés aveugles dans les yeux affectés et un seul à retrouver la vue à 6/36 après la chimiothérapie. Les patients ont suivi un regime Cyclophosphamide-Oncovin-Methotrexate (COM) avec une thérapie intrathécal. Huit (27.6%) des patients ont eu une maladie concomitante du System Nerveux Central; ceci comprend les cas des 6ieme et 7ieme nerf paralytiques, un cas de tumeur d'extension intra-cérébrale et un autre cas d'ophtalmoplégie totale.

**Conclusion:** Le lymphome de Burkitt est une cause importante de cécité visuelle infantile au Nigéria et la maladie orbitaire est principalement extra oculaire. WAJM 2007; 26(1): 48 – 52.

**Mots Clés:** Lymphome de Burkitt; Tumeur orbitaire; Maladie extraoculaire; cécité.

\*Departments of Surgery (Ophthalmology Unit), †Hematology and Blood Transfusion and ‡Dept of Paediatrics and Child Health, Obafemi Awolowo University Teaching Hospitals Complex (OAUTHC), Ile-Ife, Nigeria.

Correspondence: Dr. MA Durosinmi. E-mail: mdurosin@yahoo.com

Abbreviations: AIDS, Acquired immunodeficiency syndrome; BL, Burkitt's lymphoma; COM, Cyclophosphamide-Oncovin-Methotrexate; EBV, Epstein-Barr virus; EBVA, nuclear antigen.

## INTRODUCTION

Burkitt's lymphoma (BL) is a highly aggressive diffuse malignant B-cell lymphoma characterised by expression of surface membrane immunoglobulin (IgM), CD19, CD20, CD22 and CD10<sup>1</sup>. BL is the fastest growing neoplastic human tumour, with a doubling time of about 24 hours and a growth fraction of nearly 100%<sup>2</sup>. Epidemiologically, there are three types of BL, the endemic, sporadic and HIV/AIDS-related. The endemic BL is found mainly in the high-incidence zones of malarial holoendemic tropical rain forest of Africa 15° north and south of the equator, and other parts of the world with similar climatic conditions, such as Papua New Guinea.<sup>3,4</sup> Typically, endemic BL presents as an extranodal tumour of children and young adults with special predilection for the jaws and soft tissues of the orbit, abdomen and to some extent, the central nervous system.<sup>4,5</sup>

The tumour is the most common childhood malignancy in Nigeria<sup>6</sup> and most other countries falling within the same climatic belt.<sup>4,7</sup> The peak age incidence varies from 3 to 14 years (median, 7 years), with a male to female ratio of 2:1.<sup>4,5,8</sup> There is almost always evidence of prior Epstein-Barr virus (EBV) infection in the endemic BL in form of EBV nuclear antigen (EBVA) or EBV DNA (or RNA) in the tumour cells<sup>9</sup> as compared to 25-30% in the sporadic cases from Europe and North America,<sup>9,10</sup> 51% in South America<sup>9</sup> and about 75-80% in North Africa.<sup>11,12</sup> About 35% of AIDS-related BL cells express EBV positivity.<sup>13</sup>

Sporadic cases of BL occur typically in Europe and North America and constitute 30-50% of malignant lymphomas in children.<sup>9,10,14</sup> Unlike the clinical findings in endemic BL, sporadic BL is seen in older children and adults with frequent involvement of peripheral lymph nodes, abdomen (mainly ileocaecal region) and bone marrow. Tumours of the oropharynx and nasopharynx are also common.<sup>10,14</sup>

The clinical features of AIDS-related BL that account for about 20% of AIDS-related lymphomas in North America<sup>15</sup> are similar to those of sporadic BL, with greater frequency of peripheral node, abdominal and bone marrow disease.<sup>16</sup> The peak age incidence was

11-19 years<sup>15</sup>. BL is not normally associated with immunosuppression<sup>15</sup>; this probably explains why the AIDS epidemic has not affected the incidence of childhood BL in the endemic population of sub-Saharan Africa<sup>17</sup> as compared to the situation in Europe and North America.<sup>15-17</sup>

In contrast to the differential patterns of EBV expression between endemic BL and other BL subtypes, the c-myc gene deregulation is consistently found in all variants of BL. The deregulation involves clonal chromosomal translocations such as t(8;14) in a large majority of cases and less commonly t(2;8) and t(8;22).<sup>9,16,18</sup> The t(8;14) aberration involves chromosome 8 and the immunoglobulin heavy chain region of chromosome 14 while the others are between chromosome 8 and the light chain of either chromosome 2, t(2;8) or 22, t(8;22).<sup>18</sup> However, the so-called Burkitt's like lymphomas (BLL) are not associated with c-myc deregulation.<sup>19</sup>

Involvement of the orbit is frequent in Burkitt's lymphoma<sup>4,5,20</sup> and has resulted into blindness in a number of the affected patients.<sup>21-23</sup> The aim of the current study was to document intraorbital disease as a cause of blindness in Nigerian children with BL.

## PATIENTS AND METHODS

The Obafemi Awolowo University Teaching Hospitals Complex OAUTHC, Ile-Ife established in 1977 is the largest teaching hospital in Osun State, with catchments from the whole of Ondo, Ekiti and parts of Oyo and Kwara states, a predominantly Yoruba ethnic population of about 16.5 million people<sup>24</sup>. Ile-Ife lies within the BL endemic zone of equatorial rain forest of South West Nigeria; between latitude 7°N and 7°35'N, longitudes 4°20'E and 4°45'E.

Subjects included all cytologically and/or histologically confirmed cases of Burkitt's lymphoma consecutively managed between July 1986 and June 2003. Diagnosis of the tumour was confirmed from torch print cytology of the globe and histology of the exenterated tissue in one patient. The patients were managed jointly with the Paediatrics Department of the hospital. The

ophthalmologists reviewed all patients with orbital lesions at presentation. The biodata of each patient, duration of symptoms before presentation and the major presenting signs and symptoms were noted. The patients had full clinical and laboratory work up at presentation. All cases were staged according to Ziegler and Magrath's system<sup>25</sup>. All of the patients who had chemotherapy were treated with 4-6 cycles of 14-day of cyclophosphamide (1000mg/m<sup>2</sup>), oncovin (1.4 mg/m<sup>2</sup>) and methotrexate (37.5mg/m<sup>2</sup>) (COM) regimen, and twice weekly intrathecal methotrexate (12.5mg) with or without cytosine arabinoside (50mg) and hydrocortisone (25mg). Some of the patients with ocular tumour underwent ultrasonographic examination of the affected eye(s).

## RESULTS

Two hundred and sixty patients were seen over the 17-year period, giving an annual incidence of 15.3 cases per year. The ages of the patients ranged from 3 to 45 years with a median of 9 years. Forty-three (16.5%) of the 260 patients presented with orbital tumours; only 29 (67.4%) who had complete ophthalmic records were further evaluated.

### *Orbital Diseases (See Table)*

Orbital lesions were seen in 22 males and 7 females (M:F=3:1), with ages ranging from 3-15 years (median=7). The mean time interval between the developments of eye disease in relation to systemic disease was 1.9 weeks. Orbital diseases were concurrent with the ipsilateral jaws in 19(65.5%) of the 29 patients, with contralateral maxillary tumour in one patient, ipsilateral mandible tumour in one person and contralateral mandible in one other patient. One person had abdominal disease and orbital tumour at presentation and another person presented with only orbital tumour. Computed tomographic scan confirmed extension of tumour mass to the left frontal lobe and ipsilateral frontal skull bone in a 9-year old female patient with left maxillary tumour and left proptosis. All the patients had concomitant tumours of the jaw (s), except one that presented with proptosis alone, and diagnosis in this case was only confirmed by the histology

of the exenterated eye.

The eye diseases were unilateral in 23 (79.3%) and bilateral in six (20.7%) patients. Most of the patients 27(93%) presented with proptosis, which was associated with conjunctival injection in nine, chemosis in 11 and exposure keratopathy in five. Chemosis, conjunctival injection and proptosis occurred concurrently in 7 patients. The proptosis was bilateral in five patients. Eleven patients had proptosis and blindness at presentation (bilateral in three and unilateral in eight patients). Five (83.3%) of the six patients with optic atrophy also had proptosis.

Fourteen (48.3%) patients presented with total blindness (bilateral in three); the blindness was associated with proptosis alone in eleven cases, proptosis and optic atrophy in four and optic atrophy in another person. Other ocular lesions were purulent eye discharge, dilated pupil, retinal oedema and raised intraocular pressure (Table).

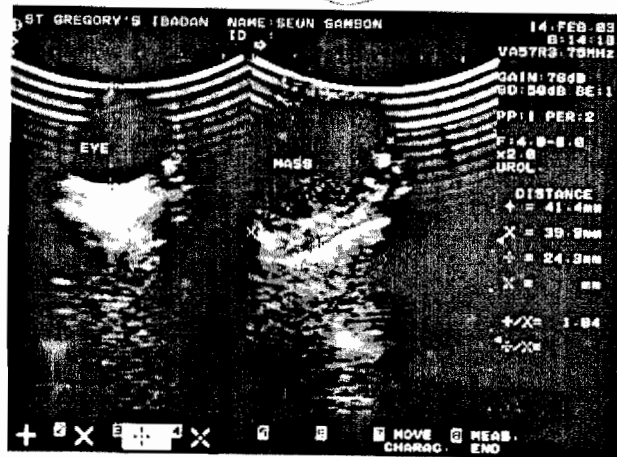
Eight (27.6%) patients had concomitant central nervous system (CNS) lesions; one had sixth cranial nerve palsy with associated intracerebral extension, two had sixth cranial nerve

palsy alone, four had seventh cranial nerve palsy and another person had total ophthalmoplegia.

The orbital tumours were mainly extraocular (Fig 1); there was no single case of intraocular tumour in the series. The blindness and poor visual outcome seen in these patients were due mainly to orbital compressive optic nerve neuropathy. One patient had intracerebral extension of Burkitt's lymphoma.

**Outcome of Therapy**

Twenty eight of the 29 patients with orbital lesions had varying cycles of COM regimen with intrathecal therapy (15 had 4-6 cycles, 8 had 2-3 and 5 had only one cycle). Of the 27 patients with proptosis (Table), one underwent exenteration of the affected eye before commencement of chemotherapy and another patient left before any chemotherapy. Regression of the



**Figure 1: Ultrasonography of the right and left eyes of patient 29 (OS, male/6).The right eye (21 AP) shows normal vitreous with no obvious mass seen. The left eye is displaced inferiorly and anteriorly by a 41 mm x 39 mm x 47 mm mixed echo mass with echogenic border. The vitreous is clear. No intra ocular lesion is seen. Retina is intact.**

**Table 1: Ocular Features of Orbital Burkitt's Lymphoma at Diagnosis**

Feature	Serial Number of patient																												Total	
	1	2	3	4	5	6	7	8	9	10	11	12	13	14	15	16	17	18	19	20	21	22	23	24	25	26	27	28		29
Bil	X					X	X							X	X			X												6
Unilat		X	X	X	X			X	X	X	X	X	X		X	X			X	X	X	X	X	X	X	X	X	X	X	23
VI	X	X	X	X	X	X	X		X	X	X	X		X									X						15	
E Dis					X			X				X						X		X				X					6	
P Orb									X	X	X	X	X		X								X	X	X				9	
Ptosis									X																				1	
C Inj		X	X	X	X					X	X								X				X					X	10	
Chem		X	X		X			X		X	X	X			X						X			X				X	11	
Prop		X	X	X	X	X	X	X		X	X	X	X	X	X	X	X	X	X	X	X	X	X	X	X	X	X	X	X	27
Kerat					X			X		X	X																		X	5
APD	X		X			X	X								X			X					X					X	8	
R Oed					X																									1
D Oed				X			X	X																					X	4
O Atr	X	X				X									X			X							X				6	
6thN	X	X		X																									4	
7thN										X		X	X															X	4	
Ophthl									X			X												X					3	
RIP								X																					1	
Blind	BL		Rt	Rt	Lt	BL	BL	Lt	Rt		Rt	Rt	Rt		Rt											Lt		Lt	14	

Bil, Bilateral; Uni, Unilateral; VI, visual impairment; E dis, Eye Discharge; P orb, Periorbital oedema; C inj, Conjunctival injection; Chem, Chemosis; Prop, Proptosis; Kerat, Keratopathy; APD, Afferent papillary dilatation; R oed, Retinal oedema; D oed, Disc Oedema; O atr, Optic atrophy; N, Nerve; Ophthl, Ophthalmoplegia; RIP, Raised intracranial pressure.

proptosis in the remaining 25 patients became evident after the first cycle of treatment in 16 (64%) and the 2<sup>nd</sup> and 3<sup>rd</sup> cycles in one person each; the cycles of chemotherapy given before resolution of proptosis were not indicated in the other 7 patients.

#### Patient Outcome

Twelve patients (41.4%) had complete remission, with full restoration of vision in five, partial restoration (6/36) of the affected eye in one, and persistent blindness in the other six patients (including the patient that had exenteration of the eye), five of these patients had since defaulted. Another twelve patients defaulted with active disease; two of who had early orbital relapse. Four (13.8%) other patients died after 2-6 weeks of admission (unspecified disease in one, septicaemia in another and meningitis in two) and one person was discharged against medical advice.

Twelve (85.7%) of the 14 patients that presented with blindness (including the one who left before therapy) remained blind in the affected eye(s), one regained vision to 6/36 with residual corneal opacity from exposure keratopathy and one other patient regained normal vision after regression of his bilateral proptosis.

Four patients with dilated pupils/ afferent pupillary defect had either optic disc oedema or optic atrophy from compressive optic neuropathy.

#### DISCUSSION

Almost all the patients (96.6%) with orbital Burkitt's lymphoma in this series were younger than 15 at presentation (median age 7). This is consistent with previous reports from Nigeria.<sup>20, 26-28</sup> The predominance of male sex is also in agreement with the general epidemiologic pattern of Burkitt's lymphoma in tropical Africa.<sup>4, 6</sup>

The rarity of intraocular disease in this series is not uncommon,<sup>20</sup> most of the cases being limited to retro-orbital space with compression of the optic nerve. This was the basis of blindness observed in many of our patients and it has been documented in previous reports.<sup>20, 21, 27</sup> The blindness that is often

associated with orbital lymphoma is usually irreversible; thus making Burkitt's lymphoma an important cause of childhood blindness in populations where the tumour is endemic.<sup>21-23, 29</sup> Twelve (85.7%) of the 14 patients that presented with blindness in the current series never regained their sights. Intraocular primary lymphoma, although very rare is also a recognised cause of total blindness in adults.<sup>30</sup>

In the series under review, only one patient (3.4%) presented with what appears to be a primary Burkitt's lymphoma of the orbit; the others had concomitant systemic disease that started about the same time with the eye disease at an interval of 0-8 weeks (mean  $\pm$  SD =  $1.9 \pm 2.8$ ). The tumour usually spreads from neighbouring primary sites in the jaw bones, in particular the maxillary bones in the majority of cases as shown in the current series; this pattern of metastases may probably explain the paucity of intraocular disease in orbito-ocular Burkitt's lymphoma<sup>20, 27</sup> compared to the adult non-Hodgkin's non-Burkitt's lymphoma, which tends to be intraocular in nature and often a primary disease<sup>30</sup>. The association of orbital Burkitt's with systemic disease is well documented.<sup>4, 20-22, 26, 27</sup>

As confirmed in this work, central nervous system disease is not uncommonly associated with orbital lymphoma;<sup>20, 22</sup> 27.6% of our patients had concurrent CNS complications, mainly sixth and seventh cranial nerve palsies, one of the patients with sixth cranial palsy had intracerebral extension of her tumour, a very unique presentation of Burkitt's lymphoma.<sup>29</sup>

Orbital tumour is a common presentation of Burkitt's lymphoma in Nigerian children; it is usually an intraorbital rather than intraocular lesion and it is an important cause of total blindness in children from Burkitt's endemic zones of the world.

#### ACKNOWLEDGEMENT

We thank all our colleagues in the departments of Paediatrics and Haematology for allowing us the use of their patients. We also thank the nursing officers in the paediatrics wards for their care.

#### REFERENCES

- Garcia C, Weiss L and Warnke R. Small noncleaved cell lymphoma: an Immunophenotypic study of 18 cases and comparison with large cell lymphoma. *Hum Pathol.* 1986; **17**: 454 – 461.
- Iversen OH, Iversen U, Ziegler JL and Bluming AZ. Cell Kinetics in Burkitt's lymphoma. *Eur J Cancer.* 1974; **10**: 115 – 163.
- Facer CA, Playfair JH. Malaria, Epstein-Barr virus and the genesis of lymphomas. *Adv Cancer Res.* 1989; **53**: 33 – 72.
- Magrath IT. African Burkitt's lymphoma: history, biology, clinical features and treatment. *Amer J Pediatr Hemato-oncology.* 1991; **13**: 222 – 246.
- Osunkoya BO. Burkitt's lymphoma In Chandra RK (eds) *Critical reviews in tropical medicine* (vol 1), N. York, Plenum Publishing Corporation, 1982.
- Adelusola KA, Odesanmi WO, Adejuyigbe O, Rufai OA, Durosinmi MA, Akinola NO. Malignant solid tumours in Nigerian children. *Cent Afr J Med.* 1995; **4**: 322 – 326.
- Magrath I, Jain V, Bhatia K. Epstein-Barr virus and Burkitt's lymphoma. *Semin cancer Biol.* 1992; **3**: 285 – 295.
- Olweny CLM, Katongole ME, Otim D. Long-term experience with Burkitt's lymphoma in Uganda. *Int J Cancer.* 1980; **26**: 261.
- Gutierrez MI, K Bhatia F, Barriga B, Diez FS, Muriel ML, de Andreas ML, et al. Molecular epidemiology of Burkitt's lymphoma from South America: differences in breakpoint location and Epstein-Barr virus association from tumours in other world regions. *Blood.* 1992; **79**: 3261 – 3266.
- Wright D, McKeever P, Carter R. Childhood non-Hodgkin lymphomas in the United Kingdom: findings from the UK Children's Cancer Study Group. *J Clin Pathol.* 1997; **50**: 128 – 134.
- Ladjadj Y, Philip T, Lenoir GM, Tazerout FZ, Bendisari K, Boukheloua R, et al. Abdominal Burkitt-type lymphomas in Algeria. *Br J Cancer.* 1984; **49**: 503 – 512.
- Anwar N, Kingma DW, Bloch AR, Mourad M, Raffeld M, Franklin J, et al. The investigation of Epstein-Barr viral sequences in 41 cases of Burkitt's lymphoma from Egypt: epidemiologic correlations. *Cancer.* 1995; **76**: 1245 – 52.
- Hamilton-Dutoit SJ, Raphael M, Audouin J, Diebold J, Lisse I, Pedersen C, et al. In situ demonstration of

- Epstein-Barr virus small RNAs (EBER 1) in acquired immunodeficiency syndrome-related lymphomas: correlation with tumour morphology and primary site. *Blood*. 1993; 15; **82**: 619 – 624.
14. Levine PH, Kamaraju LS, Connelly RR, Berard CW, Dorfman RF, Magrath I, et al. The American Burkitt's lymphoma Registry: eight years' experience. *Cancer*. 1982; **49**: 1016 – 1022.
  15. Beral V, Peterman T, Berkelman R, Jaffe H. AIDS-associated non-Hodgkin lymphoma. *Lancet*. 1991; **337**: 805 – 9.
  16. Knowles DM. Etiology and pathogenesis of AIDS-related non-Hodgkin's lymphoma. *Hematol Oncol Clin North Am*. 1996; **10**: 1081 – 1090.
  17. Parkin DM, Garcia-Giannoli H, Raphael M, Martin A, Katangole-Mbidde E, Wabinga H, et al. Non-Hodgkin lymphoma in Uganda: a case-control study. *AIDS*. 2000; **14**: 2929 – 2936.
  18. Bernheim A, Berger R, Lenoir G. Cytogenetic studies on African Burkitt's lymphoma cell lines: t(8;14), t(2;8) and t(8;22) translocations. *Cancer Genet Cytogenet*. 1981; **3**: 307 – 3015.
  19. Wright DH. What is Burkitt's lymphoma? *J Pathol*. 1997; **182**: 125 – 7.
  20. Olurin O and Williams AO. Orbito-ocular tumours in Nigeria. *Cancer*. 1972; **30**: 580 – 587.
  21. Olurin O. Etiology of blindness in Nigerian children. *Am J Ophthalmol*. 1970; **70**: 533 – 540.
  22. Ibrahim M, Ogala WN, Babayo FA, Onabolu OO, Afolayan EA. Burkitt's lymphoma presenting with blindness: a case report. *Ann Trop Paediatr*. 1990; **10**: 319 – 322.
  23. Ramesh K, Gahukamble LD, Gahukamble DB. Intracranial Burkitt's lymphoma with extension into orbital spaces resulting in bilateral blindness. *Cent Afr J Med*. 1994; **40**: 220 – 222.
  24. Population growth and projections: In 1991 Population Census of the Federal Republic of Nigeria. Analytical Report at the National Level, Abuja, National Population Commission, 1998; 318-380
  25. Ziegler JL, Magrath IT. Treatment of Burkitt's lymphoma. *Pathobiol Annu*. 1974; **4**: 129 – 142
  26. Williams AO. Tumours of the childhood in Ibadan, Nigeria. *Cancer*. 1975; **36**: 370 – 378
  27. Abiose A, Adibo J and Agarwal SC. Childhood malignancies of the eye and orbit in northern Nigeria. *Cancer*. 1985; **55**: 2889 – 2893
  28. Ajaiyeoba IA, Pindiga HU, Akang EE. Tumours of the eye and orbit in Ibadan. *East Afr Med J*. 1992; **69**: 487 – 489.
  29. Tekkok IH, Tahta K, Erben A, Buyukpamukcu M, Ruacan S, Topcu M. Primary intracranial extradural Burkitt-type lymphoma. A unique presentation with unilateral loss of vision in a child. *Childs Nerv Syst*. 1991; **7**: 172 – 174.
  30. Hoffman PM, McKelvie P, Hall AJ, Stawell RJ, Santamaria JD. Intraocular lymphoma: a series of 14 patients with clinicopathological features and treatment outcomes. *Eye*. 2003; **17**: 513 – 521.