

Human pentastomiasis: A case report

J. C. B. Dakubo, V. K. Etwire, R. Kumoji and S. B. Naaeder

Departments of Surgery and *Pathology,
University of Ghana Medical School
P. O. Box 4326 Accra, Ghana.
E-mail: jdakubo@yahoo.com

Summary

We report a case of human *pentastomiasis* in a 55-year-old farmer whose diagnosis was made incidentally during laparotomy on account of a mechanical small intestinal obstruction caused by adhesions. Encysted parasites and degenerative granulomas were found in the omentum and in the subserosal layer of the small intestine. These parasites were diagnosed as *Armillifer armillatus* larvae. The patient made an uneventful recovery after the operation and was discharged. He is being followed up.

Key-words: *Pentastomiasis, Tongue worm, Porocephalus, Armillifer, Linguatula.*

Résumé

Nous signalons le cas de pentastomiase chez l'homme. La maladie a été diagnostiquée par hasard chez un agriculteur de 55 ans au cours d'une laparotomie pratiquée à la suite d'une obstruction mécanique au niveau de l'intestin grêle, provoquée par des adhérences. On a trouvé dans l'omentum et dans la couche sous séreuse de l'intestin grêle des parasites kysiques et des granulomes en dégénérescence. Le diagnostic a révélé qu'il s'agissait de larves d'*Armillifer armillatus*. Le patient s'est rétabli sans incident après l'intervention chirurgicale et a été autorisé à sortir, mais sous surveillance.

Introduction

Pentastomiasis is a parasite zoonosis caused by *pentastomids* (tongue worm, *porocephalus*, *Linguatula*, *Armillifer*). Adult *pentastomids* are bloodsucking endoparasites of reptiles and carnivorous mammals.^{1,2,3}

Accidental infestation of man usually goes un-noticed but has on occasion been symptomatic or even fatal.^{4,5,6,7,8} Human infestation produces characteristic radiological and autopsy features however diagnosis by non-invasive diagnostic methods remain a challenge in un-calcified nymphs that produce symptoms.⁷

Pentastomiasis is a disease of the tropics and subtropics but has been reported from most parts of the world including America, Asia, Europe and Africa.^{1,3,9}

This is a case report of an incidentally diagnosed *Armillifer armillatus* in a 55-year-old man who was operated upon on account of a mechanical small intestinal obstruction at the Surgical Department of the Korle-Bu Teaching Hospital, Accra. To our knowledge this is the first officially reported case of human *pentastomiasis* in Ghana.

Case report

A 55-year-old male farmer presented to the surgical department of the Korle-Bu Teaching Hospital on 07/02/04




Fig. 1 An encysted larva (nymph) that was taken from the greater omentum

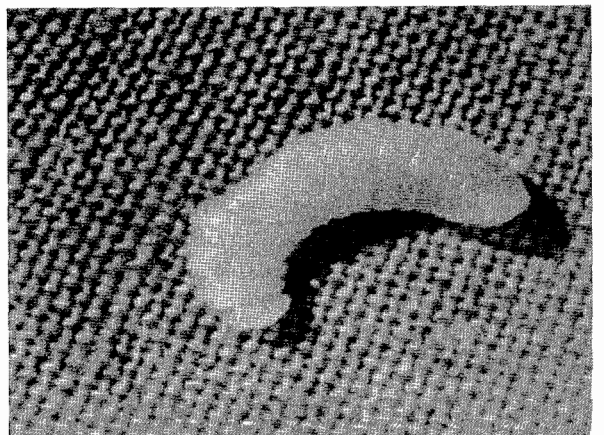


Fig. 2 A free larva (nymph) that was dissected out of a cyst.

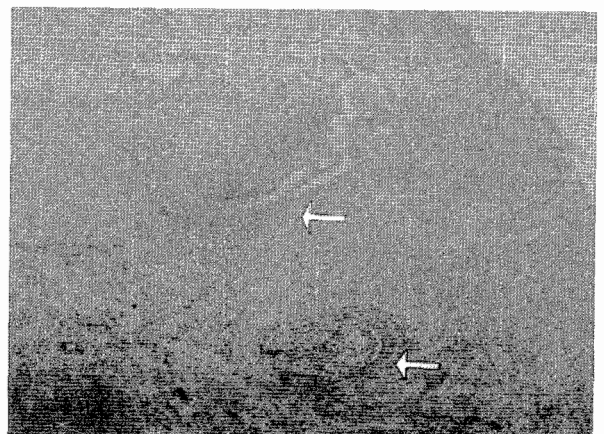


Fig. 3 A histologic section of a larva (nymph) showing some of the circumoral hooks (arrowed)

* Correspondence

complaining of a three-day history of features suggesting upper intestinal bowel obstruction.

He had a right inguinal hernia repair 15 years prior to presentation on account of an obstructed hernia. He had a past history of recurrent vague self-limiting abdominal pain for over a year. He did not eat snakes or other reptiles.

Examination revealed that he was dehydrated but wasn't pale, jaundiced nor had peripheral lymph node enlargement. His cardiopulmonary system was stable except a high pulse rate of 92bpm. He had central abdominal distension with visible peristalsis and high-pitched and frequent bowel sounds. The abdomen was mildly tender but there was no guarding. Digital rectal examination was unremarkable. Plain erect and supine abdominal X-rays confirmed mechanical small intestinal obstruction. No calcified lesions were noted on the film.

His laboratory results were essentially normal. He was initially managed conservatively with intravenous fluids, parenteral antibiotics and analgesics. A naso-gastric tube and a urethral catheter were passed. This treatment was discontinued after 24 hours and surgery performed because of progressive abdominal distension, persistent faeculent drainage through the naso-gastric tube and worsening abdominal pain.

The intra-operative findings were:

- Numerous pale nodules under the serosal surface of the jejunum and on the greater omentum each measuring 4-6mm and some contained a visible curled-up worm. The surfaces of the liver and spleen were free of these lesions.
- A few dense fibrous adhesions extending from the root of the mesentery onto the ileum, about 20cm from the ileocaecal junction, involving a circumferential fibrotic portion of the ileum that completely occluded the lumen of the intestine. This area was devoid of the nodules mentioned above.

The scarred segment of the ileum was resected after the adhesions were divided and an end-to-end anastomosis performed.

Some of the lesions were removed for histopathological diagnosis.

The patient made an uneventful post-operative recovery and was discharged on the tenth post-operative day. He is being followed-up.

The parasites were diagnosed as well-preserved encysted *Armillifer armillatus* larvae and degenerative granulomas of the larvae based on the gross morphology of the larvae (figures 1 and 2) and the identification of circumoral hooks (figure 3) on histological sections on the larvae.

Discussion

Pentastomiasis is a disease that occupies an early position chronologically among the recognized zoonotic parasitic diseases and is caused by members of the phylum *Pentastomidae*. It was first described in man by Pruner in Egypt in 1847, and a year later Wyman discovered adult *pentastomids* in the African python.^{3,10}

Visceral *Pentastomiasis* is caused by *Armillifer armillatus* while *Linguatula serrata* causes the nasopharyngeal disease.^{11,12} While man acts as an intermediate host in *Armillifer armillatus* infestation he serves as an aberrant definitive host in *Linguatula serrata* infestation.⁹ These two species, among the six species of the phylum *Pentastomidae* known to infest man, cause over 99% of the disease.¹³

The disease has been reported from every region of the world but the precise world incidence rate is not known. Postmortem reports among the Malaysian aborigines and natives of Congo have revealed incidence rates of 45.4% and 22.5% respectively in these areas.^{3,6,13,14} A retrospective review of 1000 randomly selected abdominal X-Rays diagnosed 14 cases in a center in Nigeria.¹⁵

The adult *Armillifer armillatus* inhabits the respiratory tract of the definitive host (snake) where they attach themselves by their hooks to the mucosa.^{2,11} Following fertilization embryonated eggs are discharged through the nasal secretions and the faeces and these contaminate vegetation and water.¹¹ An intermediate host, a rodent, may ingest these eggs which hatch in the intestine to release the first stage larvae. The larvae penetrate the intestine to the peritoneal cavity where they attach to the organs and moult several times into an advanced stage larvae (nymph). These encyst on the surfaces of the organs in the abdomen.^{2,9,11} The life cycle is completed when a snake eats an infested rodent. The larvae migrate from the stomach of the snake along the oesophagus to the nasopharynx where they moult once into the adult forms and attach themselves. Infestation of man, as an intermediate host, breaks the cycle since the larvae die in-situ.^{3,11}

In man, *pentastomid* infestation results from consumption of water or food contaminated with secretions from the nasal discharge of infested snakes and carnivores.^{2,11}

In communities where reptiles are eaten, consumption of raw or inadequately cooked snake, lizard meat or the flesh of another host is the cause of infestation.^{3,3,16} Our patient does not eat snakes and other reptiles or the meat of carnivores but as he is a farmer and contamination of his food or water source on the field by infestive eggs that he may have consumed could probably be the cause of the transmission of the disease.

Man tolerates *Pentastomiasis* by *Armillifer* very well and many infestations go unrecognized. However on occasion they have produced serious symptoms and twelve fatalities have been documented in the world literature.⁶ Intestinal obstruction from masses of larvae or extensive adhesions, intestinal perforation and peritonitis, as well as ocular infestation are some serious conditions reported to be caused by this disease.^{4,6}

The *Halzoun* or *Marrara* syndrome is a hypersensitivity reaction involving the respiratory tract and the skin caused by the presence of the adult parasites in the nasopharynx or the ingestion of larval proteins.^{17,18} The condition follows the consumption of *Marrara* (a traditional meal of the people of Sudan) which consists of raw liver, lungs, trachea, mesenteric lymph nodes and rumen of goats and sheep infested with larvae of *Linguatula serrata*.¹⁸ It is characterised

by oedematous congestion of the nasopharyngeal mucosa, tonsils, larynx and the trachea that develops a few minutes to about half an hour after eating the nymphs. Paroxysmal sneezing and coughing, dyspnoea, dysphagia and dysphonia are the common symptoms. On the skin a papular non-itching exanthema may develop.¹⁷

The adhesions found in our patients were localized and involved a small segment of the ileum that had an almost circumferential scarred portion. This area was also devoid of the parasites and so the larvae could not have been responsible for these adhesions. The probable cause of the adhesions could be related to the obstructed hernia that was repaired 15 years earlier. A severely ischaemic but viable intestine that is reduced into the peritoneum will excite an inflammatory reaction around it and this may lead to adhesion formation. The portion of the intestine that was caught at the neck of the hernia sac may heal by fibrosis to produce a stenotic ring (Garre's stricture).^{19,20}

The calcified encysted nymph gives a characteristic C-shaped, circular or horse-shoe-shaped opacity on the plain abdominal or chest X-rays and this aids diagnosis. Frequently the disease is diagnosed incidentally at surgery or autopsy.

Treatment is not usually necessary in asymptomatic *Armillifer armillatus* infestation. The *Halzoun* or *Marrara* syndrome, which is a hypersensitivity reaction of the nasopharynx and self limiting in most cases, is treated symptomatically.^{9,18} Appropriate surgical intervention should be undertaken when intestinal obstruction or perforation develops, and free and encysted parasite in the eye should be removed surgically.³

References

1. Markell E K, Voge M, John D T. Parasites, parasitism and Host relations. In: Baxter Venable (ed). Medical parasitology (6th edition) W. S. Saunders company. West Washington square, Philadelphia. 1986. pp 5 - 19.
2. Markell E K, Voge M, John D T. Parasites, parasitism and host relations. In: Baxter Venable (ed). Medical parasitology (6th edition). W. S. Saunders company: West Washington square, Philadelphia. 1986. pp 284 - 308.
3. Meyers W M, Neafie R C, Connor D H. Pentastomiasis. In: Binford C H and Connor D H (eds). Pathology of Tropical and extraordinary diseases. Washington D C: Armed Forces Institute of Pathology. 1976; 2: pp 546 - 550.
4. Herzog U, Marty P, Zak F. Pentastomiasis: case report of an acute abdominal emergency. *Acta Trop.* 1985; 42: 261 - 71.
5. Yapo E H, Fantom L, Adou Bryn K D, Botti K, Koffi K Malicier D. Human pentastomiasis discovered postmortem. *Forensic Sci Int.* 2003; 137: 52 - 4.
6. Ma K C, Qiu M H, Rong Y L. Pathological differentiation of suspected cases of pentastomiasis. *Trop Med and Int Health.* 2002; 4: 166 - 177.
7. Faisy C, Boye B, Blatt A, Boutes P, Iloumbou J. Porocephalosis, a little known parasitosis, literature review and a Congolese case report, *Med Trop (Mars).* 1995; 55: 258 - 62.
8. Cagnard V, Nicolas-Randegger J, Dago Akribi A, Rain B, Nozais J P, Essoh Nomel P, Ette M, Doucet J, Assale N'Dri G. Generalized and lethal pentastomiasis due to *Armillifer grandis*. *Bull Soc Pathol Exot filiales.* 1979; 72: 345 - 52.
9. Brown H W, Neva F A. Class Arachida-Ticks, Mites, Spiders, Scorpions. In: Basic clinical parasitology (5th edition). Appleton-Century-Croft/Norwalk/Connecticut. 1983; pp 287 - 302.
10. De Meneghi D. Pentastomes (Pentastomiasis, *Armillifer armillatus* Wyman, 1848) in snakes from Zambia. *Parassitologia.* 1999 Dec; 41: 573 - 4.
11. Knight R. Other Metazoan parasites. In: Parasitic disease of man. Churchill Livingstone, Medical division of Longman group Limited. 1982; pp79 - 86.
12. Morsy T A, El-Sharkawy I M, Lashin A H. Human nasopharyngeal Linguatulosis (pentastomiasis) Caused by *Linguatula serrata*. *J Egypt Soc Parasitol.* 1999; 29: 787 - 90.
13. Guardia N S, Sepp H, Scholten T, Morava-Protzner I. Pentastomiasis in Canada. *Arch Pathol Lab Med.* 1991; 115: 515 - 517.
14. Prathap K, Lau K S, Bolton J M. Pentastomiasis: A common finding at autopsy among Malaysian aborigines. *Am J Trop Med Hyg.* 1969; 16: 20 - 27.
15. Lindner R R. Retrospective X-Ray survey for porocephalosis. *J Trop Med Hyg.* 1965; 68: 155.
16. Azinge N O, Ogidi-Gbegbaje E G, Osunde J A, Oduah D. *Armillifer armillatus* in Bendel State (Midwest) Nigeria (a village study in Ayogwiri village, near Auchi, 120 kilometers from Benion City) Phase 1. *Trop. Med. Hyg.* 1978 May; 8: 76 - 9.
17. Buslau M, Kuhne U, Marsch W C. Dermatological signs of nasopharyngeal Linguatulosis (Halzoun, Marrara syndrome) the possible role of a major basic protein. *Dermatologica,* 1990; 181: 327 - 9.
18. Yagi H, el Bahari S, Mohamed H A, Ahmed el-R S, Mustafa B, Mahmoud M, saad M b, Sulaiman S M, el Hassan A M. The Marrara syndrome: a hypersensitivity reaction of the upper respiratory tract and buccopharyngeal mucosa to nymphs of *Linguatula serrata*. *Acta Trop.* 1996; 62: 127 - 34.
19. Cherney L S. Intestinal stenosis following strangulated Hernia. Review of the literature and report of a case. *Annals of Surgery.* 1958 Dec.; 148: 991 - 993.
20. Ribet M, Wurtz A, Callafe R. Stenosis of the small intestine after strangulated hernia *J. Chir (Paris).* 1976 Apr; 111: 471 - 5.