

# Multifocal osteonecrosis in HIV/AIDS: a case report

\*A.L. Akinyoola<sup>1</sup>, I.A. Adediran<sup>3</sup>, L.M. Oginni<sup>1</sup> and O. Onayemi<sup>2</sup>

\*Departments of Orthopaedic Surgery and Traumatology, Dermatology and Venereology<sup>2</sup>, Haematology and Immunology<sup>3</sup>  
College of Health Sciences, Obafemi Awolowo University,  
Ile-Ife, Nigeria.  
E-mail: aakinyoola@yahoo.co.uk.

## Summary

Many patients with Human Immunodeficiency Virus (HIV) Infection now live long due to the availability of antiretroviral drugs. This has resulted in many hitherto unknown complications being reported.

We report a 56-year-old trader who presented with a seven-month history of pain in both shoulders and hips. Laboratory investigations and x-rays confirmed osteonecrosis of both humeral heads and femoral heads in HIV/AIDS. She is presently on antiretroviral drugs and conservative management of her multiple joint disorders.

**Key-words:** *Osteonecrosis, HIV, AIDS.*

## Résumé

Un grand nombre de patients avec l'infection du virus immunodéficientaire humain (VIH) deviennent bien âgés à la suite de la disponibilité des drogues antirétrovirus. Par conséquence, on avait assisté aux complication diverses déjà rapportées. Il s'agit d'un cas d'un commerçant âgé de 56 ans atteint d'une histoire d'une douleur de la durée de sept mois dans les épaules et les hanches les deux. Des recherches laboratoire et rayon x avaient confirmé l'ostéonecrose des têtes humeruse et têtes femorales les deux en ce qui concerne VIH/SIDA. A présent, elle se drogue avec antirétrovirus un prise en charge conservatoire de ses troubles d'articulation multiple.

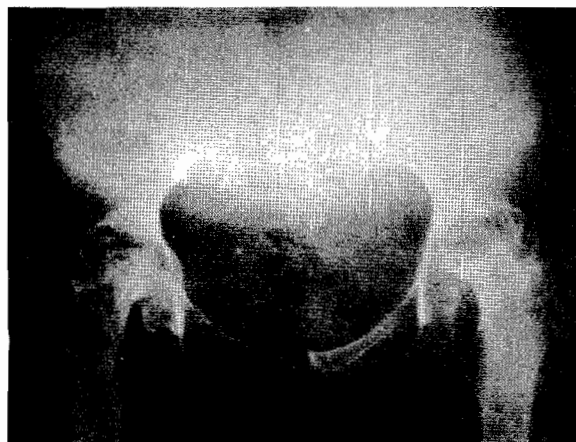## Introduction

Osteonecrosis is increasingly being reported in association with HIV/AIDS<sup>1</sup>. While some reports have suggested an association between osteonecrosis and highly active antiretroviral therapy such as the use of protease inhibitors<sup>1,2,3</sup>, others have proposed a direct link between the HIV infection and osteonecrosis<sup>4</sup>. The use of steroids for HIV-related diseases has also been implicated<sup>5</sup>. Antiphospholipid antibodies and hyperlipidaemia secondary to protease inhibitor therapy are other aetiologic possibilities<sup>6</sup>. The femoral head is most commonly involved and could be bilateral<sup>1</sup>. As more patients with HIV infection live long due to the availability of antiretroviral drugs osteonecrosis will

become an increasingly relevant problem to the orthopaedic surgeon and other physicians caring for these patients<sup>7</sup>. We report this case to encourage prospective screening of patients who complain of pain in the large joints for HIV infection.

## Case report

A 56-year-old trader presented to the Orthopaedic clinic with a seven-month-history of painful and stiff shoulders and hips, fever and weight loss. She had no cough or contact with anyone with chronic cough. There was no previous trauma to the shoulders and hips. She denied any previous use of steroids. She is not a known sickle cell disease patient. Examination showed a chronically ill elderly woman. She was pale and febrile. The peripheral lymph nodes were not significantly enlarged. The shoulder muscles were wasted bilaterally. There was tenderness in the glenohumeral joint and the range of movement was markedly reduced. Both hips were tender and there was marked limitation of all movements in the hips. X-rays of both shoulders and both hips showed necrosis and collapse of both humeral heads and femoral heads with narrowing of the joint



**Fig. 1** X-ray of the pelvis showing osteonecrosis of both femoral heads with collapse and narrowing of both hip joints.

\*Correspondence

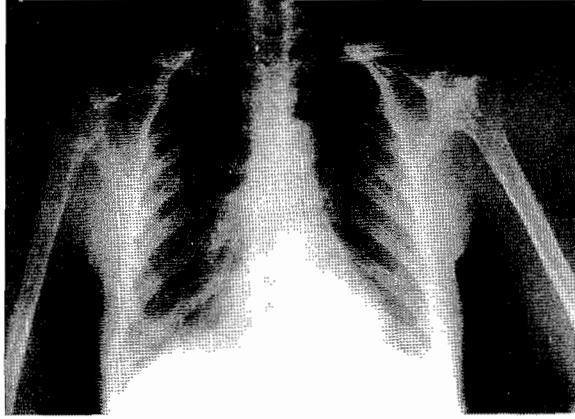


Fig. 2 X-ray showing osteonecrosis of both humeral heads  
Both lungs appear normal

spaces (Figs 1 & 2). Chest x-ray was normal (Figure 2) Packed cell volume (PCV) was 23%, wbc = 3,400/cmm (N46%, E1%, L53%); Platelets = 250,000/cmm. Erythrocyte Sedimentation Rate (ESR) was 74mm/hr (Westergren). Haemoglobin Genotype was AA. Mantoux Test was 8mm. Retroviral screening and confirmatory tests were positive.

CD4 count was 550 cells/ $\mu$ l. She was transfused with blood to correct anaemia. She was then started on antiretroviral drugs – Zidovudine 300mg bd; Lamivudine 150mg b.d, Nevirapine 200mg b.d and multivitamins. Nonsteroidal anti-inflammatory drugs and physiotherapy were administered. She is presently much better clinically and is ambulating with a pair of crutches and still on antiretroviral therapy.

### Discussion

Osteonecrosis, also known as avascular necrosis, is characterized by death of bone from vascular compromise. The incidence of osteonecrosis has increased in HIV infected patients over the last few years<sup>8</sup>. The increased incidence may be due to an increased frequency of risk factors previously associated with osteonecrosis such as hyperlipidaemia, corticosteroid use, alcohol abuse and hypercoagulability<sup>5,9</sup>. The development of osteonecrosis is also now considered a side effect of treatment of HIV/AIDS with highly active antiretroviral therapy with protease inhibitors possibly related to the induced hyperlipidaemia<sup>8</sup>.

The pathogenesis in individuals may be multifactorial. A common complaint by HIV-infected patient with osteonecrosis is arthralgia and difficulty with walking. Therefore osteonecrosis should be considered in every HIV-infected patient who complains of pain in

weight bearing joints. HIV infection should also be ruled out in patients with osteonecrosis. An important differential diagnosis of osteonecrosis in HIV/AIDS in our environment is tuberculous arthritis.

It is instructive to note that our patient developed osteonecrosis before commencing antiretroviral therapy. This tends to support a causal relationship between HIV-infection and development of osteonecrosis<sup>4,7</sup>.

The multifocal nature of our patient's osteonecrosis (both humeral heads and femoral heads) and late presentation (Figs 1 & 2) present a formidable challenge in management.

Presently she is doing well on antiretroviral therapy and nonsteroidal anti-inflammatory drugs. With increasing incidence of HIV/AIDS infection, especially in Africa, it is expected that the incidence of osteonecrosis will rise. Studies are needed to ascertain the prevalence of osteonecrosis in HIV/AIDS and the prevalence of HIV/AIDS in patients with osteonecrosis.

### References

1. Allison G.T., Bostrom MP, Glesby MJ. Osteonecrosis in HIV disease: epidemiology, etiologies and clinical management. *AIDS* 2003; 17: 1-9.
2. Bongiovanni M, Chiesa E, Riva A, d' Arminio Monforte A, Bini T. Avascular necrosis of the femoral head in HIV-1-infected patient receiving lopinavir/ritonavir. *Int. J. Antimicrob Agents.* 2003; 22: 630-1.
3. Franzen C, Salzberger B, Fatkenhever G. Avascular necrosis of both femoral heads in an HIV-infected patient receiving protease inhibitors. *Eur. J. Med Res.* 2001 Feb. 28; 6: 83-4.
4. Ries MD, Barcohana B, Davidson A, Jergesen HE, Paiement GD. Association between human immunodeficiency virus and osteonecrosis of the femoral head. *J. Arthroplasty* 2002; 17: 135-9.
5. Blacksins MF, Kloser PC, Simon J. Avascular necrosis of bone in human immunodeficiency virus infected patients. *Clin. Imaging.* 1999; 23: 314-8.
6. Brown P, Crane L. Avascular necrosis of bone in patients with human immunodeficiency virus infection: report of 6 cases and review of the literature. *Clin. Infect. Dis.* 2001; 32: 1221-6.
7. Attarian DE. Multifocal osteonecrosis and human immunodeficiency virus infection. *J. South Orthop. Assoc.* 2002; 11: 172-3.
8. Calza L, Manfredi R, Chiodo F. Osteonecrosis in HIV-infected patients and its correlation with highly active antiretroviral therapy (HAART). *Presse Med.* 2003; 32: 595-8.
9. Scribner AN, Trionfo-Cancio PV, Cox BA, Marcantonio D, Hamid F, Keis P, Levi M, Allen B, Murphy K, Jones RE, Skiest DJ. Osteonecrosis in HIV: a case-control study. *J. Acquir Immune Defic Syndr.* 2000; 25: 19-25.