

# Simultaneous post traumatic bilateral cervico-trochanteric femoral neck fractures in a child: A case report

\*Hussa M. Gilban, Tarek M. Mirdad<sup>1</sup> and Matthew Jenyo

Aseer Central Hospital, College of Medicine,  
<sup>1</sup>Professor of Surgery, College of Medicine,  
King Khalid University, Abha, Saudi Arabia,  
P. O. Box 641, Abha Saudi Arabia.  
E-mail: tarekmirdad@hotmail.com

## Summary

A case is being presented of simultaneous bilateral cervico-trochanteric fractures of the neck of the femur in a five and a half-year-old girl following a road traffic accident (RTA). It is being presented because of its rarity; literature search to date revealing no previously reported similar case. The patient was managed by open reduction and internal fixation with a period of postoperative immobilization with a hip spica.

**Key-words:** *Cervico trochanteric, Neck fractures, Femoral, Traumatic children.*

## Résumé

Il s'agit d'un cas des fractures simultanées bilatérales cervico-trochanterique du cou du fémur chez une fille âgée de 5 ans et demi à la suite d'un accident de la circulation routière (ACR). On présente ce cas parce qu'il est rare. Recherche de la littérature jusqu'ici avait indiqué aucun rapport précédent semblable. La patient a été soigné à travers la réduction ouverte et fixation interne avec une durée d'immobilisation postopératoire avec un spica de la hanche.

## Introduction

Femoral neck fractures in children are usually caused by high energy trauma and are often associated with multiple injuries with a high risk of avascular necrosis and non-union<sup>1</sup>. Seizure attacks<sup>2,3</sup>, stress<sup>4,5</sup> and electric shock<sup>6,7</sup> have also been reported as causing fractures of the femoral neck. Simultaneous post-traumatic bilateral cervico-trochanteric fractures of the neck of the femur in a child have not been previously reported in the literature. However, there were two previously reported cases in the literature of bilateral transepiphyseal separation of the femoral neck; both of these cases following seizure attacks. One in a 4 ½ months old baby girl<sup>2</sup> and the other one in an 11 year old boy<sup>3</sup>. Bilateral femoral neck stress fractures in children were also reported in an adolescent runner and an eight year old girl<sup>4,5</sup>. Electric shock was also found responsible for bilateral fractures of femoral neck<sup>6,7</sup>. In this article, the classification described by Delbit and popularized by Colonna<sup>8</sup> was used, namely Type I: Transepiphyseal; Type II: Transcervical; Type III: Cervico-trochanteric and Type IV: Intertrochanteric.

## Case report

A five and a half year old girl was involved in a road traffic accident resulting in bilateral closed and displaced cervico-trochanteric femoral neck fractures (Fig. 1). The patient also sustained a closed left tibial shaft fracture. This

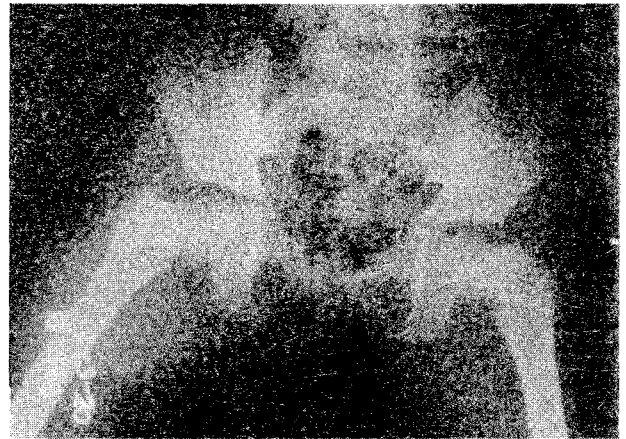


Fig. 1 X-ray of the pelvis of the five and a half year old girl with bilateral cervico-trochanteric fracture of the neck of the femur.

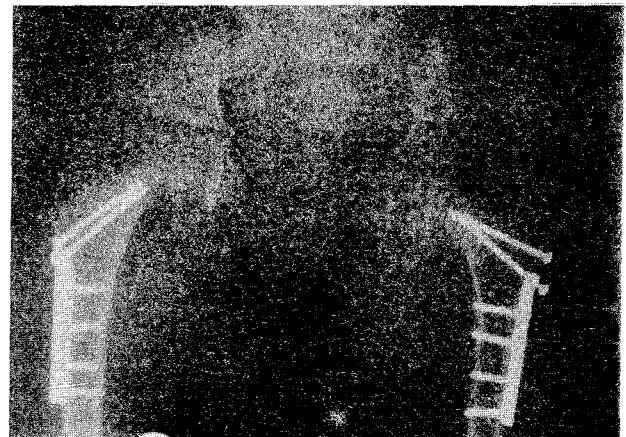

Fig. 2 X-ray of the pelvis after closed reduction and internal fixation of femoral neck fractures.

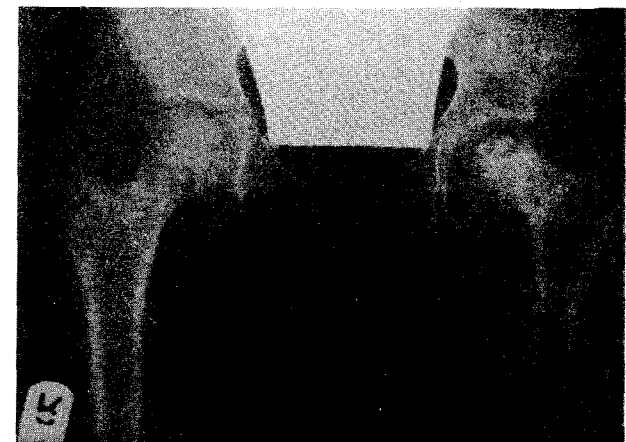

Fig. 3 X-ray of the patient one year and four months after trauma (a) immediately before implants removal, and (b) immediately after removal of implants. Avascular necrosis with varus deformity are obvious on the left side.

\* Correspondence

patient was referred to our institution from a peripheral hospital four days after the accident. Immediately, she had closed reduction and internal fixation of both femoral neck fractures. On each side a 4.0mm partially threaded cancellous screw, compressing the fracture but not crossing the growth plate of the femoral head, was used. The screw was incorporated in the proximal hole of a 3.5mm DCP side plate. Another 4.0mm cancellous screw was inserted proximal to the first screw for reinforcement and to prevent rotation at the fracture site (Fig. 2). This combination was the best set of implants available in our institution at the time. Post operatively, bilateral hip spica Plaster of Paris (POP) cast was applied. The cast was removed two months later; at that time there was good union on the right side; but delayed union was noticed on the left side. A one and a half hip spica cast was applied for two more months during which the fracture united. Then the child started to bear weight. Review after one year and 4 months showed that the left femoral head had undergone avascular necrosis (involving about 50% of the head) with varus deformity of the femoral neck. The plate and screws were removed from both the sides (Fig. 3). Clinically after removal of implants, the patient had mild limping favouring the left side.

#### Discussion

Healing of intra-capsular fractures of the femoral neck remains poor on account of poor or absent periosteum, bathing of the fracture site in synovial fluid, and precarious blood supply<sup>1</sup>. Although cervico-trochanteric fracture might be expected to behave like inter-trochanteric fracture as far as union is concerned, several cases of mal-union and non-union have been reported, one reason being absence of adequate posteromedial buttress<sup>1</sup>. This has prompted the use of a side plate to reinforce the fixation in this case.

In the case presented, possible reasons for the development of avascular necrosis and delayed union on the left side include: (i) extent of the initial insult on the left femoral neck (supported by the fact that the associated tibial fracture was also on that side), (ii) extent of displacement of the fracture and (iii) delay in fixation (the retinacular vessels could have been kinked or stretched by the displaced fragments for a long time).

From 10-15% of children with femoral neck fracture will develop complications over which the surgeon has no control<sup>1</sup>. In the series reported by Azouz et al.,<sup>9</sup> avascular necrosis accounted for 13%, premature closure of epiphyseal plate 12%, varus deformity 8.3%, and non union 3.7%. While in the long follow-up study of Morsy<sup>10</sup> avascular necrosis occurred in 40%, premature physeal closure in 38%, coxa vara in 36%, non-union in 36%, arthritic changes in 34% and shortening in 55% of patients. Better results were obtained in undisplaced and anatomically reduced fractures.

The treatment in a child of this age should incorporate a hip spica immobilization as was carried out in this case<sup>11</sup>. The difficulty of closed reduction achieving anatomical posi-

tion is well recognized<sup>12</sup> in femoral neck fractures in children and a degree of varus deformity has to be accepted as in the case reported here (Fig. 3). The delay in surgical procedure may however also contribute to the problem of development of varus deformity<sup>13</sup> as in the child presented. No differences in outcome have been observed however if the delay in operation is not longer than 6 hours<sup>13</sup>.

#### References

1. Canale, ST. In Campbell's Operative Orthopaedics. Vol. III, 9<sup>th</sup> ed. 1998: 2436-50, Mosby-Year Book Inc.
2. Kozlowski K, Braune M and Scougall JS. Multiple fractures in early infancy: report of two unusual cases. Fortschritte auf dem Gebiete der Rontgenstrahlen und der Nuklearmedizin 1980; 133: 312-6.
3. Blanco JS, Dahir G and McCrystal K. Bilateral femoral neck fractures secondary to hypocalcemic seizures in a skeletally immature patient. The American Journal of Orthopaedics 1999; 28: 187-8.
4. Bailie DS and Lamprecht DE. Bilateral femoral neck stress fractures in an adolescent male runner. A case report. American Journal of Sports Medicine 2001; 29: 811-3.
5. Scheerlinck T and De Boeck H. Bilateral stress fractures of the femoral neck complicated by unilateral displacement in a child. Journal of Pediatric Orthopedics British 1998; 7: 246-8.
6. Slater RR Jr and Peterson HD. Bilateral femoral neck fractures after electrical injury: a case report and literature review. The Journal of Burn Care and Rehabilitation 1990; 11: 240-3.
7. Shaheen MA and Sabet NA. Bilateral simultaneous fractures of the femoral neck following electrical shock. Injury 1984; 16: 13-4.
8. Delbet P. Quoted by Colonna PC. Fractures of the neck of the femur in children. American Journal of Surgery 1929; 6: 793-7.
9. Azouz EM, Karamitsos C, Reed MH, Baker L, Kozlowski K and Hoeffel JC. Types and complications of femoral neck fractures in children. Pediatric Radiology 1993; 23: 415-20.
10. Morsy HA. Complications of fracture of the neck of the femur in children. A long-term follow-up study. Injury 2001; 32: 45-51.
11. Mirdad T. Fractures of the neck of femur in children: an experience at the Aseer Central Hospital, Abha, Saudi Arabia. Injury. 2002; 33: 823 - 7.
12. Leung PC and Lam SF. Long-term follow-up of children with femoral neck fractures. J Bone Joint Surg Br. 1986; 68: 537-40.
13. Mayr J, Hirner V, Styhler W, Posch E, Jelen M, Linhart WE, Kohlmaier W, Neubauer T and Schwarz N. Femoral neck fractures in childhood. Unfallchirurg. 1998; 101: 426-32.

# Bowen's disease: Report of a case in a Nigerian man

\* Husain Yahya and Abdullahi Mohammed

*\*Dermatology Unit, Department of Medicine, Barau Dikko Specialist Hospital,  
P. O. Box 9727, Kaduna, Nigeria.*

*Department of Pathology, Ahmadu Bello University Teaching Hospital, Zaria, Nigeria.  
E-mail: husainyahya@hotmail.com*

## Summary

Bowen's disease (cutaneous squamous cell carcinoma in situ), like other cancers of the skin, is rare in black people – to our knowledge, only about 43 cases have been published in the medical literature. We report a 59-year old Nigerian man who presented with a five-year history of a mildly pruritic, slowly enlarging well-circumscribed plaque on the lower part of the anterior region of the chest on the right side. The lesion had an irregular crusted periphery and an atrophic hypopigmented centre. Histological examination confirmed a diagnosis of Bowen's disease. No predisposing factor was found to be relevant in this case – although he might have had brief occupational exposure to arsenic, it is unlikely that this was the cause of his disease. The published literature on Bowen's disease in blacks is briefly reviewed.

**Key-words:** *Bowen's disease, Skin cancer blacks, Cutaneous malignancy, Arsenical cancers.*

## Résumé

La maladie de Bowen (carcinome cellulaire cutané squameux in situ), comme d'autres cancers de la peau, est rare parmi les noirs - à notre connaissance, seul environ 43 cas ont été publiés dans la presse médicale. On signale le cas d'un vieux nigérian, de 59 ans, qui au bout cinq ans présente un problème de léger prurit, s'agrandissant lentement - la plaque circonscrite sur la partie inférieure de la région antérieure de la poitrine sur le côté droit. La lésion avait une périphérie irrégulièrement encroûtée et le centre atrophique hypo pigmenté. L'examen histologique a confirmé un diagnostic de la maladie de Bowen. Aucun facteur prédisposant n'a été trouvé pour être pertinent dans ce cas - bien qu'il ait pu avoir une brève exposition professionnelle à l'arsenic, il est peu probable que cela soit la cause de sa maladie. La documentation publiée sur la maladie de Bowen parmi les noirs est brièvement revue et corrigée.

## Introduction

Bowen's disease (cutaneous squamous carcinoma in situ) is rare in black people – only about 43 cases have been reported in the medical literature. We report a case in a Nigerian man and briefly review the literature on the subject.

## Case report

A 59-year old man presented to the dermatology clinic with a 5-year history of an occasionally mildly itchy, slowly enlarging lesion on the lower part of the anterior region of the chest on the right. He had worked as a forestry worker for 34 years until his retirement 6 years before presentation. During the first five years of his work, sodium arsenite had been used to poison some tree species but he denied using it

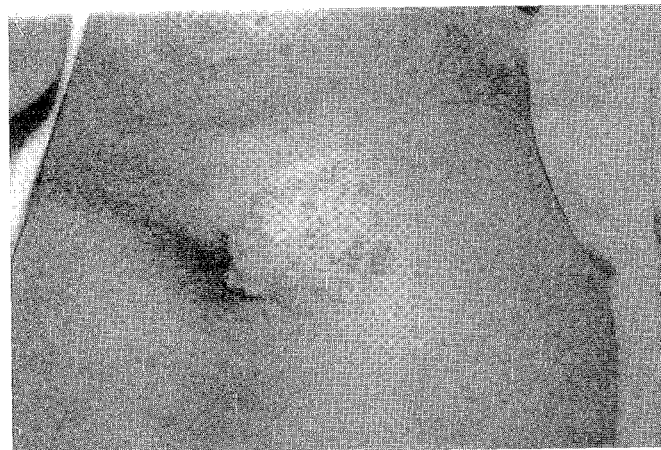

Fig. 1 Photograph shows a well-circumscribed crusted plaque of Bowen's disease on the lower part of the chest.

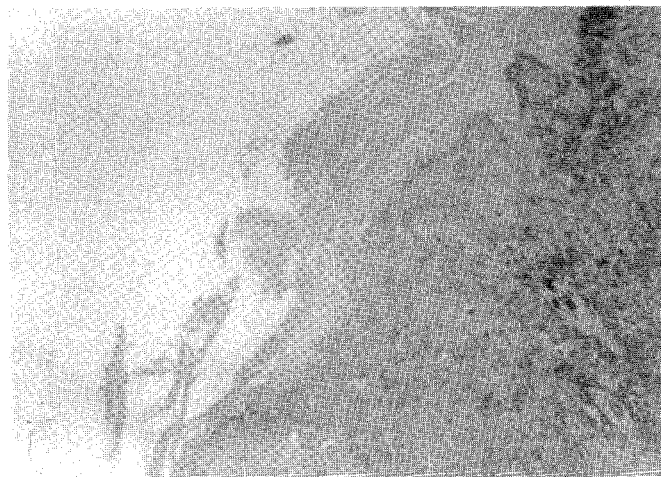


Fig. 2 Histologic section of Bowen's disease. Note marked full thickness epidermal dysplasia characterized by nuclear pleomorphism, and loss of polarity of the keratinocytes. The dermo-epidermal junction is intact (H & E x 100).

himself or coming in contact with it in any way. He also denied taking any medications containing arsenic. He had lived in many communities where well water was the only source of water. There was no history of long-term application of heat to the chest. He had well-controlled essential hypertension and type two diabetes mellitus and enjoyed good general health.

On examination, he had a well-circumscribed 4 cm by 5 cm plaque on the right side of the lower part of the anterior aspect of the chest (figure 1). The plaque had an irregular outline with a crusted periphery and a hypopigmented centre. The rest of the examination was normal. There were no other skin manifestations suggestive of chronic arsenic ingestion. Histological examination (figure 2) of a punch biopsy showed parakeratosis, acanthosis and broadening of the rete pegs. There was marked full thickness pleomorphism of

\*Correspondence

keratinocytes and hyperchromasia of nuclei with loss of polarity of cells. The dermis showed infiltrates of chronic inflammatory cells. The dermo-epidermal junction was intact. The lesion was subsequently excised with primary closure of the skin.

### Comment

Bowen's disease is a form of intra-epidermal (in situ) squamous cell carcinoma and, like other pre-malignant skin conditions, is rare in black people. The largest series (21 lesions in 19 patients) was reported by Mora, Perniciaro and Lee in their retrospective study of skin cancer in black patients in New Orleans, United States, between 1948 and 1982.<sup>1</sup> Rosen and his colleagues reported 7 cases from Texas,<sup>2</sup> and Graham and Helwig reported that out of 155 cases of Bowen's disease, only 4 were black.<sup>3</sup> The rest of the cases were isolated single reports. We were able to find only six single reports of Bowen's disease from Black Africans.<sup>4-9</sup> Our patient was treated for many years with topical and systemic antifungal agents and antibiotics without any improvement. Prompt referral to a dermatologist would have allowed differentiation of this condition from common skin problems seen in the tropics such as fungal and bacterial skin infections but would also have facilitated exclusion of chronic plaque psoriasis, discoid lupus erythematosus, and tuberculosis verrucosa cutis, conditions that might resemble Bowen's disease clinically.

Majority of the cases of Bowen's disease occurred in the seventh and eight decades although younger patients were also seen. Women were affected slightly more than men. Most cases of Bowen's disease in blacks occurred in non-sun exposed skin as in our patient. This contrasts with the disease in whites where lesions are found in sun-exposed parts of the body (head, neck, arms, leg in women). A lesion on the palm has been reported<sup>5</sup>. Lesions were usually solitary although multiple lesions occurred in a few patients. The morphology of Bowen's disease was similar to those in other races although a fungating tumour of the anterior abdominal wall with histological feature of the disease was reported by Leibowitz et al. in a South African man.<sup>7</sup> This case was unusual, however, in also having features of basal cell carcinoma with sebaceous differentiation. There was also strong evidence of arsenic intoxication in this patient.

Chronic arsenic ingestion is a well known predisposing factor for Bowen's disease.<sup>11</sup> Although our patient may have had brief occupational arsenic exposure, there is no strong evidence that this was the cause of his disease: He had a single lesion (arsenical cancers are multiple),<sup>11</sup> and did not have other cutaneous features of arsenic intoxication such as diffuse generalized pigmentation or rain drop pigmentation or palmo-plantar keratoses, features that were found in up to 90% of patients with chronic exposure.<sup>11</sup> Moreover, arsenic ingestion was thought responsible for Bowen's disease in blacks in only five of the cases reported. Three patients had epidermodysplasia verruciformis,<sup>4,6,8</sup> a rare, life-long generalized infection with human papilloma viruses characterized by the development of cutaneous carcinomas, often at an early age. Chronic application of heat, irritated seborrhoeic keratosis and lymphopathic strictures were

thought responsible in three patients.<sup>1</sup> Most patients had no obvious predisposing factor.

The association of Bowen's disease and internal malignancy is disputed. Five of 19 of Mora's patients had an internal malignancy (diagnosis of Bowen's was made first in three patients) which included polycythemia vera and leukaemia, mycosis fungoides, and carcinomas of the large intestine, cervix and prostate.<sup>1</sup> Of the seven patients reported by Rosen, one developed adenocarcinoma of prostate at follow-up.<sup>2</sup> A meta-analysis of 12 studies has, however, found no significant association between Bowen's disease in general and internal malignancy.<sup>13</sup>

Treatment of Bowen's disease was principally by total excision and primary closure. Other modalities of treatment used included curettage and desiccation, cryotherapy and 5-Fluorouracil. Invasive disease and metastasis occurred in only a few patients.<sup>1</sup>

### References

1. Feldman RE, Schiff ER. Hepatitis in dental professionals. *J Am Med Assoc* 1975; 232: 1228 - 30.
1. Mora RG, Perniciaro C and Lee B. Cancer of the skin in blacks. III. A review of nineteen black patients with Bowen's disease. *J. Am. Acad. Dermatol.* 1984; 11: 557 - 562.
2. Rosen T, Tucker SB and Tschen J. Bowen's disease in blacks. *J. Am. Acad. Dermatol.* 1982; 7: 364 - 368.
3. Graham J H and Helwig E B. Bowen's disease and its relationship to systemic cancer. *Arch. Dermatol.* 1961; 83: 76 - 96.
4. Bloc G, Faye I and Basset Y et al; Epidermodysplasie verruciforme de Lewandowski-Lutz chez des Noirs Africains. *Bull. Soc. Med. Afr. Noire Lang. Fr.* 1971; 16: 538 - 590.
5. Dogliotti M. Survey of skin disorders in the urban Black population of South Africa. *Br. J. Dermatol.* 1975; 92: 259 - 270.
6. Jacyk WK. Bowen's disease of the palm. Report of a case in an African. *Dermatologica* 1980; 161: 285 - 287
7. Leibowitz M R, Rippey J J and Thompson F. Fungating Bowen's disease with presumed arsenic intoxication. *S. Afr. Med. J.* 1982; 62: 737 - 739.
8. Lutzner M A, Blanchet-Bardon C and Orth G. Clinical observations, virologic studies, and treatment trials in patients with epidermodysplasia verruciformis, a disease induced by specific human papilloma viruses. *J. Invest. Dermatol.* 1984; 83: 180 - 250.
9. Jacyk WK and de Villiers EM. Epidermodysplasia verruciformis in Africans. *Int. J. Dermatol.* 1983; 32: 806 - 810.
10. Yeh S, How S W and Lin C S. Arsenical cancer of skin. Histologic study with special reference to Bowen's disease. *Cancer* 1968; 21: 312 - 359.
11. Lycka B A S. Bowen's disease and internal malignancy. A meta-analysis. *Int. J. Dermatol.* 1989; 28: 531 - 533.