

Generalised Burkitt's lymphoma involving both breasts - A case report

S. O. Fadiora, **V. O. Mabayoje, *A. O. A. Aderoumu, *M. L. Adeoti,
*S. A. Olatoke and *A. S. Oguntola

*Department of Surgery, **Department of Haematology
LAUTECH College of Health Sciences, P. M. B. 4400, Osogbo.
E-mail: sofadiora@yahoo.com

Summary

Background: Burkitt's lymphoma is a disease of children age ranging 8-10 years. Lymphoma involving the breast is an unusual clinical entity, which is rarely distinguished preoperatively from other more common forms of breast cancer. The Management differs from the more typical adenocarcinoma of the breast in that the emphasis is on systemic therapy.

Case: We report a 27-year-old pregnant Nigerian civil servant at 28 weeks gestation, who presented with multiple organ swellings including both breasts. She was diagnosed histologically as primary breast Burkitt's lymphoma. She was treated with systemic chemotherapy after spontaneous abortion. She had a recurrence of the lesion in the right breast a month later that was excised. Presently there is no evidence of any mass.

Conclusion: Compared with breast carcinoma, primary breast lymphoma is a rare disease but should be considered in the differential diagnosis of breast masses.

Key-words: Generalised Burkitt's lymphoma, Breast, Pregnancy.

Résumé

Introduction: Lymphome de Burkitt est une maladie chez des enfants avec la tranche d'âge de 8 - 10ans. Lymphome impliquant le sein est une entité clinique peu commun, ce qui est rarement reconnaissable préopérativement par rapport au plus adénocarcinome typique du sein dans la mesure où l'accent est mis sur la thérapie systémique.

Cas: Nous rapportons le cas d'une fonctionnaire nigériane enceinte âgée de 27 ans pendant une période de 28^{ième} semaine de gestation qui s'est présentée atteinte de la tuméfaction multiple d'organe y compris les deux seins. On l'avait été diagnostiqué histologiquement comme lymphome de Burkitt de sein primaire. On l'avait traité avec la chimiothérapie systémique après un avortement volontaire. Elle avait eu une récurrence de la lésion dans le sein du côté droit un mois après une intervention chirurgicale. A présent, il n'y a aucun signe de n'importe quel gonflement.

Conclusion: Par rapport au carcinome du sein, lymphome du sein primaire est une maladie rare mais devrait être considéré dans le diagnostic différentiel des masses du sein.

Introduction

Lymphoma involving the breast, either as a primary site or as a site of recurrence from lymphoma previously diagnosed elsewhere is rare¹ Primary breast lymphoma is seldom distinguished preoperatively from other more common forms of breast cancer.² It constitutes 0.04% to 0.5 % of malignant breast neoplasm; 1.7% of all extranodal Non-Hodgkins lymphomas, and 0.7% of all Non-hodgkin Lymphomas; in

one of the several series³.

Breast lymphoma usually manifests as painless masses incidentally detected by self examination or during routine mammography¹. The majority of the cases are unilateral and of B-lymphocyte histologic lineage.; while bilateral involvement is seen almost exclusively in secondary cases and in Burkitt's lymphoma.¹⁻³ Prognosis depends on the histological type and stage at diagnosis.^{4,5} Multiorgan involvement is commonly seen and secondary cases with mucosal associated lymphoid-tissue (MALT) type lymphoma appear to have a better prognosis^{1,3,6}.

The purpose of this paper is to consider Burkitt's lymphoma as a differential diagnosis of breast mass though very rare and to high-light its peculiar presentation.

Case report

A 27-year-old Nigerian Civil Servant presented with 2 months history of painless multiple body swellings involving both breasts, lower abdomen and the back, with associated weight loss, early satiety and vomiting of recently eaten food.

Examination revealed a young lady pale, with evidence of weight loss. There was a left breast mass of 44cm by 32cm while the right side was 46cm by 30cm. (see fig. 1)

Abdominal examination revealed right iliac fossa mass of 8cm by 5cm size, and left lumbar mass of 15cm by 17cm, fundal height was at 28 weeks gestation. The last menstrual period (L.M.P.) was 12/11/2002; the expected date of delivery (EDD) was 19/8/2003; with viable fetus. An abdominal ultrasound (USS) confirmed the pregnancy and the gestational age in addition to the multiple abdominal masses, a diagnosis of malignant lymphoma in pregnancy was made.

The patient had incision biopsy on the left breast mass, and an aspiration biopsy on both breasts, incisional biopsy of the right breast confirmed the diagnosis (see fig.2). She had a bone-marrow aspiration which was negative for

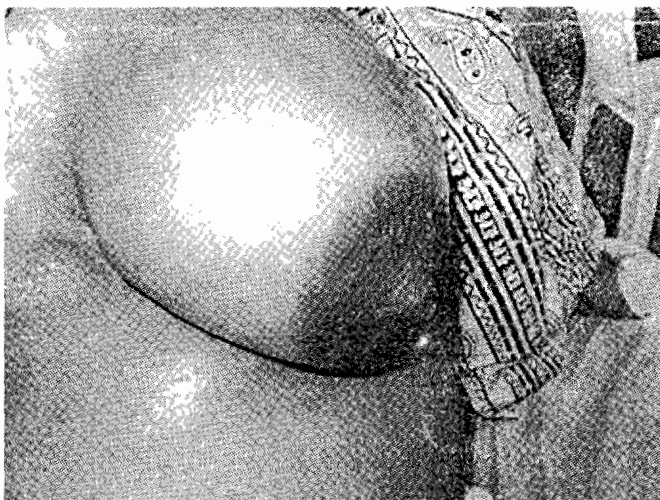


Fig. 1a Left breast mass; that measures 44cm by 32cm.

¹Correspondence

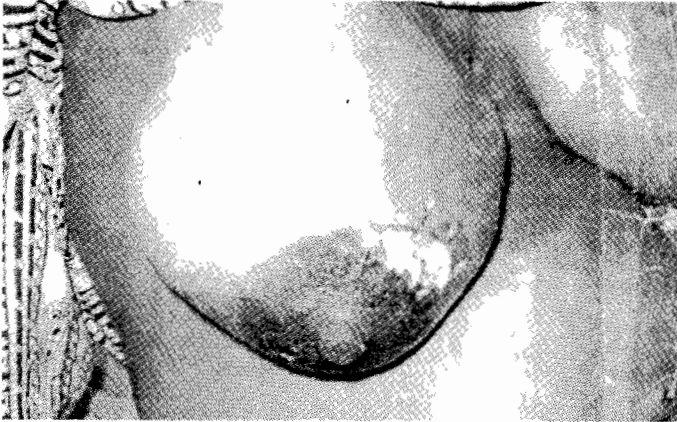


Fig. 1b Right breast mass with the site of the incisional biopsy

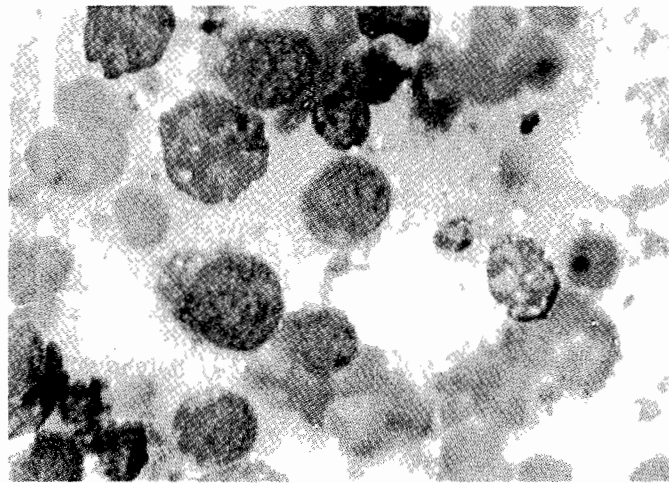


Fig. 2 Histopathological presentation of the breast biopsy that shows Burkitt's cell.

Burkitt's cells.

Laboratory values were Packed Cell volume (PCV) 22%; total white blood cell count of $8.7 \times 10^9/L$; a differential count of Neutrophils 86%, eosinophils 2% and lymphocytes 12%. The ESR was 81mm in the first hour and the alkaline phosphatase was raised at 210 I.U./L. Other biochemical findings were essentially normal but for elevated urea of 7.6 mm/L.

A definitive diagnosis of Burkitt's Lymphoma (stage D due to breast involvement) in pregnancy was made she was scheduled to commence chemotherapy with I.V. Vincristine, she however had a spontaneous abortion before the commencement hence, she was placed on full regimen for Burkitt's lymphoma as follows: -

I.V.	Cyclophosphamide	1gm/m ²	day 1
I.V.	Methotrexate	37.5mg/m ²	day 1
I.V.	Vincristine	1.5mg/m ²	day 1

The intravenous drugs were given on day one of a fourteen-day cycle.

Oral prednisolone 20mg 8hrly for 5 days with Mist. Magnesium trisilicate 15mls 8 hrly also for five days; Allopurinol 100mg orally 8 hrly daily for Fourteen days within a cycle was also given.

She received seven cycles of chemotherapy including

(intrathecal central nervous system (CNS) prophylaxis to prevent CNS involvement) with complete regression of all the swellings; A month later she presented with right breast recurrence that was excised. Presently she has no breast mass.

She is currently attending both surgical and haematology clinics for routine follow up. Haemogram pattern of the last follow up visit revealed packed cell volume (PCV) of 29%; total white cell count of $7.6 \times 10^9/L$; platelet count of $120 \times 10^9/L$. with a white cell differential of Neutrophils 46%, Eosinophils of 14% lymphocytes of 40%, and ESR of 15mm in the first hour. She is presently being screened for possible parasitic infestation though bone marrow eosinophilia is not an unusual finding in malignant lymphoma. The patient tested negative for HIV/AIDS.

Discussion

Burkitt's lymphoma in this part of the world is usually seen in children, age ranging between 8-10 years⁷, however the case being reported is a 27-year-old pregnant woman. Well known predisposing factors to the development of the disease include residing in malaria endemic areas⁸, and the rain fall pattern with high humidity associated with equatorial forest zones⁹ all of which are present in the south west area of Nigeria where the patient resides. Infection with Epstein Barr virus is also a known risk factor¹⁰, but it is as of now not possible for us to prove that this patient is harbouring the virus.

Non-Hodgkins Lymphoma of the breast is uncommon with variable incidence of primary and secondary cases.^{1,2} The largest individual series with clinical follow up has been reported by Giardini et al¹¹. In this series thirty-five patients presenting with stage I or II Primary Breast Lymphoma were identified over a 30-year period, with the most common histology as diffuse large cell lymphoma (17 patients) and only 7 patients having low grade malignancy.

A variety of single and combined modality of treatment were used, with a mean follow up of 45 months, seventeen patients had died of their disease, an overall 5-year survival of 43%.

A preponderance of right-sided lesions has been reported while bilateral involvement, indicates secondary involvement^{1,3,12} Diffuse large cell lymphoma of B-lymphocyte lineage has been the most frequent histologic subtype in both primary and secondary cases^{1,12}.

Our patient has multiple painless organ involvement including the breast which was painless at the initial presentation, however in one case of primary T-cell lymphoma of the breast reported by Cohen and Brooks¹, the patient had breast pain and skin breakdown. Breast swelling as a presenting feature of lymphoma has been reported,¹³⁻¹⁵ but breast pain was not mentioned as a predominant feature in these cases. Inalsingh¹⁶ reported a case initially diagnosed as mastitis, but eventually the patient had a biopsy to rule out malignancy, and a histopathologic diagnosis of primary lymphoma of the breast was made. Rarely bilateral inflammatory Carcinoma of the breast may present with florid features of inflammation; Burkitt's lymphoma involving the breast, especially in lactating women can also manifest as a rapidly enlarging mass with features of inflammation.¹⁷

Mammography is indicated in clinically suggestive cases, however, mammography is not reliable for diagnosing breast lymphoma¹⁶.

Needle aspiration or excisional biopsy is necessary to establish a diagnosis¹⁸.

It is necessary to take samples from both breasts because primary breast lymphoma and contralateral breast cancer had been reported.¹⁹

Treatment options include combination chemotherapy such as cyclophosphamide, doxorubicin, vincristine, and prednisone.^{20,21}; radiation²², and surgical resection.²³

References

1. Cohen B A, Brooks JJ. Lymphoma of the breast, a clinicopathologic and immuno-histochemical study of Primary and secondary cases. *Cancer* 1991; 67: 1359 – 1369.
2. Gholam D, Bibeau F, EL-Weshi A, Bosq J Ribra. Primary breast Lymphoma. *Leuk. Lymphoma* 2003, July; 44: 1173-8.
3. Mattia AR Ferry JA, Harris NL. Breast Lymphoma a B-cell spectrum including the low grade B-cell lymphoma of mucosa associated lymphoid tissue. *Am J. Surg. Pathol* 1993; 17: 574-587.
4. Au wy, Chan AC, Chow LW, Liang R. Lymphoma of the breast in Hong Kong Chinese. *Haem. Oncol.* 1997; 15: 33-8.
5. Ha C S, Dubey P, Goyal L K, Hess M, Cox J D. Localised Primary non-Hodgkin's lymphoma of the breast. *Amer J. clin. Oncol.* 1998; 21: 376-80.
6. Lamovec J, Jancar J. Primary malignant lymphoma of the breast. Lymphoma of the mucosa associated lymphoid tissue. *Cancer* 1987;60: 3033-3041.
7. Okolo SN, Nwana EJ, Mohammed AZ. Histopathologic diagnosis of lymphadenopathy in children in Jos, Nigeria. *Niger ostgrad Med J.* 2003 sep 10: 165-7.
8. Biggar RJ, Nkrumah FK. Burkitt's lymphoma in Ghana: urban-rural distribution, time-space clustering and seasonality. *Int J Cancer.* 1979 mar 15 ; 23: 330-6.
9. Louiere R, Ette M, Valisco J, et al. Burkitt's disease in the Ivory Coast: anatomo-clinical and epidemiologic considerations. *Ann. Anat. Pathol (Paris)* 1975 Nov-Dec ; 20: 437-52.
10. Goldman JM. The Lymphomas, postgraduate Haematology, Third Edition. Chapter 10 pp502-529.
11. Giardini R, Piccols C, Rilke F. Primary non-Hodgkin's lymphoma of the female breast. *Cancer* 1992, 69; 725-35.
12. Arber D A, Simpson JF, Weiss LM, et al. Non-Hodgkins lymphoma involving the breast. *Am J. Surg, Pathol.* 1994; 18: 288-295.
13. Bristein S, kimmel M, Lieberman PH, et al. Malignant lymphoma of the breast a study of 53 patients. *Ann Surg* 1987; 205; 144 – 150.
14. Jeon HJ, Akagi T, Hoshida Y. Primary non- Hodgkins malignant lymphoma of the breast an Immuno histochemical study of seven patients and Literature review of 152 patients with breast lymphoma in Japan. *Cancer* 1992; 70; 2451-2459.
15. Kan JWH, Arnstein NB, Chen DCP, et al. Non-Hodgkin lymphoma of the breast, unusual presentation; detection by 67 Ga Scritigraphy. *J. Nucl Med.* 1988; 14: 214-216.
16. Inalsingh CHA. Primary non-Hodgkin's lymphoma of the breast. Case report. *J. fla. Med Assoc.* 1977; 64; 481-483.
17. Aghadiuno PU, Akang EEU, Ihekwaba FN et al. simultaneous bilateral malignant breast neoplasms in Nigerian women. *J, Natl Med Assoc.* 1994; 86; 365-368.
18. Musra A, kapur BML, Rath G K. Primary breast lymphoma. *J. Surg, Oncol.* 1991; 47: 265-270.
19. Frei KA, Bonel HM, Former P, Allemar J, Steiner RA. Primary breast lymphoma, contralateral breast cancer, and bilateral Brenner tumours of the Ovary. *Obstet Gyrecol* 2002; 100; 1079-82.
20. Linker CA, Leritt LJ, Donnel M, et al. Treatment of Adult acute lymphoblastic Leukaemia with intensive cyclical chemotherapy; on follow up report. *Blood* 1991; 78;2814 – 2822.
21. Coleman CN, Picozzi VJ Jr, cox RS, et al. Treatment of lymphoblastic lymphoma in Adults. *J. Clin. Oncol.* 1986; 4:1628 – 1637.
22. Smith MR, Brinsein S, Strans DJ. Localized non-Hodgkin's lymphoma of the breast. *Cancer* 1987; 59:351-354.
23. DaO AH, Adkins R B, Glick AD. Malignant lymphoma of the breast: a review of 13 cases. *Am surg.* 1992; 58: 792-796.