

Rigid bronchoscopic dilatation of postintubation tracheal stenosis

Abdullateef Softah

Department of Surgery, College of Medicine and Medical Sciences
King Khalid University, Abha and King Fahad General Hospital Jeddah, Saudi Arabia

E-mail: softah@hotmail.com

Summary

Background: Postintubation tracheal stenosis (PITS) occurs due to excessive pressure on the trachea by the cuff of the endotracheal tube which leads to local ischaemic necrosis of the tracheal cartilage and excessive growth of granulation tissue. The recognition of its aetiology and modifications in the design and management of endotracheal tubes have led to a diminished incidence of PITS. The management modalities that have been employed for the management of PITS include stenting, surgical resection and reconstruction, percutaneous dilatation, rigid bronchoscopic dilatation, fiberoptic assisted balloon dilatation and Nd:YAG (neodymium: yttrium-aluminum garnet) laser therapy with or without stenting.

Methods: Three female patients with a history of varying periods of endotracheal intubation after a period of acute respiratory failure who developed symptoms of tracheal stenosis 1-2 weeks post-extubation are presented. The mean age was 24 ± 12.49 years (range = 14 -38 years).

Results: All the three patients were successfully managed by frequent, rigid bronchoscopy and gradual dilatation until the resolution of the tracheal stenosis and the return of pulmonary function tests (PFT) to normal.

Conclusions: Rigid bronchoscopic dilation in patients with PITS provides safe, effective tracheal dilatation and improved pulmonary function in the medium term.

Key -words: Tracheal intubation, Postintubation tracheal stenosis, tracheal dilatation, rigid bronchoscopy.

Résumé

Introduction: Sténose de la trachée postintubation (PITS) arrive à cause de la pression excessive sur la trachée par le revers de la paroi endotrachéale aboutissant à la nécrose ishémique du cartilage de la trachée et une croissance excessive du tissu de la granulation. L'identification de son étiologie et de modifications apportées au dessin et à la prise en charge des parois endotrachéales a abouti à l'incidence diminuée de PITS. Les modalités de la prise en charge qu'on avait utilisé pour la prise en charge de PITS sont les suivantes; stenting, résection chirurgicale et la chirurgie réparatrice, dilatation percutanée, dilatation bronchoscopique rigide, dilatation de la technologie des fibres optiques de la bulle et Nd:YAG (neodymium yttrium - aluminium garnet) la thérapie laser avec ou sans le stenting.

Méthodes: Trois malade du sexe féminin avec une histoire des périodes diverses d'intubation endotrachéale après une durée d'insuffisance respiratoire aiguë qui avaient manifesté des symptômes de sténose de la trachée de 1 - 2 semaines post-extubation se sont présentées. L'âge moyen était $24 \pm 12,49$ ans (tranche = 14 - 38ans).

Résultats: Toutes les trois malades ont été traitées avec succès

à travers la bronchoscopie rigide et dilatation graduelle, fréquente jusqu' à la résolution de la sténose trachéale et le retour du pulmonary function test (PFT) jusqu' à la moyenne.

Conclusion: La dilatation bronchoscopique rigide chez des malades atteints de PITS est sans danger, et elle donne une dilatation trachéale efficace, et une fonction améliorée pulmonaire à terme moyen.

Introduction

Postintubation tracheal stenosis (PITS) occurs due to excessive pressure on the trachea by the cuff of the endotracheal tube which leads to local ischaemic necrosis of the tracheal cartilage and excessive growth of granulation tissue¹⁻⁴. The recognition of its aetiology and modifications in the design and management of endotracheal tubes have led to a diminished incidence of PITS¹. The management modalities that have been employed for the management of PITS include endoluminal stenting⁵, surgical resection and reconstruction^{1,6,7,9}, percutaneous dilatation; rigid bronchoscopic dilatation³, fiberoptic bronchoscopic balloon dilatation⁸, dilatation with an intra-aortic balloon pump¹⁰ and Nd:YAG (neodymium: yttrium-aluminum garnet) laser therapy with or without stenting^{3,2}.

Materials and methods

Three patients referred to the Cardiothoracic Unit of the King Fahad General Hospital, Jeddah, form the basis of this report (Table 1). All the patients were females. The ages of the patients were 14, 20 and 38 years respectively (mean age = 24 ± 12.49 years). Each of the three cases developed tracheal stenosis following varying periods of endotracheal intubations. The mean duration of intubation was 17.33 ± 13.43 days (range = 2-27 days).

The indications for endotracheal intubation included respiratory failure due to Guillain-Barré syndrome in case 1, scorpion bite and anaphylactic shock in case #2 and Systemic Lupus Erythematous (SLE), severe pneumonia and respiratory failure in case #3.

Investigations carried out in each case included base line Chest X-Ray, CT Scan of the neck and chest, pulmonary function tests (PFT) pre- and post-dilatation, which consisted of the measurements of Vital capacity (VC), Forced vital capacity (FVC), Forced expiratory volume in one second (FEV₁) and FEV₁/VC%.

The stenosed trachea was then dilated under general anaesthesia using various sizes of rigid bronchoscopes. Dilatations were carried out monthly until follow-up PFT and tracheal size adjudged from repeat CT Scans of the neck and chest had returned to normal and the patients became asymptomatic. Case no 3 did not give consent for post-dilatation CT scan but was asymptomatic.

Results

The clinical data on the three patients are shown in Table 1. The durations of monthly dilatations were 7, 8 and 12 months in the three patients respectively (mean = 9 ± 2.65 months). The mean percentage changes in VC, FVC, FEV₁ and FEV₁/VC% in the three patients were $59.22 \pm 56.57\%$

(range= -5.65-98.3%), $41.36 \pm 34.71\%$ (range= 8.16-77.42%), $323.50 \pm 191.60\%$ (range= 147.0-527.27%) and $174.84 \pm 53.80\%$ (range= 143.13-236.96%) respectively (Table 2).

Tracheal size as demonstrated by CT scans of the neck and chest (Figs.1-3) returned to normal in all the patients and all were asymptomatic following the last dilatations at 8, 7, and

Table 1 Clinical data on three patients with post-endotracheal intubation tracheal stenosis

Case Number	Age (Years)	Sex	Clinical diagnosis	Duration of endotracheal intubation	Level of tracheal stenosis	Frequency of tracheal dilatations	Duration of tracheal Dilatations	Outcome
1	38	F	Respiratory failure due to Guillain-Barre syndrome	27	2.5cm above the carina	Monthly	8	Normal tracheal diameter, Normal PFT
2	14	F	Scorpion sting/ Anaphylactic shock	2	2.5cm above the carina	Monthly	7	Normal tracheal diameter, Normal PFT
3	20	F	SLE, Renal failure, severe pneumonia, respiratory failure	23	4.0 cm above the carina	Monthly	12	Normal tracheael diameter; Normal PFT.

PFT: Pulmonary function tests;

SLE: Systemic lupus erythomatosus

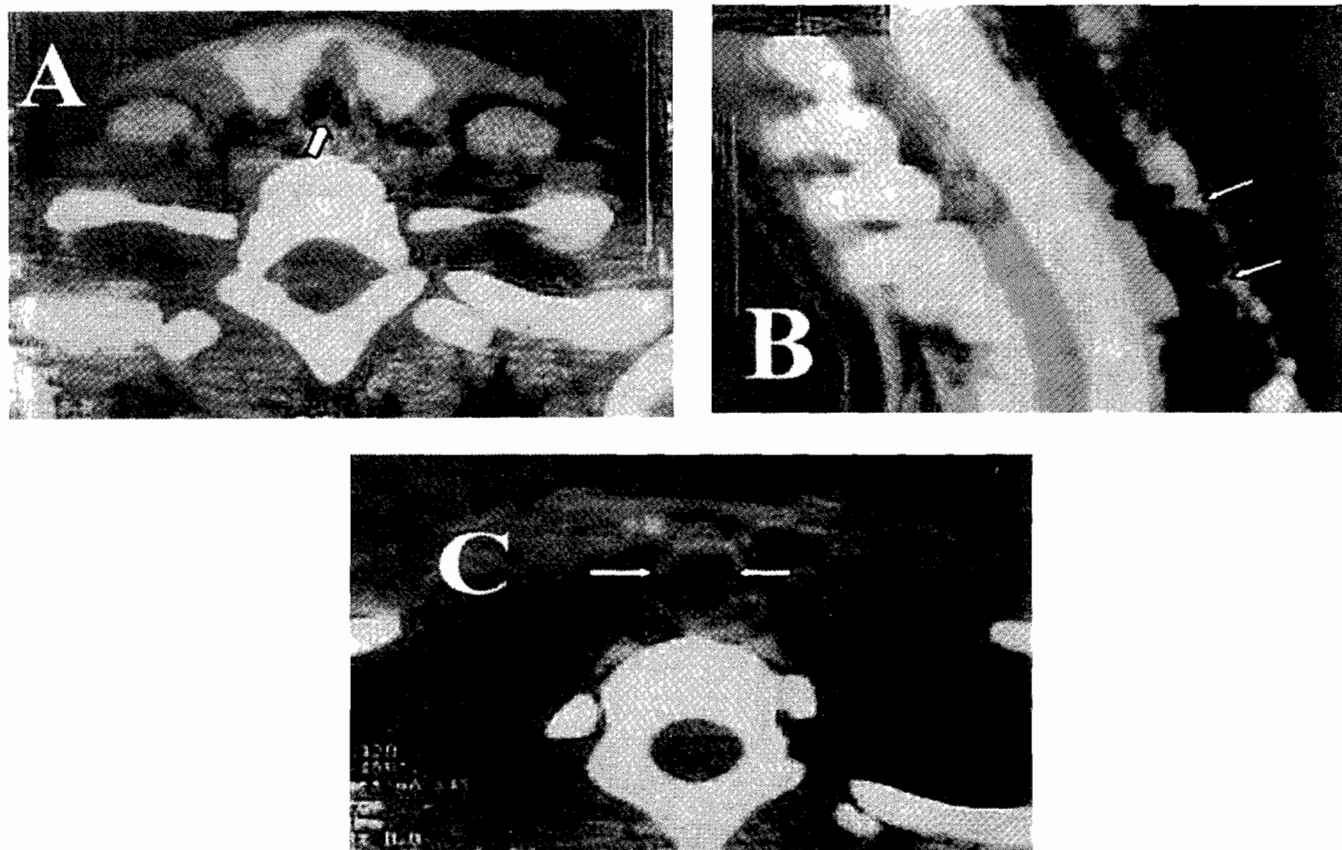


Fig. 1 A. Plain CT scan of the neck in a 38-year old female with acquired tracheal stenosis (Case # 1) due to the development of granulation tissue (white arrow) in the tracheal. B. Reformatted CT Scan of the neck and upper chest in the same patient showing multiple tracheal stenosis due to granulation tissue (Arrow). C. Plain CT Scan of the neck in the same patient after 8 months of repeated rigid bronchoscopic dilatation of the tracheal. The tracheal size is normal (White arrows).

Table 2 Pulmonary function test results before and after rigid bronchoscopic dilatations in 3 patients with post-endotracheal intubation tracheal stenosis

Case No	VC(L)			FVC(L)			FEV ₁ (L)			FEV ₁ /VC%		
	Pre dilatation	Post dilatation	% change	Pre dilatation	Post dilatation	% change	Pre dilatation	Post dilatation	% change	Pre dilatation	Post dilatation	% change
1	1.2	2.22	85.0	1.24	2.20	77.42	0.33	2.07	527.27	27.6	93	236.96
2	1.15	2.28	98.3	1.87	2.59	38.50	0.53	2.10	296.23	32.0	77.8	143.13
3	2.48	2.34	-5.65	2.45	2.7	8.16	0.91	2.38	147.0	36	88.0	144.44

VC: Vital capacity (Litres); FVC: Forced vital capacity (Litres). FEV₁: Forced vital capacity in 1 second.

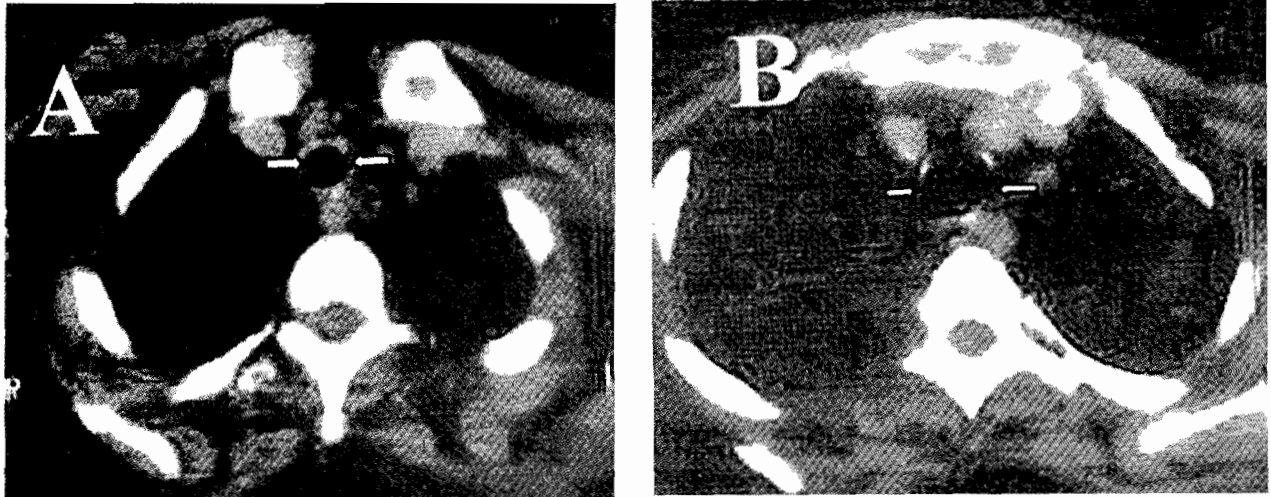


Fig. 2 A. Plain CT scan of the neck in a 14-year old female with acquired tracheal stenosis (white arrows) (Case # 2). B. Plain CT scan of the same patient after 7 months of repeated rigid bronchoscopic dilatation of the trachea. The tracheal size is normal (White arrows).

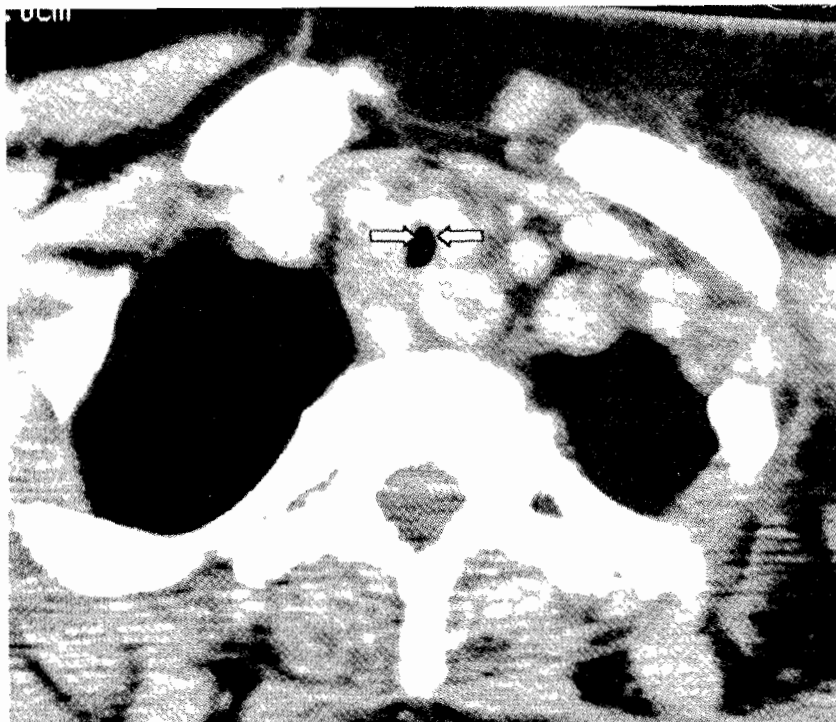


Fig. 3 Plain CT scan of the neck in a 20-year old female with acquired tracheal stenosis (Case # 3) due to the development of granulation tissue (white arrow) in the trachea.

12 months respectively in the three cases. The mean follow-up period was 18.5 months.

Discussion

The aetiology of PITS has been identified to be due to excessive pressure on the trachea by the cuff of the endotracheal tube which leads to local ischaemic necrosis of the tracheal cartilage and excessive growth of granulation tissue¹⁻⁴. Granulation tissue was demonstrated radiologically and was seen during bronchoscopy in our patients (Fig. 1). All the three patients that have been presented developed PITS following endotracheal intubation for mechanical ventilation. The duration of endotracheal intubation that predisposes to PITS appear to be very variable. In one of our patients, endotracheal intubation lasted for only two days (Case2). Polderman, et al.,¹¹ reported the development of tracheal haematoma and swelling of the posterior wall of the trachea leading to intermittent tracheal obstruction within 2 to 21 days in patients who had percutaneous dilatational tracheostomy. The periodic obstruction was due to intermittent pressure and chaffing on the posterior tracheal wall. Although the recognition of the aetiology of PITS and modifications in the design and management of endotracheal tubes have led to a diminished incidence of PITS¹ several cases continue to be reported world wide^{5, 6, 8, 10-12}. PITS has been reported in both the paediatric and adult age groups^{6, 10, 12-14}. The arithmetic mean age in our patients was 24 ± 12.49 years.

The modalities that have been employed for the management of PITS include endoluminal stenting⁵, surgical resection and reconstruction^{1, 6, 7, 9}, percutaneous dilatation, rigid bronchoscopic dilatation³, fiberoptic bronchoscopic balloon dilatation⁸, dilatation with an intra-aortic balloon pump¹⁰ and Nd:YAG (neodymium: yttrium-aluminum garnet) laser therapy with or without stenting^{3, 2}. With the multiplicity of available methods of management, it is clear that the use of any of the treatment options has to be tailored to the patient's individual needs and the available local resources^{5, 6, 8, 12, 13, 15}. The desired outcome measure in all cases is the elimination of tracheal stenosis and the satisfactory improvement in the patients' ventilatory parameters^{13, 16}.

In each of the three patients presented, rigid bronchoscopic dilatation produced statistically significant improvements in their ventilatory parameters. The mean percentage changes (pre-dilatation versus post-dilatation) in VC, FVC, FEV₁ and FEV₁/VC% in the three patients were $59.22 \pm 56.57\%$ (range = -5.65-98.3%), $41.36 \pm 34.71\%$ (range = 8.16-77.42%), $323.50 \pm 191.60\%$ (range = 147.0-527.27%) and $174.84 \pm 53.80\%$ (range = 143.13-236.96%) respectively (Table 2). The percentage change between pre- and post-dilatation values of FEV₁/VC% was significant ($p=0.002$, 95% Confidence Interval = -1.9324 to -1.2542). Significant improvements in respiratory function were also reported by Manduor, et al.,¹⁵ following endoscopic dilatation of PITS. Management by tracheal resection did not provide a higher improvement in respiratory function¹³.

The mean follow-up period reported by Manduor, et al.,¹⁵ for their patients with PITS treated by laser endoscopically

was 12.58 months while the mean follow-up in our patients was 18.5 months. In the follow-up period, none of our patients developed re-stenosis of the trachea. In 11 patients with PITS who were treated by surgical resection over a 6-year period and reported by Vaamonde, et al.,¹² complete cure was seen in 44% while 33% had partial improvement.

Conclusion

Rigid bronchoscopic dilatation in patients with PITS provides safe, effective tracheal dilatation and improved pulmonary function in the medium term.

References

1. Wain JC. Postintubation tracheal stenosis. *Chest Surg Clin N Am* 2003; 13(2): 231-46.
2. Terashima H, Sakurai T, Takahashi S, Saitoh M, Hirayama K. Postintubation ; May 6tracheal stenosis; problems associated with choice of management. *Kyobu Geka* 2002; 5(10): 837-42.
3. Chhajed PN, Malouf MA, Glanville AR. Bronchoscopic dilatation in the management of benign (non-transplant) tracheo-bronchial stenosis. *Intern Med J* 2001; 31(9): 512-6.
4. Meneghini L, Zadra N, Metrangolo S, Narne S, Giusti F. Post-intubation subglottal stenosis in children: risk factors and prevention in pediatric intensive care *Minerva Anestesiol* 2000; 66(6): 467-71.
5. Mostafa BE. Endoluminal stenting for tracheal stenosis. *Eur Arch Otorhinolaryngol* 2003; May 6 [epub ahead of print].
6. Marel M, Pekarek Z, Fila L, Spasova I, Pafko P, Schutzner P, Pospisil R, David I. Benign stenoses of the large respiratory airways *Cas Lek Cesk* 2002; 141(19): 610 - 4.
7. Rea F, Callegaro D, Loy M, Zuin A, Narne S, Gobbi T, Grapeggia M, Sartori F. Benign tracheal and laryngotracheal stenosis: surgical treatment and results. *Eur J Cardiothorac Surg* 2002; 22(3): 352-6.
8. Li Q, Bai C, Dong Y, Zhao L, Yao X, Xu H, Liu Z, Wang Q, Zhonghua Jie He He Hu Xi Za Zhi Results of bronchoplasty by fiberoptic bronchoscopic balloon dilatation in the management of proximal benign tracheobronchial stenosis 2002; 25(8): 481- 4.
9. Stanic V, Stepic V, Kovacevic S, Cvorovic N, Cvijanovic V, Ristanovic A, Gulic B. Resection of post-intubation tracheal stenosis *Vojnosanit Pregl* 2000; 57(1): 99 -104.
10. Loubani M, Machin D, Shawkat S, Leverment JN. Use of the intra-aortic balloon pump for dilatation of benign tracheobronchial strictures. *Thorac Cardiovasc Surg* 2002; 50(5): 310-1.
11. Polderman KH, Spijkstra JJ, de Bree R, Christiaans HM, Gelissen HP, Wester JP, Girbes AR. Percutaneous dilatational tracheostomy in the ICU: optimal organization, low complication rates, and description of a new complication. *Chest* 2003; 123(5):1595-602. Comment in: *Chest*. 2003; 123(5): 1336-8.

12. Vaamonde Lago P, Garcia Soto N, Martin Martin C, Cajade Frias JM, Labella Caballero T. Surgical treatment of laryngotracheal stenoses. Our experience. *An Otorrinolaringol Ibero Am* 2003; 30(1): 39-46.
13. Stotz WH, Berkowitz ID, Hoehner JC, Tunkel DE. Fatal complication from a balloon-expandable tracheal stent in a child: a case report. *Pediatr Crit Care Med* 2003; 4(1): 115-7.
14. Aidonis A, Nikolaou A, Bourikas Z, Aidonis I. Management of tracheal stenosis with a titanium ring and nasal septal cartilage. *Eur Arch Otorhinolaryngol* 2002; 259(8): 404-8.
15. Mandour M, Remacle M, Van De Heyning P, Elwany S, Tantawy A, Gaafar A. Chronic subglottic and tracheal stenosis: endoscopic management vs. surgical reconstruction. *Eur Arch Otorhinolaryngol* 2003; 260(7): 374-80.
16. Gotway MB, Golden JA, LaBerge JM, Webb WR, Reddy GP, Wilson MW, Kerlan RK Jr, Gordon RL. Benign tracheobronchial stenoses: changes in short-term and long-term pulmonary function testing after expandable metallic stent placement. *J Comput Assist Tomogr* 2002; 26(4): 564-72.