

Transverse Leukonychia: A case report

*V. Modesto dos Santos¹, T. Arruda Modesto Sugai², B. F. Cezar³ and A. C. Vasconcellos de Rezende³

¹Catholic University and Armed Forces Hospital, Brasilia-DF, Brazil.

¹SMPW Quadra 14 Conjunto 2 Lote 7 Casa A Sector de Mansões Park Way, 71745 -140 Brasilia-DF Brazil

²Brazilian Society of Dermatology, Brasilia-DF, Brazil

³Armed Forces Hospital, Brasilia-DF, Brazil.

E-mail: vitorinomodesto@ig.com.br

Summary

A case of transverse leukonychia following chemotherapy for Hodgkin's disease in a 17-year-old white male is reported. The patient presented with multiple white bands across the fingernails, which appeared three weeks after the end of chemotherapy. The changes were almost homogeneously spread across the breadth of the fingernail plates, showing smooth borders with a rounded distal edge. Because of Hodgkin's disease in Costwold stage IE, he received sequential chemotherapy with cyclophosphamide, adriamycin, procarbazine, prednisolone, vincristine and bleomycine, and mediastinal mass irradiation. The authors emphasize that white transverse nail banding – Leukonychia striata or Muehrcke lines - constitute an aesthetical unpleasant side-effect of medication, but may represent an easily observed sign indicative of previous use of cytotoxic therapy for malignancy.

Key-words: *Chemotherapy-induced nail changes, Hodgkin's disease, Leukonychia striata, Muehrcke lines.*

Résumé

Un cas d'un leuconychie transversale à la suite d'une chimiothérapie pour la maladie de Hodgkin chez un blanc du sexe masculin âgé de 17 ans est l'objet de ce rapport. Le patient est atteint de la bande blanche tout autour des ongles de la main qui est apparu trois semaines après la fin de la chimiothérapie. Les différences étaient apparus d'une manière homogène presque au tour de la largeur des plaques d'ongle de la main tout en indiquant des frontières douces avec des bords rond distals avec la maladie d'Hodgkin dans l'état costwold^{1E}, on l'avait donné la chimiothérapie séquentielle avec le cyclophosphamide, adriamycine, procarbazine, prednisolone, vincristine et bleomycine, et irradiation médiastinale de masse. Les auteurs ont souligné que la bande d'ongle transversale - leuconychie straita ou des lignes de muchrcke - constituent un résultat esthétique très malsain du médicament, mai qui pourrait signaler un signe facilement observable indicatif de l'utilisation précédente de la thérapie cytotoxique pour une malignité.

Introduction

This is a case report of transverse leukonychia

*Correspondence

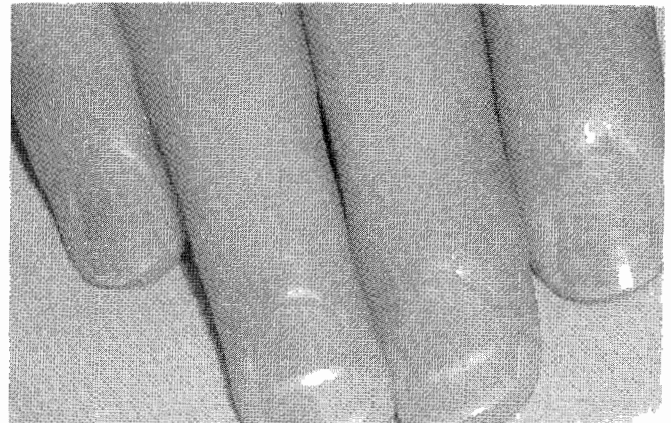


Fig. 1 Multiple transverse white striations across the right fingernails of a patient undergoing poly-chemotherapy for Hodgkin's disease.

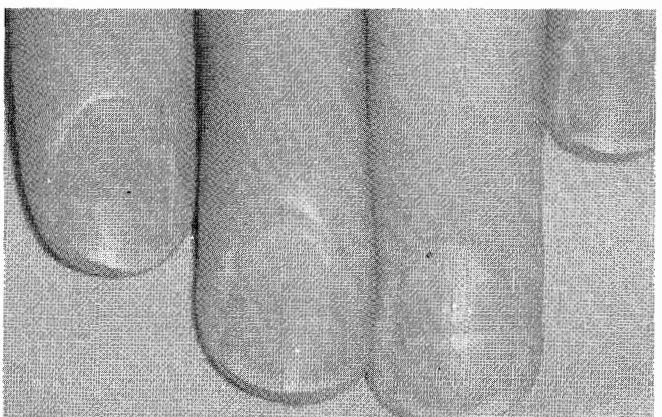


Fig. 2 Less conspicuous transverse white striations on the left fingernails.

antineoplastic agents have been associated with the development of transverse leukonychia in oncology patients, cyclophosphamide, doxorubicin and vincristine are the agents most frequently involved². Noteworthy, in cases of drug-induced transverse leukonychia, discontinuation of the causative agents will prevent recurrent episodes.

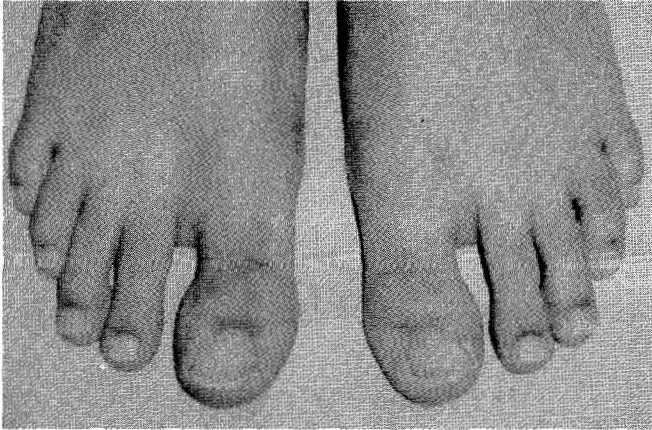


Fig. 3 Normal aspect of the patient's toenails.

Case report

A right-handed 17-year-old white male came to hospital, because of fever and aqueous diarrhoea for five days. Until three weeks before the onset of symptoms, he was undergoing polychemotherapy for Hodgkin's disease. During the course of his treatment, he was submitted to sequential chemotherapy, in addition to mediastinal mass irradiation. The recent treatment included cyclophosphamide 650 mg/m² IV (day 1), adriamycin 25 mg/m² IV (day 1), procarbazine 100 mg/m² IV (days 1-7), prednisolone 40 mg/m² PO (days 1-14), vincristine 1.4 mg/m² IV (day 8) and bleomycine 10 mg/m² IV (day 8).

On admission, he was alert, pale, with universal alopecia. Temperature was 38.5°C. Other systems were essentially normal. Multiple transverse white curvilinear bands, separated by normal pink nail colour, were noted on all fingernails, more conspicuously on the right (Fig. 1) than on the left hand (Fig. 2), while the toenails were

found entirely normal (Fig. 3).

Routine blood tests were essentially within the normal range. Urinalysis showed no abnormality.

Discussion

Transverse leukonychia has been associated with a variety of conditions, including arsenic intoxication, local trauma, acute and chronic renal failure, liver disease, myocardial infarction, malnutrition, pellagra, immunohemolytic anaemia, sickle cell anaemia, systemic lupus erythematosus and Hodgkin's disease^{1,2,3,4,5}. The diagnosis of Hodgkin's disease was established in our patient; so, a possible concern would be about the role of this disease on the origin of the fingernail changes. However, we have observed that as the normal-appearing nail plate was growing, the white bands were moving toward the distal tip. Thus, as described in similar cases, the leukonychia tends to disappear after cessation of chemotherapy, indicating that changes are due to

treatment, rather than the underlying malignancy^{2,4}.

Moreover, the albumin serum level was normal, and a clear temporal relationship may be established between the administration of chemotherapeutic drugs and the appearance of transverse leukonychia in our patient. In fact, the whitish nail bands appeared early after the first cycle of cytostatic agents and increased in number following the course of polychemotherapy^{2,4}.

Noteworthy in this case is the finding of whitish changes exclusively on the fingernails. In fact, the fingernails often provide more subtle clinical information than toenails because trauma is more likely to occur⁵, in addition to the fact that toenails grow more slowly than fingernails^{6,7,8}.

Although the origin of the transverse white bands in fingernails remains to be entirely cleared, at least in part, they are due to an injury on the mitotically active cells of the nail matrix, which leads to abnormal keratinisation, with retention of nuclei or nuclear debris in the nail plate³. The number and the distance between two successive white bands often keep relationship with the number and duration of respective chemotherapy cycles².

The authors emphasize that white transverse nail banding may constitute an aesthetical unpleasant side-effect of medication, but may represent an easily observed sign indicative of previous use of cytotoxic therapy for malignancy.

References

1. Muerhcke RC. The finger-nails in chronic hypoalbuminemia. *Br. Med. J.* 1956; 1: 1327.
2. Chapman S, Cohen PR. Transverse leukonychia in patients receiving cancer chemotherapy. *South. Med. J.* 1997; 90: 395-398.
3. Deliliers GL, Monni P. Nail transverse white bands induced by antileukemic chemotherapy. *Haematologica* 2001; 86: 333.
4. Naumann R, Wozel G. Transverse leukonychia following chemotherapy in a patient with Hodgkin's disease. *Eur. J. Dermatol.* 2000; 10: 392-394.
5. Daniel CR 3rd, Osment LS. Nail pigmentation abnormalities. Their importance and proper examination. *Cutis* 1980; 25: 595-607.
6. Bean WB. Nail growth. Thirty-five years of observation. *Arch. Intern. Med.* 1980; 140: 73-76.
7. Geyer AS, Onumah N, Uyttendaele, Scher RK. Modulation of linear nail growth to treat diseases of the nail. *J Am. Acad. Dermatol.* 2004; 50: 229-234.
8. Heikkilä H, Stubb S, Kiistala U. Nail growth measurement employing nail indentation – an experimental follow-up study of nail growth in situ. *Clin. Exp. Dermatol.* 1996; 21: 96-99.