

# Osteomyelitis of the pubic ramus misdiagnosed as septic arthritis of the hip

Saeed M. Al-Qahtani

Department of Surgery (Orthopaedics) College of Medicine and  
Medical Sciences King Khalid University, Abha, Saudi Arabia, P. O. Box 1268.  
E-mail: [sqahtani1@yahoo.com](mailto:sqahtani1@yahoo.com)

## Summary

This is a case report of an 11-year-old male Saudi who presented with osteomyelitis of the left pubic ramus who was misdiagnosed and treated as a case of septic arthritis of the hip. Subsequent re-evaluation upon referral was carried out using CT scan and MRI which clarified the diagnosis. The lesion was explored, the pus drained and necrotic material excised. The patient was subsequently managed on antibiotics with complete resolution. The rarity of pelvic osteomyelitis in childhood is stressed and the causes for delay in diagnosis are stressed.

**Keywords:** *Osteomyelitis, Pubic ramus, Misdiagnosed.*

## Résumé

Il s'agit d'un rapport d'un saoudien du sexe masculin, âgé de 11 ans qui s'est présenté atteint de l'osteomyélite du pubis ramus du côté gauche chez qui on a fait une erreur du diagnostic donc a été traité pour un cas de l'arthrite septique de la hanche. Au cours d'une réévaluation ultérieure a la suite d'un envoi avec ;'utilisation du CT Scan et MRI qui ont éclairci le diagnostic. La lésion a été traitée, drain le pus et coupé le matériel nécrotique. Puis on a traité le patient avec l'administration des antibiotiques avec une résolution complète. On mis en relief la rareté d'ostéomyélite pendant l'enfance et les causes pour le retard pendant le diagnostic.

## Introduction

Pelvic osteomyelitis in children is rare. It accounts for between 3-8% of all cases of osteomyelitis in childhood.<sup>1-4</sup> The diagnosis is usually delayed and the treating physician can be misled into making a diagnosis of osteomyelitis of the hip.

We report herein a case of osteomyelitis of the inferior pubic ramus in an 11-year-old boy misdiagnosed and treated as septic arthritis of the hip.

## Case report

An 11-year-old boy was referred to the Orthopaedic clinic at the Asir Central Hospital, Abha by a colleague who had treated him in the past. At presentation, he complained of pain in his left groin and left hip for 5 days prior to admission. The pain was associated with fever and difficulty in walking. The pain radiated to the medial aspect of the left thigh. There was no history of trauma.

## Past medical history

The patient had a similar attack 3 ½ months earlier and was seen by an orthopaedic surgeon who diagnosed him as a case of septic arthritis of the left hip and performed an arthrotomy. There was no pus in the joint and culture swab

taken from the joint did not yield any microorganism. The patient received intravenous antibiotics (Cloxacillin 500 mg 6 hourly) improved and was discharged on oral antibiotics (Cloxacillin 500 mg) for 4 weeks.

## Physical examination

The patient was febrile with a temperature of 38.5°C. He looked ill. He walked with difficulty. There was no swelling, redness or increased warmth over his left groin and hip areas. There was tenderness over the left groin area. Regional lymph nodes were not enlarged. His active range of motion was painful but passive range of motion was less painful. When the leg was fully extended, it could be rolled from side to side with minimal pain. Rectal examination was not done.

## Laboratory findings

Hemoglobin level was 13.9 g/dl, the white cell count was  $13.6 \times 10^9/L$  with 68% neutrophils. The erythrocyte sedimentation rate (ESR) was 72 mm/h. Serum calcium, phosphorous, alkaline phosphatase, urea, creatinine and electrolytes were all normal.

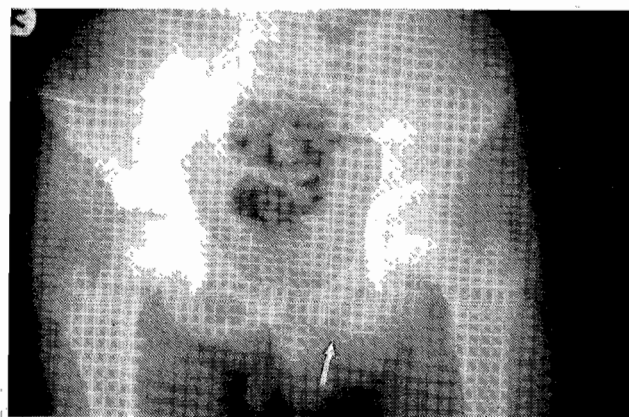


Fig. 1 Plain X-ray of the pelvis showing lesion of the left inferior pubic ramus (Arrow).

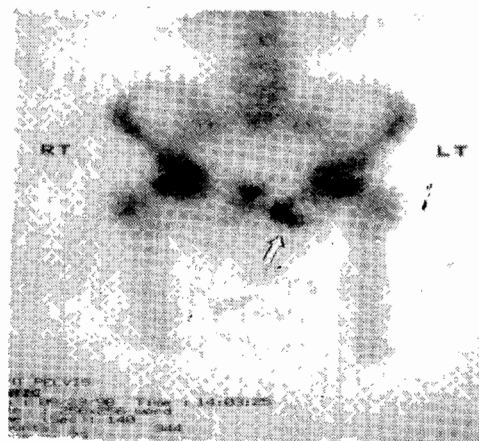


Fig. 2 Bone scan showing increased uptake in the left inferior pubic ramus (Arrow).

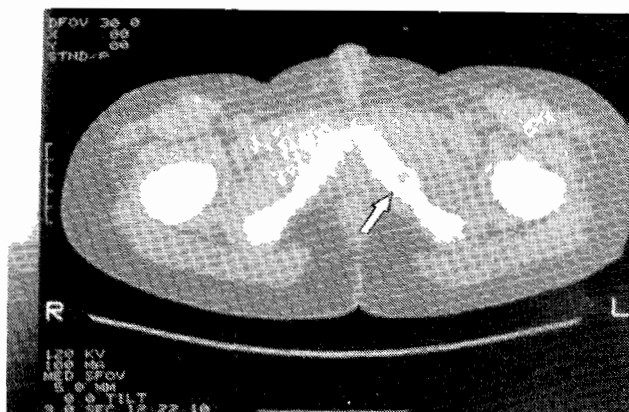


Fig. 3 CT Scan of the pelvis showing a lytic lesion in the inferior pubic ramus (Arrow).

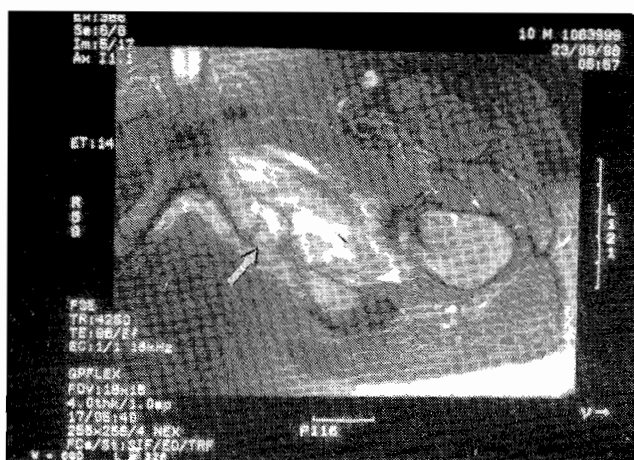

Fig. 4 MRI of the pelvis showing lesion of the inferior pubic ramus with soft tissue edema (Arrow).

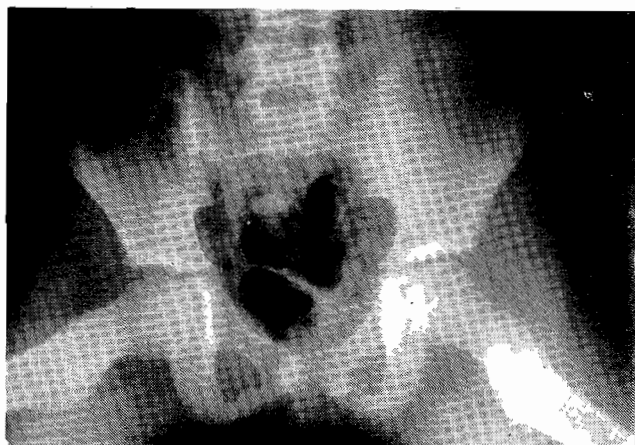

Fig. 5 Plain X-ray of the pelvis 18 months after discharge from the hospital. The lesion in the left inferior pubic ramus has healed.

### Radiological findings

Plain X-ray of the pelvis showed a lytic lesion in the left inferior pubic ramus (Fig. 1) which was also present in the old X-ray from previous admission. A technetium-99 bone scan was performed and showed increased uptake in the left inferior pubic ramus (Fig. 2). CT-scan showed a lytic lesion in the inferior pubic ramus (Fig. 3). MRI showed the same findings with oedema in the soft tissues (Fig. 4).

### Treatment and clinical course

After the above investigations, the patient was taken to the operating room and exploration of the pubic ramus was performed through a vertical incision in the left groin with dissection between the adductors and the medial hamstring. There was a lytic lesion in the middle of the inferior pubic ramus. The lesion was full of pus and granulation tissue. The bone was soft and looked abnormal. Gram stain of the material from the lesion showed gram positive cocci and cultures yielded *Staphylococcus aureus* which was sensitive to cephadrine. Cephadrine was started intravenously (500 mg every 6 hours) for two weeks then orally for four weeks.

Histopathology of the material from the lesion confirmed acute-on-chronic osteomyelitis. The patient improved post-operatively. He became afebrile, his pain disappeared and his gait returned to normal. He was discharged on the 16<sup>th</sup> day of admission to continue his oral antibiotics at home.

His ESR had fallen to 32 mm/L by the time of his discharge. Outpatient follow up over a period of 18 months showed complete recovery and healing of the lesion (Fig. 5).

### Discussion

Osteomyelitis of the pelvis is a rare disease.<sup>1-4</sup> The incidence varies from 3-8% of cases of osteomyelitis in childhood.<sup>1-4</sup> The iliac bone is most commonly affected (40%), followed by the ischium (28%) and the pubis (15%).<sup>7</sup> Osteomyelitis of the pelvis tends to occur more commonly in children over 7 years of age.<sup>1</sup> The etiology of pelvic osteomyelitis is usually obscure, but trauma can be a predisposing factor in children. In adults, pelvic osteomyelitis may be secondary to pelvic surgery, prostatectomy, parturition and parenteral drug abuse.<sup>1-4</sup>

Osteomyelitis of the pelvis in children has been reported to be a diagnostic problem<sup>1-4</sup> and presentation can be misleading. In the case presented, it was misdiagnosed as septic arthritis of the hip and the patient underwent an unnecessary arthrotomy. Presentation has been reported to simulate other disease process such as acute abdomen, septic arthritis of the hip, nephrolithiasis, osteomyelitis of the proximal end of femur, neoplasia and discitis.<sup>2</sup> The most common bacterial pathogen is *Staphylococcus aureus* accounting for up to 80% of cases followed by *Salmonella*.<sup>5</sup> *Staphylococcus aureus* was the organism isolated in our case.

Early diagnosis can be facilitated by a high index of suspicion and detailed physical examination. Appropriate laboratory work-up, a technetium bone scan MRI and/or CT-scan followed by aspiration and culture of the material obtained from the involved area helped us to reach a definite diagnosis.

Most cases of pelvic osteomyelitis can be treated with antibiotics alone and surgery is reserved for the cases not responding to antibiotic therapy or in those patients who develop an extra-osseous abscess.<sup>2-6</sup>

### Acknowledgement.

I would like to thank Dr. Modood Ali, Associate Professor of Orthopaedics for reviewing this manuscript and Mr. Jolly Mathews for his secretarial assistance.

**References**

1. R. Gregory Simms, B. ST. John Brown, John C. Hyndman, Richard B. Goldbloom. Osteomyelitis of the pubis in childhood. *CMA Journal*, 1981;124: 1028-30.
2. Thomas R, Highland, Richard L Lamont. Osteomyelitis of the pelvis in children. *Journal of Bone and Joint Surgery*, 1983; 65-A: 230-34.
3. Ramon del Busto, Edward L. Quinn, Evelyn J. Fisher, Tom Madhavan. Osteomyelitis of the pubis. *JAMA*, 1982; 248: 1498-1500.
4. Rand N, Mosheiff R, Matan Y, Port S, Shapiro M, Liebergall M. Osteomyelitis of the pelvis. *Journal of Bone and Joint Surgery*, 1993; 75-B: 731-733.
5. Nandini Narasimhan and Melvin Marks. Osteomyelitis and septic arthritis. In: Richard E. Berkman, Robert M. Kliegman, Ann M. Arvin, editors. *Nelson Textbook of Pediatrics*, Philadelphia, W.B. Saunders Company, 1996; 724-733.
6. Ahmad A.H. Al-Omar, Mosarrat J. Qureshi, Abdullah S. Al-Jarallah, Khalid F. Al-Mobeireek. Pelvic osteomyelitis due to *Haemophilus influenzae* type B in a Down syndrome child. *Annals of Saudi Medicine*, 2002; 22: 341-343.
7. Zvulunov A, Gal N, Sege VZ. Acute hematogenous osteomyelitis of the pelvis in childhood: Diagnostic clues and pitfalls. *Pediatric Emergency Care*, 2003; 19: 29-31.