

Arrow injury to the skull base

*A. O. A. Ogunleye¹, A. O. Adeleye,² K. J. Ayodele,¹ M. O. Usman¹ and M. T. Shokunbi²

¹Department of Otorhinolaryngology, University College Hospital, Ibadan

²Neurosurgical unit, Department of Surgery, University College Hospital, Ibadan.

E-mail: arduch@skanet.com

Summary

An unusual case of penetrating nasal injury with middle skull base involvement, from fired arrow is reported. The arrow was surgically removed and the patient remains well with no sequelae. We therefore present this case because of its rarity. The anatomical principles underlying the surgical management of the lesions are discussed.

Keywords: Injury, Arrow, Nasal, Skull base

Résumé

Un cas peu commun de la blessure natale perforante impliquant la base centrale du crâne à la suite de lancement d'un flechette est l'objet de ce rapport. On avait enlevé la fleche à travers la chirurgie et la patient est en bonne sante sans aucun cas de la sequelle. Donc, nous présentons ce cas à cause de son rareté.

On a traité les principes anatomiques sousjacent la prise en charge chirurgique des lésions.

Introduction

Arrow shafts are constructed from a variety of materials and are generally equipped with either a field tip or a broadhead tip.¹ The arrow injuries depend on the type of bow and arrow used.

The broadhead, used predominantly for hunting is generally constructed of aluminium alloy, high-carbon steel, or titanium-nitride of Teflon-coated tips and may be fitted with three to five razor-sharp blades.¹

The field tip, commonly used in target practice, possesses a tip diameter equal to that of the shaft and entrance wounds closely simulate gunshot wounds, while the broad head arrow is associated with a stellate entrance wound and increased tissue destruction.²

The average velocity of a broad head arrow fired from a compound bow is 60 to 90m/s.¹

We present a case of arrow injury to the nasal cavities with skull base involvement in a male patient.

Case report

A 30-year-old Nigerian farmer presented five days after being shot by armed robbers with an arrow. The arrow had penetrated through the nose and remained firmly since then.

There was associated minimal and transient bleeding around the entry point. There were no other nasal symptoms. No impairment of consciousness, headache, seizures or ophthalmological symptoms or signs since the incident. The general physical examination revealed a conscious and alert young man, not in any obvious distress.

There was fullness on the anterior dorsum of the nose at the point of entrance of the metallic object. It was projecting outwards about 4cm from its entry points and the entry point was about 1cm from the midline of the nasal bridge on the left side. The object was inclined about 10° and 30° to the hori-

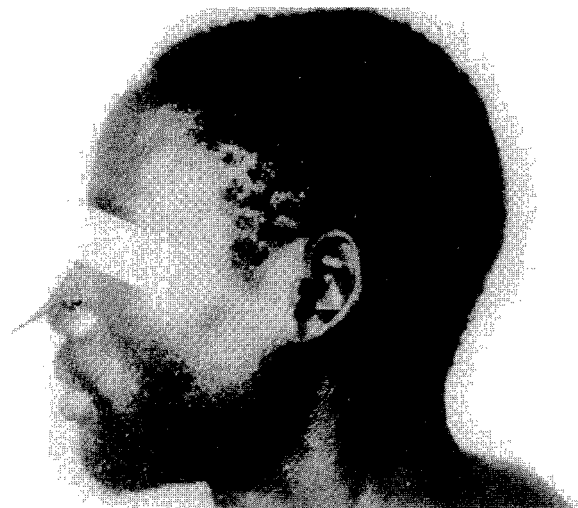

Fig. 1 Lateral view of the patient's face showing the external position of the foreign object

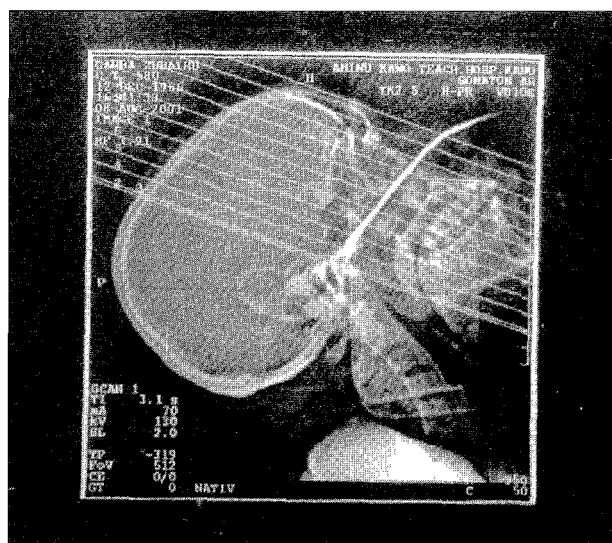


Fig. 2 CT scan of the brain and sino-nasal cavities showing the passage of the foreign object



Fig. 3 Foreign object (Arrow) that was surgically retrieved from the patient (15cm in actual length).

* Correspondence

zontal and vertical planes respectively (Fig. 1). Engorged inferior turbinates were noted bilaterally though the object was not visualized intranasally. Neurological and ophthalmological examination revealed no abnormalities.

A CT scan of the sinuses, nasal cavities and cranium revealed a uniformly radio-opaque metallic object extending from the dorsum of the nose, through the left nasal cavity, nasal septum, right nasal cavity and passing in close relation to the right sphenoidal sinus floor and impacting in the region of the pterygopalatine fossa on the right. The sinuses and the orbits appeared normal, Figure 2.

A diagnosis of penetrating nasal injury with foreign body impaction in the skull base was made.

The arrow measuring 15cm in length was removed by performing a right medial maxillectomy through a right Moore's incision with Weber's extension.³

Since no CSF leak was observed intraoperatively after the object had been removed and with CT scan findings, no further intracranial exploration needed to be carried out on the patient.

The patient remains well with no sequelae.

Discussion

The simplest classification divides penetrating missile injuries into high velocity and low velocity categories, relating the severity of the wound to the muzzle or initial velocity and energy content of the missile.^{4,5} The type of missile injury in this case could be regarded as low velocity category. (Figure 3).

The behaviour of a missile depends upon several variables, such as its size, shape, aerodynamic stability and velocity. Tissue density and elasticity will greatly modify both the stability and the velocity of the missile. This to a great degree, will limit the extent of tissue damage produced by the passage of the missile.⁶ Thus the extent of tissue damage depends on the amount of energy expended by the missile at the point of tissue penetration.⁶ It is of note that little damage beyond the trajectory was observed in this patient. This conforms with the nature and speed of penetration of the object.

Due to the path of the object through left nasal cavity, nasal septum, right nasal cavity and passing in close relation to the right sphenoidal sinus floor, impacting in the region of the right pterygopalatine fossa and for adequate exposure of the object intra-operatively a right medial maxillectomy through Moore's incision with Weber's extension had to be done before the impacted object could be delivered (Figure 2).

Levi et al in their present report analyzes 116 penetrating craniocerebral injuries. The site of impact was at the skull convexity in 87% of cases and at the base of the skull in the remaining 13%.⁷

These were mainly high-velocity bullets, shrapnel, stones from explosive devices, and in one case a radio antenna penetrated the head through the orbit.⁷

Arrow injuries to the brain, other than in tribal conflicts in which the orbits is a prime target, are exceedingly rare.⁸

O'Neil et al presented a case of non-fatal transorbital penetrating arrow injury to the brain.¹ The case highlighted

the necessity for anterograde removal of the arrow in the direction of its lines of trajectory.

Pandey et al reported an unusual arrow injury in which point of entrance was at the inner canthus of the right eye. The arrow was lying against the right eyeball, along the upper part of the pharynx with its tip embedded in the prevertebral muscle.⁹

Two cases of skull base-penetrating injuries through naso-orbital routes caused by umbrella tips were reported by Tokitsu et al and these were accompanied by serious neuro-ophthalmic manifestations and sequelae after treatment.¹⁰ It was concluded that skull base, because of its anatomical characters is likely to be penetrated in orbital and peri-orbital injury.

Since no CSF leak was observed preoperatively and intraoperatively after the object had been delivered and with CT scan findings, no further intracranial exploration needed to be carried out on the patient.

The arrow in this patient is constructed of iron and measured 15cm in length with a barb on each side of the body near the head to add to tissue destruction ability of this arrow, (fig. 3).

The CT imaging (fig 2) seen in this case was almost similar to the one reported by Shandera and Hayman.¹¹ However in their case the object was a galvanized nail fired accidentally from a nail gun.

Angiography is one of the investigations needed to be done in this case before definitive surgical treatment to exclude damage to large vessels at the skull base. However, the facilities were non-functional at the time of presentation. Besides, there were no clinical symptoms and signs (including CT scan findings) suggestive of a vascular injury.

Conclusion

We have presented a case of transnasal penetrating arrow injury to the middle skull base, which was successfully treated surgically. This is a rare surgical problem.

The knowledge of surgical anatomy of this area is essential for the management of such a case.

The development of more complex and diverse assault weapons may result in an increase of uncommon forms of penetrating injury to the nose, skull base and/or brain.

References

1. O'Neil O R, Gilliland G, Delashaw JB and Purtzer TJ: Transorbital penetrating head injury with a hunting arrow. Case report Surgical neurology 1994; 42:494-97.
2. Hain JR: Fatal arrow wounds J. Forensic Sci 1989; 34: 691 - 93.
3. Maran AGD, Gaze M and Wilson JA: Tumours of the nose and sinuses. In: Stell and Maran's head and neck surgery, 3rd edn. Oxford: Butterworth-Heinemann, 1993; 176 - 193.
4. Demuth WE Jr.: Bullet velocity and design as determinants of wounding capacity. An experimental study. J. Trauma. 1966; 6: 222 - 32.
5. Demuth WE Jr. Bullet velocity and design as applied to military rifle wounding capacity. J. Trauma 1969; 9: 27 - 38.

6. Saba IM: Surgical management of gunshot wounds of the head. In: Schmidela HH, Sweet WH, eds. Operative neurosurgical techniques, 2nd edn. Philadelphia: W. B. Saunder, 1988; 37 - 48.
7. Levi L, Borovich B, Guidburd J N, Grushkiewics I, Lemberger A and Linn S et al: Penetrating craniocerebral injuries. Israel Journal of medical sciences 1990; 26: 548 - 54.
8. VanGurp G, Hutchinson TJ and Alto WA: Arrow wound management in Papua New Guinea. J. Trauma 1990; 30: 183 - 88.
9. Pandey S, Sinha SN, Sahay LK and Tiwary RN: An unusual arrow injury. International surgery. 1972; 57: 589.
10. Tokitsu M, Nakamura M, Yokoyama H, Watanabe H, Hera M and Takenchi K: Skullbase penetrating injuries caused by umbrella tips: case reports. No Skinkei Geka - Neurological surgery, 1990; 18:189 - 92.
11. Shandera WX and Hayman A: Nail injury to the skull N. Engl. J. Med 2001; 345: 339.