

Mastoid cells myiasis in a Saudi man: A case report

Abdul Aziz Al-Abidi, *Cornelius Bello², Mohammed Al-Ahmari¹ and Yinka Fawehinmi¹

Departments of Ear, Nose and Throat, Head and Neck¹ and Microbiology²
Assir Central Hospital, Box 34, Abha, Saudi Arabia.

Summary

We report here the case of myiasis of the mastoid cells in a 50-year old Saudi farmer.

Eight larvae of suspected *Calliphorid* fly were extracted from his right mastoid at examination in the clinic. The larvae almost ate into his brain, using their powerful screw-shaped mouth parts. It is the first report of *Calliphorid* larvae affecting the mastoid cells from Saudi Arabia. The epidemiological and clinical implications of this finding are discussed below.

Keywords: Myiasis, Mastoid bone, Saudi Arabia.

Résumé

Notre rapport est basé sur le cas de la Myiase des cellules mastoïdes chez un cultivateur d'origine saoudien âgé de 50 ans. Huit larves soupçonnées d'être des mouches calliphorides ont été arrachées de son côté droit mastoïde au cours d'examen médical dans un centre médical. Les larves ont presque entré dans son cerveau à l'aide de leur parties de bouche en forme de vis. C'était le premier rapport des larves calliphorides qui affectent les cellules mastoïdes venant de l'Arabie saoudite. Les implications épidémiologique clinique de ce résultat sont traitées ci-dessous.

Introduction

Myiasis is the infestation of live human and vertebrate animals with fly larvae which, at least for a certain period, feed on the host's dead or living tissue, liquid body-substances, or ingested food.¹ The three categories of medically important myiasis are:

1. Obligatory (or specific) myiasis, involving parasites which must develop on the live hosts. 2. Facultative (or semi specific) myiasis, involving parasites which can develop on both living and dead organic matter. 3. Accidental myiasis, infestations are usually accidental and occur infrequently. The flies that most commonly cause obligatory and facultative myiasis belong to the families *Oestridae* (the warble flies and the bot flies), the *Sarcophagidae* (the flesh flies), and the *Calliphoridae* (the blow flies).¹

Different forms of myiasis (including those involving the *Calliphorid* larvae), have been reported from Saudi Arabia, and from the Assir region of Saudi Arabia in particular.^{2,3} This report documents what we believe is the first case of *calliphorid* larvae affecting the mastoid cells in a human subject.

Case report

On 4th February, 2003, a 50 year-old Saudi male from a suburb of Abha, Assir region of Saudi Arabia presented to the Emergency Room (ER), of the Assir Central Hospital, Abha, with a two-day history of excruciating pain in the right ear associated with discharge. Further enquiry revealed that he had had recurrent right ear discharge for eight years. The discharge

was whitish, foul smelling and occasionally blood-stained. He had no tinnitus, vertigo or facial weakness. Systemic review, and social history, were un-remarkable. Drug history revealed that he was on 1 antibiotics occasionally mainly as ear drops.

Physical examination showed that he was generally well, with stable vital signs. The left ear was normal. Examination of the right ear showed that the external auditory canal was full of blood-stained, whitish discharge.

The mastoid was widely open due to the disease process, with a lot of blood-stained whitish discharge. Seven living larvae were extracted under the operating microscope, in the clinic. (Fig. 1). The rest of ENT examination was normal. General systemic examination was also normal.

Investigations: Computerized tomography (CT) of the temporal bone showed the coalescence of the right mastoid cavity and the external auditory canal into one cavity due to the disease process. (Fig. 2).

The CT of the temporal bone also showed an eroded right mastoid bone with a fluid level within it and erosion of the posterior wall of external auditory meatus. There were no abnormal intracranial findings.

Pure Tone Audiometry (PTA) revealed moderate to severe conductive hearing loss at the right side with normal hearing being preserved on the left side.

Complete blood count (CBC), liver function tests (LFTs) and serum electrolytes, urea and creatine, were within normal limits.

The patient was admitted into the ward and operated upon three days later. At operation, there were small cavities within the mastoid air cells, lined by squamous epithelium and filled with thick yellowish fluid. No larvae were found. Evaluation of

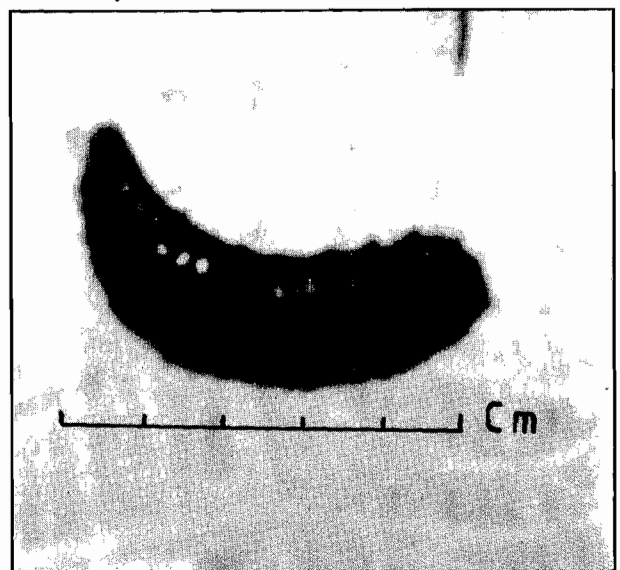


Fig. 1 *C.bezziana* larva, showing screw projections at its mouth part (spiracles). (Magnification x 3)

*Correspondence

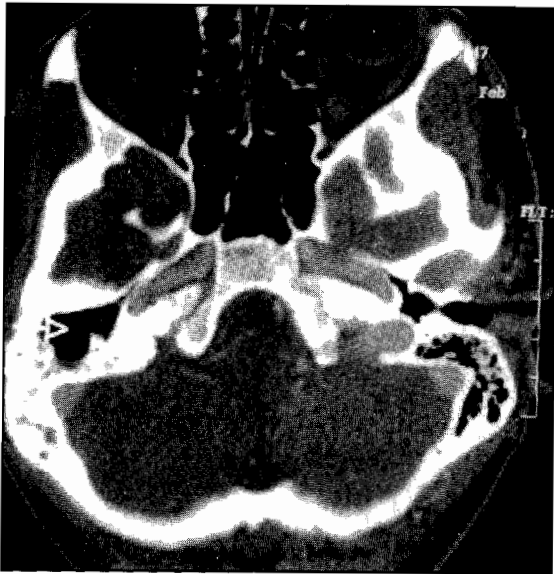


Fig. 2 CT scan of right mastoid bone with the arrow showing the right mastoid cavity with the air cells destroyed by the disease process.

the middle ear showed that the malleus and incus bones were severely eroded and the stapes was totally missing. The mastoid cavity was opened widely, cleaned and the remaining parts of the posterior canal wall were excised. Reconstruction of the ossicles was carried out.

Patient was discharged home two days after the operation on Cephalothin 500mg, tid. At follow up seven days later, the mastoid was clean. At the last follow up one month after the procedure, the patient was asymptomatic.

Discussion

There has been an increase in reported cases of myiasis in Saudi Arabia, although it does not constitute a serious public health problem in the kingdom.² Interestingly, most of the reported cases are from the Assir region situated in the south of the country at an elevation of 3000 meters above sea level.^{2,3} The majority of these cases were due to the larvae of *Cordylobia anthropophaga* and *Dermatobia hominis*. Some cases of ophthalmomyiasis caused by *Oestrus ovis*, the sheep botfly, have also been reported from other regions of Saudi Arabia.⁴⁻⁸ Myiasis caused by the old world screw worm, *Chrysomya bezziana*, is rare.^{9,10}

In each of the two reports of orbital and nasal myiasis from Saudi Arabia, *C. bezziana* was identified. Our report is the first documented case of mastoid cells myiasis caused by *C. bezziana* from Saudi Arabia.

The family *Calliphoridae* contains six metallic-coloured flies in the subfamily *Calliphorinae*, of which two species, the screw worms, have carnivorous larvae that are obligatory feeders on living flesh, and four that are essentially scavengers of decaying flesh.¹¹ The Old and New world screw worms are notorious parasites of domestic livestock, but humans are also frequently infected. The larvae attack open wounds on humans, feeding on living as well as dead tissue. They penetrate the tissue by using powerful oral hooks, hence the name 'screw worm'.¹² Our patient was a farmer and he probably got infected on his farm.

The flies that produce these larvae live and breed in warm, damp climates, such as are characteristically found in central and south America, Africa and parts of the Middle-East. It is

thought that the flies were imported first, into North Africa, and from there to the Middle-East, through the importation of cattle.¹¹ Global control of the adult flies are being pursued through the introduction of genetically-sterilized females into their population.¹¹ In addition, those working in vegetations where these flies are found should wear protective clothing and cover all abrasions and wounds.

Apart from being primary parasites of livestock, human beings who acquire the infection tend to be people with poor personal hygiene. The infection tends to be transient and less serious in those with good personal hygiene. In rare cases, these larvae have been found in the brain.¹²

This would probably have been the case in our patient, given more time because the CT scan of temporal bone showed eroded thin bone covering the brain tissue at the tegmen region.

Adult flies have been known to lay eggs on scabs, sores, scratches, pimples, or dried blood, on the healthy mucous membranes of the eyes, nose, mouth or vagina; and in the umbilicus of neonates.¹²

These varied manifestations therefore, constitute red alert for practicing physicians in the endemic zones to be on the look out for infections by these larvae, especially those working in agricultural and nomadic populations.

In the developed countries of Europe and America, these larvae are often put to good use in the form of Maggot Debridement Therapy (MDT) of chronic, fungating and dirty wounds, such as pressure ulcers, venous stasis ulcers, diabetic and neurovascular ulcers, and traumatic wounds.¹³ This may explain why our patient's wound was so clean that it required no pre-operative antibiotics. Research on this use of the larvae in developing countries, especially in Africa, where chronic ulcers abound, and the burden of antibiotic resistance is unbearable deserves particular attention.

Acknowledgement

We are grateful to Mr. ElHaj Abbas ElHaj, medical photographer, College of Medicine and Medical Sciences, King Khalid University, Abha, for the illustrations.

References

- Hall JRM. Introduction to myiasis: the entomological origins of larva therapy. Abstracts from the 1st World Conference on Biosurgery. 10th & 11th June, 1999. Grand Pavilion, Porthcawl, South Wales, U.K.
- Scrimgeour EM, El-Azazy OME. Significance of cutaneous and ophthalmic myiasis in Saudi Arabia. *Ann. Saudi Med.* 1995; 15: 295-6.
- Sundharam JA, Al-Gamal MN. Myiasis in Saudi Arabia. *Ann. Saudi Med.* 1994; 14: 352.
- Imam AN, Hassan MAM. Cutaneous myiasis. *Saudi Med. J.* 1990; 11: 252.
- Qadri SMH, Al-Ahdal MN. Cutaneous myiasis due to *Dermatobia hominis*. Report of a case. *Ann. Saudi Med.* 1988; 8: 286-7.
- Cameron JA, Shoukrey NM, Al-Garni AA. Conjunctival ophthalmomyiasis caused by the sheep nasal botfly (*Oestrus ovis*). *Am. J. Ophthalmol.* 1991; 112: 331-4.
- Omar MS, Das AB, Osman NI. External ophthalmic myiasis due to the sheep nostril botfly larva *Oestrus ovis* in Saudi Arabia. *Ann. Trop. Med. Parasitol.* 1988; 82: 221-8.

8. Torok PG, Davies DL, Roley E. Ophthalmomyiasis during Operation Desert Shield. *Military Med.* 1991; 156: 438-9.
9. Kersten RC, Shoukrey NM, Tabbara KF. Orbital myiasis. *Ophthalmol.* 1986; 93: 1228-32.
10. Ansari MA, Oertley RE. Nasal myiasis due to Bezzi's blow-fly (Screwworm): case report. *Saudi Med. J.* 1982; 3: 275-8.
11. Myiasis. In: *Tropical Medicine and Parasitology*. 5th ed. Wallace Peters & Geoffrey Pasvol. Eds. Mosby, Edinburgh-New York-Toronto. 2002, 269-74.
12. Medically important arthropods. In: *Diagnostic Medical Parasitology*. 3rd ed. Garcia LS & Bruckner DA. Eds. ASM Press, Washington DC, 1997, 523-63.
13. Sherman RA. Maggot therapy: the US experience. Abstracts from the 1st World Conference on Biosurgery. 10th & 11th June, 1999. Grand Pavilion, Porthcawl, South Wales, U.K.