

# Case report: intraocular cysticercosis

\*B. O. Adegbehingbe, E. O. Soetan and A. O. Adeoye

Department of Surgery,  
Obafemi Awolowo University Teaching Hospitals Complex,  
P.M.B. 5538, Ile-Ife, Osun State.

## Summary

A case of intravitreal cysticercosis causing left unio-ocular cataract and eventual left visual loss in a healthy female Nigerian is presented.

The diagnosis of *Cysticercus celulosae* was not made until the patient had left cataract extraction done.

The cysticercus larva found its way into the anterior chamber and this stimulated severe ocular inflammation.

The use of antihelminthic and systemic steroid caused amelioration of the patient's ocular inflammation and symptoms.

The review of literature on ocular involvement and the management of cysticercosis are discussed.

**Keywords:** Ocular cysticercosis, *Cysticercus cellulosae*, Vitrectomy in ocular surgery.

## Résumé

Il s'agit d'un cas de la cysticerose intravitrée provoquant la cataracte unioculaire du gauche et finalement une femme nigériane an bonne santé a perdu son oeil gauche. Le diagnostic de la cysticerose cellulose n'était pas effectué jusqu'au moment ou la patiente a subi l'extraction cataracte de son oiel gauche. La larve de la cysticerose trouve son chemin, dans la chambre antérieure et ceci a provoqué une inflammation oculaire grave.

L'utilisation de l'antihelminthique et le stréroide systémique provoquent une amélioration dans l'inflammation oculaire et symptômes de la patiente.

Nous faisons la cile bilan de la littérature sur la complexité oculaire et la prise en charge de la cysticerose.

## Introduction

Cysticercosis is an infestation of any tissue of the body with the larva form of the helminth *Cysticercus cellulosae*. This worm is commonly known as the "Tape Worm"

The two common types are the *Tinea solium* (pig's tape worm) and *Tinea saginata* (Beef Tapeworm).

After ingestion of undercooked meat from an infected host, the larva form of this worm can be lodged in any part of the body including the brain and skeletal muscles.

Ocular involvement of cysticercosis is not uncommon. The most common and severe ocular infections usually involve the posterior segment and these often lead to blindness and atrophy of the eye.

Prompt diagnosis of ocular cysticercosis and early treatment with the use of antihelminthic, systemic steroid and specialised eye surgery where indicated are essential.

We report a case of unioocular cataract which is caused by intraocular *Cysticercus cellulosae*.

## Case report

In May 2001, a 43-year-old female civil servant presented in a private eye hospital, in Ile-Ife with progressive loss

of vision in her left eye over the past 1½ years. There was no history of trauma. There was no other ocular symptom apart from gradual loss of vision. At presentation examination of the left eye revealed visual acuity of perception of light. The patient was found to have a unioocular left matured cataract for which she was listed for extracapsular cataract extraction with intraocular lens implantation.

The patient had no systemic problem and she was otherwise healthy. Social history revealed that she used to eat a lot of pork in the past but stopped a couple of years before this problem due to advice from neighbours.

Past ophthalmic history showed that the patient started using presbyopic spectacle correction when she was 40 years old.

After the removal of the cataract, the attending ophthalmologist (EOS) noticed a progressively expanding mass coming from behind the posterior capsule and pushing through the vitreous into the anterior chamber. Because of the transparent cystic nature of the mass the surgeon decided to leave it intact and no attempt was made at its removal.

The eye was closed and the patient was put on the following topical medications: Betametasone eye drops, gentamycin and atropine eye drops.

A week after surgery the visual acuity was no perception of light (NPL). She had moderate conjunctiva hyperaemia with a hazy cornea. Slit lamp examination post operatively revealed a transparent, whitish granular cystic ballon, the head (scolex) of the *Cysticercus cellulosae* with the hooks (about seven in number) hanging on the corneal endothelium. There was visible slow undulating movement within the body of cysticercus. About a week post operatively, the cornea was found to be hazy with a lot of endothelia dusting.

Blood investigation after surgery revealed, eosinophilia, erythrocyte sedimentation rate was 86mm per hour westergren.

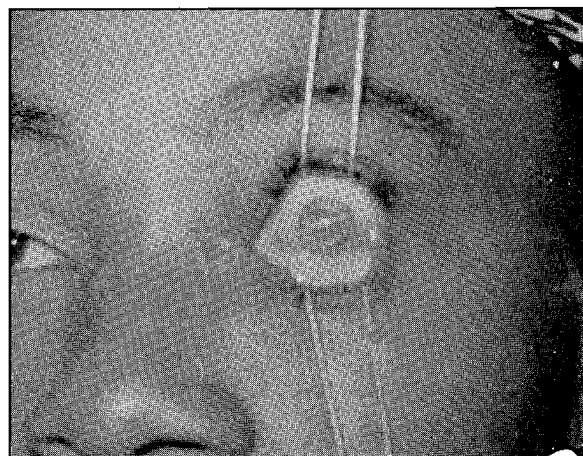


Fig. 1 A picture showing cysticercus in the anterior chamber of the patient's left eye.

\*Correspondence

The packed cell volume and white cell blood count were normal.

Ocular ultrasound scan revealed a Y shaped thick vitreal opacity extending across the vitreous chamber. There was an area of subtle posterior acoustic shadows which suggests areas of calcification in an aphakic eye.

The patient was placed on praziquantel tablets 200mg daily for two weeks and prednisolone tablet 10mg daily for two weeks. A week after medications were commenced, there was a noticeable shrinkage of the balloon with the loss of motility. She was to be reviewed later for surgical removal of the cysticercus but she was lost to follow up.

An informed consent was obtained before the clinical photograph of affected eye was taken for inclusion in the case report.

## Discussion

Cysticercosis is a parasitic infestation of different body organs by cysticercus cellulosae, a larval form of the helminth, *Taenia solium* commonly known as pork tapeworm. Ocular involvement of cysticercosis has been reported on several occasions. Parasitic infestation of other organs in the body include infestation of the central nervous system, subcutaneous tissue, skeletal muscles and heart muscle. The patient with ocular involvement may be symptomatic or may present with various degrees of visual loss or several other ocular signs and symptoms.

The most common and severe manifestations of ocular infection are secondary to posterior segment involvement which often leads to blindness and atrophy of the eye.

In the review of literature a case of acquired Brown syndrome caused by infestation of the superior oblique muscle by cysticercus cellulosae has been reported in India<sup>1</sup>.

Some other workers in India have reported the occurrence of optic nerve cysticercosis in the optic canal<sup>2</sup>. However, with the use of systemic steroids and albendazole in the prescribed doses for a month, the patient was symptomatically better with amelioration of the recurrent conjunctivitis and diplopia in primary gaze.

In another report, there was a successful removal of a subretinal cysticercus by pars plana vitrectomy<sup>3</sup>. This involved a 39-year-old woman who presented with recent visual loss in her left eye due to a subretinal cysticercus located near the macula. Pars plana vitrectomy with transretinal removal of the cysticercus is a useful alternative to the traditional external sclerotomy.

Also six cases of adnexal cysticercosis have been reported with one in the lacrimal gland, three in the orbital cavity and 2 in the palpebral tissue<sup>4</sup>. In the lacrimal gland, it presented as a painless, translucent cyst which closely simulated a simple dacryops. In the orbit, two of the cases presented as an acute abscess in the upper inner quadrant. Though one of these had existed as a case of simple ptosis for a period of 8 months. The third orbital involvement appeared as a painless cyst in the upper outer quadrant of the orbit.

Those in the lid presented, as either subcutaneous nodule or lodged in the orbicularis oculi muscle. The cysts were surgically removed in all cases and the diagnosis was confirmed by histological examination

In a related study<sup>5</sup>, experimental animal model for intravitreal cysticercosis using Newzealand rabbits and *Taenia crassiceps* cysticerci had been done.

This revealed an intense inflammatory reaction which led to severe ocular injury in the rabbits which did not receive any intramuscular dose of steroids prior to inoculation of parasites, while there was only a mild inflammatory infiltrate limited to the area of direct contact with the parasite in those that had preinoculation steroid treatment.

The intravitreal presentation of the larva in our patient's eye can be assumed responsible for the development of her uniocular cataract.

While evaluating the management of our patient, one would have preferred to perform pars plana vitrectomy during the primary cataract extraction surgery when the cysticercus was first noticed if the facilities were available. In a retrospective study of five cases of intraocular, cysticercosis seen at an institute in India, pars plana vitreous surgery for complete removal of intact cyst was done in all cases. This resulted in good functional recovery in the eyes with intraocular cysticercosis<sup>6</sup>. However, with the closure of the wound and commencement of systemic steroid and antihelminthic drug, praziquantel in the recommended dose it was expected that there will be less inflammatory reaction during any further operative procedure this patient may undergo for removal of the larva.

The patient did not turn up for follow-up till the time of report of this case.

## Conclusion

Late presentation for proper eye examination and treatment by a trained eye specialist is a big problem to early diagnosis and treatment in most ophthalmic conditions in our society. Based on the good results obtained with the previous reported cases in other centers worldwide, prompt diagnosis and referral to a vitreoretinal surgeon was essential for the successful treatment of this condition.

The role of Health education on ingestion of undercooked pork and careless handling of animal droppings cannot be over emphasized.

There is a need to enforce regular deworming of pigs, cats and other animal sources which can serve as a reservoir for cysticercus or any other worm infestation.

## References

1. Parely PK, Chaudhuri Z, Bhatia A. Extra ocular muscle cysticercosis presenting as Brown syndrome. *Am J Ophthalmol* 2001; 131: 526 – 7.
2. Gurta N, Sood A, Dhar J, Gupta S. Optic nerve cysticercosis in the optic canal. *Acta Ophthalmol. Scand* 1999; 77: 107 – 9.
3. Stainmetz RL, Masket S, Sidikara R. The successful removal of a subretinal cysticercus by pars plana vitrectomy. *Optom Vis Sci.* 78: 188094.
4. Sen DK. Cysticercus cellulosae in the lacrimal gland, orbit and eyelid. *J Med. Assoc. Thai* 1999; 74: 641 –52.
5. Santos A et al. Experimental intravitreal Cysticercosis. *Graefes Arch. Clin Exp. Ophthalmol.* 234: 515 – 20.
6. Natarajan S, Malpani A, Kumar Nimalan P, Dutta B. Management of intraocular cysticercosis. *Graefes Arch Clin & Exper. ophthalmol* 1999; 237: 812 – 4.