

Reduced liquor drainage at delivery: an unusual presentation of uterine rupture

E. I. Archibong* and S. J. Etuk**

*Abha Maternity Hospital, Abha, Saudi Arabia.

**Maternity Annex, University of Calabar Teaching Hospital, Calabar, Nigeria.

Summary

A 27-year old unbooked G₅P₃+1 woman with a history of previous caesarean section is reported. She had an apparent normal vaginal delivery at term with very scanty liquor drainage. She then developed severe persistent abdominal pain with stable vital signs. A laparotomy confirmed a ruptured uterus. We therefore conclude that any woman with a scarred uterus presenting with very scanty liquor drainage at delivery, if she develops persistent abdominal pain, should raise a suspicion of uterine rupture.

Keywords: Scarred uterus, Reduced liquor drainage, Persistent abdominal pain, Uterine rupture.

Résumé

Il s'agit d'un rapport d'une femme avec G₅P₃+1 âgée de 27 ans qui n'a pas fait son inscription dans l'hôpital mais avec une histoire de la césarienne. Apparemment, elle avait un accouchement vaginal normal suivi par un très peu de drainage d'eau. Puis, elle est atteinte d'une douleur abdominale grave et continue avec des signes de vie stables.

A travers la laparotomie, on a pu confirmer un utérus hernié. Don, de ceci, nous concluons que n'importe quelle femme avec un utérus apeuré et qui a un tout petit peu du drainage d'eau pendant accouchement et si elle est atteinte d'une douleur abdominale continue, d'évrait éveiller des soupçons d'un utérus hernié.

Introduction

Uterine rupture is one of the most dangerous complications of pregnancy and labour particularly in the developing world. It is associated with high maternal and fetal mortality^{1,2}. The prospect for survival of patients with ruptured uterus depends on the time interval between the rupture and the initiation of effective treatment³. Hence, the diagnosis of this life-threatening condition should be made early and immediate resuscitation initiated. This calls for a high index of suspicion in all who attend to women in pregnancy, labour and delivery.

The usual clinical presentation of ruptured uterus is not strange to most obstetricians particularly in the developing countries, where it is common. Occasionally some cases present in an unusual manner. To strengthen our index of suspicion and hence help early diagnosis and management of this condition in order to prevent the high maternal and fetal mortality associated with it, these unusual presentations need to be made known to all.

Case report

A 27-year-old unbooked patient was admitted at 38 weeks gestation in established labour. This was her fifth pregnancy, following a spontaneous abortion, a lower segment caesarean section at term due to transverse lie and two normal deliveries at term. Her general condition was satisfactory on admission. She

had a pulse rate of 80 beats per minute and blood pressure of 130/80mmHg. Her abdomen was soft, non-tender and her uterine size was compatible with 38 weeks gestation, with a longitudinal lie of the fetus and cephalic presentation. Her cervix was fully effaced, soft, central, 4cm dilated and well applied to the presenting part at 1cm above the level of the ischial spines, with intact membranes. Artificial rupture of fetal membranes was performed but no liquor was obtained. She had a spontaneous vaginal delivery of a 3.0kg baby within 4 hours of admission with very minimal drainage of liquor.

Following delivery, the patient had severe right-sided loin pain radiating to the posterior aspect of her right thigh. The

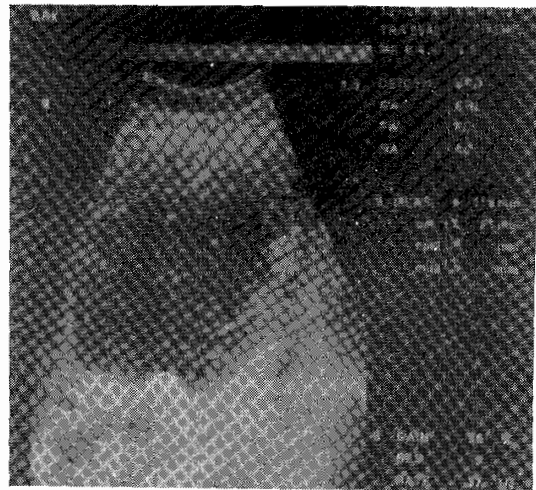


Fig. 1 Abdominal ultrasound showing a huge mass on the right side of the uterus.

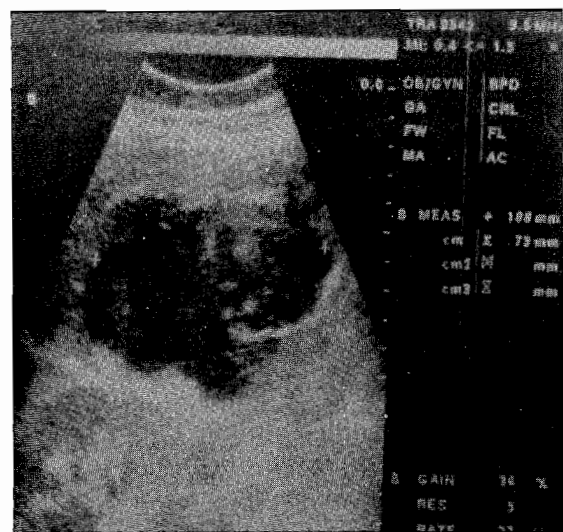


Fig. 2 Mass on the right side of the uterus showing sonolucent fluid with minimal echogenic spot.

*Correspondence

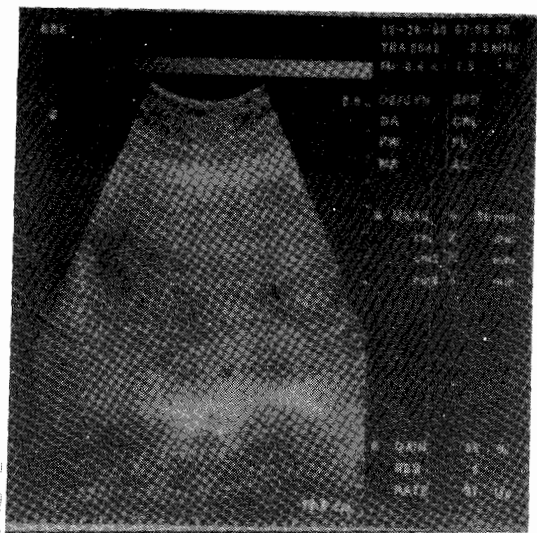


Fig. 3 Abdominal ultrasound showing an empty uterus.

severity of the pain increased with time. Her right lumbar region was very tender. Abdominal ultrasound revealed a huge mass on the right side of her uterus, extending to the level of the fundus, measuring 11.0cm x 7.5cm x 9.1cm (Fig. 1). It was full of sonolucent fluid with minimal echogenic spots inside (Fig. 2). There were incomplete trabeculae inside. The uterus appeared empty (Fig. 3). There was no free fluid in the peritoneal cavity. The patient's condition was stable at this stage (2 hours post delivery), with a pulse rate of 78 beats per minute and blood pressure of 120/80mmHg. Possible incomplete uterine rupture with right broad ligament haematoma was suspected.

Laparotomy performed revealed no free fluid in the peritoneal cavity. The uterovesical fold of peritoneum was oedematous while the right broad ligament was enlarged, oedematous and also tense. A transverse incision through the utero-vesical peritoneum revealed a transverse uterine scar rupture of about 8cm long, with fresh edges. Her urinary bladder was intact. Incision of the anterior peritoneal fold of the right broad ligament led to the drainage of about 600mls of liquor with particles of vernix caseosa. The uterus was repaired in two layers and the peritoneal cavity was drained. Her post-operative recovery was uneventful.

Discussion

Although uterine rupture is more common in the developing countries because of ignorance, poverty and inadequate health facilities, it is still a global problem. Along with placenta accreta and placenta praevia with accompanying haemorrhage, they constitute some of the serious complications associated with delivery after one or more previous caesarean section⁴. Our patient had two uneventful deliveries following caesarean section for non-recurrent indication. The birth weight of the baby in this index pregnancy was not more than that of the previous

delivery at term.

Meta-analysis of cases of trial of labour after caesarean section in sub-Saharan Africa revealed a success rate comparable to that observed in developed countries⁵. Some authors found successful trial of labour in patients with previous caesarean section scar in 63.3% of patients with recurrent indication and 73.4% with non-recurrent indication⁶. These point to the fact that a trial of labour in patients with previous caesarean section scar is safe, provided that obvious disproportion and malpresentation are excluded as in this case. Our patient did not have abnormal vaginal bleeding following delivery and her vital signs were normal and stable. The severe discomfort she experienced following delivery and the presence of a tender para uterine mass called for laparotomy. A primary uterine repair of the scar rupture was performed. Hysterectomy is more commonly performed with rupture of the scarred one⁷.

The unusual presentation of uterine rupture in this patient probably lies on the fact that the membranes may have ruptured through the dehiscence scar and the liquor drained into the broad ligament, to set up a painful inflammatory reaction and swelling. Very scanty liquor was obtained following the delivery of the baby.

In conclusion, a high index of suspicion is very important in order to avoid missing uterine rupture, when a patient with previous caesarean section presents with persistent severe abdominal pains, with or without abnormal vaginal bleeding following a normal delivery. This index of suspicion becomes higher if there is associated reduced liquor drainage at delivery as shown by this patient.

References

1. Wright EA. Rupture of the gravid uterus at the University College Hospital, Ibadan, Nigeria. *Trop J Obstet Gynaecol* 1984; 4: 47 – 50.
2. Ghatak DP. Rupture of the uterus. A review of 146 cases. *Trop J Obstet Gynaecol* 1990; 8: 41 – 44.
3. Ayangada O. Rupture of the uterus. A 10-year review. *Trop J Obstet Gynaecol* 1990; 8: 25 – 27.
4. Chazotte C, Cohen WR. Catastrophic complications of previous caesarean section. *Am J Obstet Gynaecol* 1990; 163: 738 – 742.
5. Boulvain M, Fraser WD, Brisson-Carroll G, Wollast E. Trial of labour after caesarean section in sub-Saharan Africa: a meta-analysis. *Br J Obstet Gynaecol* 1997; 104: 1385 – 1390.
6. Chua S, Arulkumaran S, Singh P, Ratman SS. Trial of labour after previous caesarean section: obstetric outcome. *Aust NZJ Obstet Gynaecol* 1989; 29: 12 – 27.
7. Flannelly GM, Turner MJ, Rassmussen MJ, Stronge JM. Rupture of the uterus in Dublin: an update. *J Obstet Gynaecol* 1993; 13: 440 – 443.