

# Giant frontal sinus mucocoele with intracranial extension and orbital displacement in an elderly Nigerian

F. O. Arole<sup>1</sup>, A. A. Olaitan<sup>2</sup> and \*O. A. Fatusi

\*Department of Oral and Maxillofacial Surgery, College of Health Sciences, Obafemi Awolowo University, Ile-Ife, <sup>1</sup>Postgraduate Residency Programme Training Unit, General Hospital, Ikeja, Lagos and <sup>2</sup>Maxillofacial Unit, Kaduna, Nigeria

## Summary

Mucocoele of the frontal sinus presents with initial sign of forehead swelling in about 10% of cases, and cases with huge intracranial extension have been reported to be rare. We present a case of a giant frontal sinus mucocoele with intra-cranial and intra-orbital extensions exerting a mass effect on the anterior cranial fossa in a 78 year old Nigerian female with resultant forehead swelling, proptosis and total blindness of the left eye. Diagnosis was made on clinical and radiological basis, and enucleation using coronal flap approach was done. Immediate repair of the resultant frontal bone defect was effected through the use of a curved 0.5mm stainless steel wire fixed in 3 layers across the defective frontal bone over which the soft tissues of the forehead were undermined for primary closure on sound bone. This approach was considered more appropriate than a split rib graft in view of the patient's age. No evidence of recurrence was recorded during a one-year post-surgery follow-up, suggesting that mucocoele, regardless of size can be treated with conservative surgical approach provided all cystic lining and mucocoele are removed.

**Key words:** *Frontal sinus, Mucocoele diagnosis, Mucocoele complications, Surgical flaps, Aged.*

## Résumé

La mucocoele du sinus frontal a montré les signes du début à l'égard de l'enflure au front chez environ 10% des cas, et on a remarqué que les cas avec une grande extension intracranie étaient rares.

Nous présentons un cas d'une mucocoele sinus frontale énorme avec les extensions intra-crâniennes intra-orbitales qui exerce l'influence de sa pression sur le crânien antérieur fossa chez une femme nigérienne âgée de 78 ans avec le résultat l'enflure au front, proptosis et aveuglement total dans l'œil gauche. On avait fait la diagnose à travers les méthodes cliniques, radiologique et enucleation tout en utilisant la démarche coronal flap. On avait opéré tout de suite un défaut surgissant à partir d'os frontal à l'aide d'un acier métallique d'une longueur de 0,5mm courbé et attaché en trois couches en travers l'os infecté, l'os frontal par-dessus lequel on avait traité les tissus mous du front à travers l'occlusion primaire sur la sonde d'os (sound bone). Cette démarche est très efficace au lieu de split rib graft, la greffe de la côte gerçure, en considération de l'âge du malade.

On n'a pas noté aucune marque de la récurrence pendant la durée d'une année postopératoire c-à-d soins post-hospitaliers.

Par suite, on peut dire que la mucocoeles, sans se soucier des grandeurs, pourrait se soigner à travers la méthode chirurgicale préservative pourvu que tous les mucocoeles et les cystites ganglionnaires aient enlevé.

## Introduction

Mucocoeles are cystic bony expansions of the paranasal sinuses, which contain mucoid, and epithelial debris as a result of obstruction of normal drainage through ostia<sup>1</sup>. These arise in the frontal, ethmoidal, or sphenoidal sinuses and present clinically as effects of mass lesion. These lesions are low reflective, non-

vascular and are very well outlined. Mucocoeles have a very firm consistency and may cause indentation of the eyeball. They are always associated with a large bony defect through which the lesion extends from the sinus into the orbit<sup>2,3,4</sup>. The contents of the mucocoele may be thin serous fluid, thick mucoid material, and at times, caseous material that justifies the term "sinusitis caseosa". When the contents are drained, they are almost always sterile. Thick chocolate brown material is found if haemorrhage has occurred, cholesterol crystals in the degenerating contents of the mucocoele may also be seen. The term suppurating mucocoele or pyocoele is used when the contents of the cavity are purulent as a result of infection due to either repeated incisional or aspiration biopsies.

Mucocoele of the frontal sinus can be defined as the accumulation and retention of mucous secretion within the sinus owing to obstruction of its outlet with thinning and possible distention of one or more of the walls of the sinus. The condition can either be primary or secondary in nature. The primary mucocoele is said to arise as a cyst from goblet gland, which grows to such an extent as to expand the sinus. The secondary type is due to outlet obstruction<sup>4</sup>. The three most important causes of outlet obstruction resulting in the formation of a frontal sinus mucocoele are inflammatory changes in the fronto-nasal duct, external trauma to the frontal sinus and growth such as osteoma in the region of the fronto-nasal duct<sup>4</sup>. Other causes of fronto-nasal duct obstruction include allergy, polyposis, tumour metastasis, sudden barometric pressure changes and neuro-surgical procedures involving the frontal sinus<sup>4</sup>. Irrespective of its cause, untreated frontal sinus mucocoele has the tendency to grow bigger and extend both intracranially and intra-orbitally. Giant cases of frontal mucocoeles are rare<sup>5</sup> and as recorded in our case, do present with complications such as orbital displacement, proptosis and eventual blindness of the affected eye.

## Case report

A 78-year old Nigerian woman presented with a 15 year history of gradually increasing, painless swelling in the frontal bone region. Examination revealed a non-tender, fluctuant swelling bulging forward beyond the bridge of the nose (Fig 1). Proptosis with loss of vision on the left eye was also recorded. Aspiration biopsy revealed a thick black-greenish fluid. Radiographic examination showed a large radiolucent area in the frontal sinus with destruction of the frontal bone (Fig 2). Baseline haematological investigations were essentially within normal limits. Based on the foregoing, a diagnosis of frontal mucocoele was made. The patient was admitted for surgery and under naso-endotracheal intubation, a bicoronal flap was raised to expose the lesion and its intra-cranial extension. The thick cystic lining of the mucocoele together with its contents were completely removed and the left eyeball was also enucleated. Consequently, there was immediate collapse of the soft tissue overlying the defect. The resorbed frontal bone was reconstructed with 0.5mm gauge stainless steel wire curved, shaped and fixed into three holes drilled on each side of the remnant of the frontal bone. Thus, the three rows of the wire overlay the resorbed frontal bone and it was over these that the soft tissues were stretched to achieve primary closure on a sound bone. Vacuum drainage was inserted for 72 hours. The patient was placed on

\*Correspondence

amoxicillin capsule 500mg 8hrly for 7 days and ibuprofen tablet 400mg 12hrly for 3 days. Healing was uneventful and the patient was discharged home after 14 days. Follow-up appointments were fixed at three monthly interval and no complication was recorded during the first post-operative year. The patient was, however, lost to follow-up after the first year.

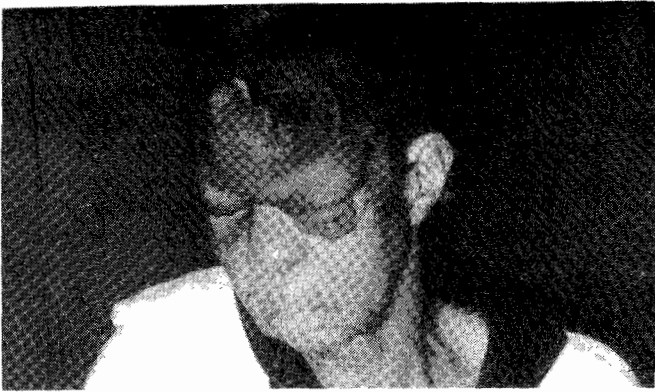

Fig. 1 Giant frontal sinus mucocoele with orbital displacement. Note the collapsed frontal swelling after spontaneous rupture.

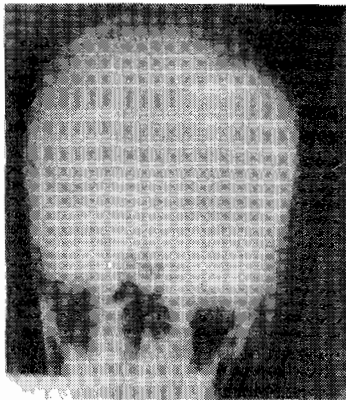


Fig. 2 Posterior anterior radiograph of the skull showing intracranial extension as a radio-opaque area.

## Discussion

The frontal and ethmoidal sinuses are the most common sites for the development of mucocoele. The condition occurs when the drainage from a sinus is blocked by obstruction of its ostium, usually from inflammation. Long standing sinusitis may be a predisposing factor, but it is not always elicited in all patients with mucocoeles. Other possible causes of osteal obstruction are osteomas, fractures, polyps, scarring, congenitally narrow ostium, nasal septum deviation and obstruction of the mucous glands of the sinus, which leads to their dilatation with the accumulation of inflammatory material or blood in the submucosa of the sinus lining. The stenosis of the ostium is most likely to occur in the frontal sinus where the narrow duct, approximately 2mm wide, passes for a distance of 5-10mm through the ethmoid bone in close relationship to the anterior ethmoidal sinus<sup>6</sup>. Once blockage of the ostium is established, pressure develops within the involved sinus. A slow expansion of the sinus space, thinning and erosion of the bone and displacement of the bone together with encroachment of the mucocoele on contiguous structures such as the cranial nerves, the extra-ocular muscles, and the optic nerve occurs thereafter. As the sinus expands with pressure, erosion of the bony walls occurs and the thinnest section - the orbital wall of the horizontal part will most often in 90% of cases give way first and the mucocoele will continue to expand into the orbit<sup>6</sup>. The displaced bone may produce new bone. In 10 percent of cases of frontal sinus mucocoeles the anterior wall will erode first and the swelling appear on the

forehead as recorded in the present case.

Frontal sinus mucocoeles can cause enlargement of the forehead and downward displacement of the eye, whereas ethmoidal mucocoeles can cause lateral displacement of the eye<sup>7</sup>. A frontal mucocoele usually presents under the anterior orbital rim and displaces the eye downward and outward rather than forward. Diplopia on extremes of the lateral gaze is an indication of extra-ocular imbalance from the enlarging mucocoele. The posterior frontal mucocoele, another variant, expands posteriorly towards the optic foramen instead of under the orbital rim and the picture may elude detection of the only signs which are those of frontal lobe compression. On palpation, there may be a crepitant feel, due to the thin underlying "egg-shell" bone. The swelling is usually painless and spongy.

Radiological examinations are the standard diagnostic procedures. Dural involvement and intracranial extension of the mucocoele can be diagnosed pre-operatively by occipitomental view of the skull and by lateral skull tomography to show the lateral wall of the frontal sinus. When available, CT scan also give valuable information regarding intracranial extension<sup>8</sup>. Mucocoele may demonstrate a hypointense or hyperintense signal on magnetic resonance imaging, depending on the concentration of proteinaceous or inflammatory fluid components. Although the walls are well delineated, the integrity of the expanded bony walls of the sinus cavities cannot be assessed as well as by CT scan<sup>9,10</sup>. A pathognomonic diagnostic finding is emphysema around the eye when the patient sneezes, as a result of the bursting of the wall of the partially aerated mucocoele. Such a development leads to an acute inflammatory response, because of the release of irritating, degenerating and cholesterol material contained within the sinus. Perhaps the most difficult cystic tumours to distinguish from mucocoeles are dermoids and epidermoids that occur within the bones of the orbit and sinuses<sup>11,12</sup>. Dermoids usually occur at the suture lines of bones, but they may occur deep in the orbit and in the greater and lesser wings of the sphenoid. In the case of dermoids, x-rays will reveal expansion of the inner and outer tables of the diploic bone without concomitant enlargement or dissolution of the sinus.

Surgical treatment entails stripping the mucosa from the sinus wall to prevent recurrence, and packing the sinus. Several controversies still exist regarding the surgical approach used in the management of paranasal sinus mucocoeles<sup>13</sup>. However, osteoplastic flap of the frontal sinus, described by Macbeth over 40 years ago, is still the best surgical approach for the diagnosis and definitive treatment of the disease<sup>14</sup>. It is indicated for complete removal of mucous membrane and sinus obliteration. The surgical approach can be coronal, brow, or hermicoronal. Other approaches that have been associated are lateral rhinotomy, sublabial and intranasal<sup>14</sup>. Complications of the surgical management may include dural tears with leakage of cerebrospinal fluid (intra-operatively), frontal deformity, persistent frontal anaesthesia and supraorbital nerve neuralgia (postoperatively). The coronal incision has proved to be the principal surgical approach to the frontal region of the head. As evidenced in the management of our case, it gives a wide operation view and allows for a well-hidden scar<sup>15</sup>. Except where there is an evidence of an extension intracranially the incision line can be placed a few centimetres above the frontal sinus: incision line in the creases of the forehead generally gives an excellent cosmetic result. Possible disadvantages of this approach include the long distance that may be involved between the incision line and the location of the lesion, and possibility of severe haemorrhage. Numbness of the forehead and formation of a large keloid in patients who are prone to keloid formation may also occur. The midforehead incision, described as brow-lift in the literature, is a cosmetically acceptable alternative to the coronal incision for patients with forehead wrinkles or who are at risk for male pattern baldness. The use of a midforehead approach has been advocated in patients

with hairline recession and elderly or infirmed patients who can not tolerate prolonged procedures or significant blood loss<sup>15</sup>.

The use of endoscopic sinus for marsupialisation and drainage in the management of mucocoeles of the paranasal sinuses is receiving increasing attention in the literature<sup>16-19</sup>. Although some aspects of endoscopic sinus remain controversial and are poorly understood<sup>16</sup>, it is generally viewed as a safe and reliable approach, which obviates, the need for major cranial surgery and reduces post-operative morbidity<sup>17-19</sup>. Close follow-up is however required and secondary decompression can be carried out in cases of recurrence.

The use of methyl methacrylate and wire mesh for the repair of frontal bone defect in surgical management of frontal sinus mucocoele has been documented<sup>20</sup>. In our case, the immediate reconstruction of the frontal bone defect was carried out using a curved 0.5mm stainless steel wire fixed across the defect in three rows over which the soft tissues of the forehead were stretched. This approach enabled us to avoid the alternative of a split rib graft that could have given additional discomfort to our aged patient. The use of ionomer-based cement, a new bone replacement material (Ionocap®) as bonding material for certain complicated frontal sinus diseases requiring osteoplastic surgery has recently been reported by Weber and colleague<sup>21</sup>. In comparison with the use of metal osteosynthesis, they reported that the use of bone cement was easier, faster and achieves, at least, equivalent functional stability, and improved cosmetic outcome. No case of rejection of osteonecrosis of the material was recorded. Based on this result, Weber and his team recommend the use of ionomer-based cement, but caution that the guidelines of the supplier are 10 years strictly followed<sup>21</sup>.

Failure to ensure complete removal of the lining of the mucocoele during surgery could lead to recurrence after 5 – 10 years. A long-term follow-up is also necessary to determine the benign nature or otherwise of fronto-ethmoidal sinus mucocoele particularly those of long standing duration of say, 35-40 years. However, once the surgery has been performed and all the symptoms disappear, patients are often loss to follow-up. Reasons for this in our environment include ignorance, economic burden of transportation, hospital consultation, movement to other locations and death from other causes. Thus, in a developing country like Nigeria, long-term follow-up of mucocoele patients is a very great challenge that may not be easily surmounted.

### Conclusion

Untreated frontal sinus mucocoele will grow extensively to involve the anterior intracranial fossa and exert pressures on neighbouring tissues and organs to cause such complications as orbital displacement and blindness of the affected eye. The goals of the treatment of frontal sinus mucocoeles are the relief of symptoms due to compression and the prevention of recurrence through surgical management. As mucocoeles are largely benign in nature, it is advisable to choose a surgical approach that minimises the surgical trauma<sup>22</sup>. From our experience, a bicoronal flap presents an optimal surgical approach to the giant lesion as it gives excellent visibility and access.

Collapse of the soft tissues of the forehead after enucleation in a 78-year-old patient is a big problem. Secondary reconstruction of the defect of the frontal bone with a split rib graft is usually not acceptable by old patients and gives additional discomfort, which may be best avoided. We were able to solve this problem by using curved 0.5mm stainless steel wire fixed across the frontal bone defect in three rows over which the soft tissues of the forehead were stretched to allow primary closure on a sound bone after trimming off the excess soft tissues. The curved ends of the wire terminated inside the anterior intracranial fossa through the holes drilled on either side of the remnant of the frontal bone. This procedure from our experience gives no discomfort to the patient

and is well tolerated. For the one-year period that the patient reported for follow-up, before she eventually defaulted, no complication was recorded.

### References

1. Glaser JS. Topical Diagnosis: Prechiasmal visual pathways: Duane's Clinical Ophthalmology. Revised edition. J.B. Lippincott, Philadelphia: 1991 (2) 5: 66.
2. Byrne SF and Green RL. Ultrasound of the orbit: Duane's clinical ophthalmology. revised edition. J.B. Lippincott, Philadelphia: 1991 (2) 26: 33.
3. Adekeye EO and Ord RA. Giant frontal mucocoele. Report of two cases. J Max Fac Surg. 1984; 12: 184 - 88.
4. Howart WG. Mucocoele and pyocoele of the nasal accessory sinus. Lancet. 1921; 2: 744-46.
5. Nakayama T, Mori K and Maeda M. Giant pyocoele in the anterior intracranial fossa-case report. Neurol Med Chir Tokyo. 1998; 38: 499-502.
6. Pickard BH. The conditions of sinusitis: Otolaryngology. 5<sup>th</sup> edition. Butterworth & Co, London: 1987 pp. 203-07.
7. Jones IS, Jakobiec FA and Nolan BT. Patient Examination and introduction to orbital disease: Duane's Clinical Ophthalmology. Revised edition. J. B. Lippincott, Philadelphia: 1991; (2) 21:4.
8. Lannetti G, Gascone P, Valentini V and Agrillo A. Paranasal sinus mucocoele. Diagnosis and treatment. J Craniofacial Surg. 1997; 8: 391-98
9. Price HI and Danziger H. Computerised tomographic findings in mucocoele of the frontal and ethmoidal sinuses. Clin Radiol. 1980; 31: 169-72.
10. Tassel PV, Lee Y, Jing B et al. Mucocoeles of the paranasal sinuses. MR imaging with CT correlations. AJNR. 1989; 10:607.
11. Mortada A. Dermoid cyst of great wing of sphenoid bone. Br J Ophthalmol. 1970; 54:131.
12. Cullen JF. Orbital diplopic dermoids. Br J Ophthalmol. 1974; 58:105.
13. Gararenta G, Arcuri T, Schiavoni S and Fonzari M. Anterior clinical mucocoele: a trans-nasal endoscopic approach. Minim Invasive Neurosurg. 1997; 40: 144-47.
14. Bertran-Mendizabal JM, Perez- Martinez C and Murtinel- Vidal A. Osteoplastic frontal sinus flap. Study of 47 cases. Acta otorrinolaringol esp. 1998; 49: 380-84.
15. Cheney ML, Gliklich R, Li KK, Topf P and Montgomery W. Midforehead incision: an approach to the frontal sinus and upper face. J Craniofac Surg. 1995; 6: 408-11.
16. Kennedy DW and Senior BA. Endoscopic sinus surgery. A review. Otolaryngol Clin North Am. 1997; 30: 13-30.
17. Sillers MJ and Page EL. Endoscopic surgery of the frontal sinus. Clin Plast Surg. 1995; 22: 785-90.
18. Benninger MS and Marks S. The endoscopic management of sphenoid and ethmoid mucocoeles with orbital and intranasal extension. Rhinology. 1995; 33: 157-61.
19. Har-El G and Lucente FE. Endoscopic intranasal frontal sinusotomy. Laryngoscope. 1995; 105: 440-43.
20. Smoot EC III, Bowen DG, Lappert P and Ruiz JA. Delayed development of an ectopic frontal sinus mucocoele after paediatric cranial trauma. J Craniofac Surg. 1995; 6: 37-31.