

# Hydrocephalus, Ventriculo-Peritoneal shunt and Cerebrospinal fluid ascites.

\* O. P. Binitie<sup>1</sup>, S. A. Abdul-Azeim<sup>1</sup> and S. H. Annobil<sup>2</sup>

<sup>1</sup> Department of Neurosurgery, Assir Central Hospital, P. O. Box 34, Abha, Saudi Arabia; and

<sup>2</sup> Department of Child Health, King Khalid College of Medicine, Abha, Saudi Arabia.  
P. O. Box 34, Abha, Saudi Arabia.

## Summary

A small number of patients with congenital hydrocephalus, who have been treated effectively with ventriculoperitoneal shunts, develop progressive increase in abdominal girth, due to cerebrospinal fluid ascites. This abdominal distension can produce respiratory difficulties that require endotracheal intubation and ventilator support. The respiratory difficulties and the abdominal distension were eliminated when the ventriculoperitoneal shunt was converted to a ventriculoatrial shunt in each of the three cases presented in this paper for discussion.

**Keywords:** *Hydrocephalus, Ventriculoperitoneal (vp) shunt, Cerebrospinal fluid (CSF) ascites, Ventriculoatrial (VA) shunt.*

## Résumé

Un petit nombre de patients, avec congenital hydrocephale, qui ont été traités avec succès par shunts ventriculo-péritoneal, développement une augmentation progressive de la sangle abdominale, due à la formation d'ascite par le liquide céphalo-rachidien. Cette distension abdominale peut produire des difficultés respiratoires nécessitant une intubation endotrachéale avec ventilation. Les difficultés respiratoires et la distension abdominale ont été corrigées par le remplacement du shunt ventriculo-péritoneal par un shunt auriculo-ventriculaire dans chacun des trois cas présentés dans la discussion.

## Introduction

Patients with congenital hydrocephalus are usually effectively treated using a CSF shunt diversion technique. Insertion of a ventriculoperitoneal shunt remains one of the most commonly used neurosurgical techniques for treating hydrocephalus<sup>1,2</sup>. A small number of these patients however, fail to respond to this CSF diversion method because of overproduction of cerebrospinal fluid or impaired ability of the peritoneum to absorb the CSF<sup>3</sup>. The latter results in excessive accumulation of CSF in the peritoneal cavity, eventually producing ascites, and gross abdominal distension with concomitant respiratory distress. Previous shunt infections may be responsible for the reduced capacity of the peritoneum to absorb fluid. The accumulation of protein-rich CSF in the peritoneal cavity produces a reversed osmotic gradient with the hypo-osmolar plasma and further aggravates the ascites.<sup>4</sup>

## Case 1

A 5-month-old male Saudi infant developed a fever, opisthotonus, flaccid paraplegia and blood in the ventricular CSF, for which neurosurgical consultation was sought, in Assir Central Hospital, (ACH) Abha, Saudi Arabia. Relevant positive findings included CT and MR brain scans. These showed intraventricular haemorrhage and multiple small-scattered hyperdense lesions in the brain. MRI of the spinal cord showed an anteriorly located intramedullary serpiginous hyperintense arteriovenous malformation of the cord at C2 and at C7-T1 levels. Patient had to be ventilated because he could not maintain satisfactory blood gases levels. Repeated ventricular aspirations cleared the CSF of blood. This was confirmed by serial follow up CT brain scans, which in addition showed progressive ventriculomegaly coupled with periventricular lucency. A low-pressure right VP shunt was duly

inserted and this dealt with the hydrocephalus. Over the next 10 days, the abdomen was noted to progressively increase in girth with concomitant respiratory distress. The ventriculoperitoneal shunt was then converted into a ventriculoatrial shunt. This successfully relieved the respiratory distress and abdominal distention.

Unfortunately at the age of 16 months, patient succumbed to candida septicemia, due to a huge fungal growth on the tricuspid valve. He died one month later in spite of appropriate care and antifungal treatment.

## Case 2

A 2-year-old Yemeni girl with congenital hydrocephalus for which a left sided VP shunt was inserted in another hospital, shortly after birth, presented to the Emergency room of A. C. H., with inflammation of the shunt track. The left VP shunt was removed.

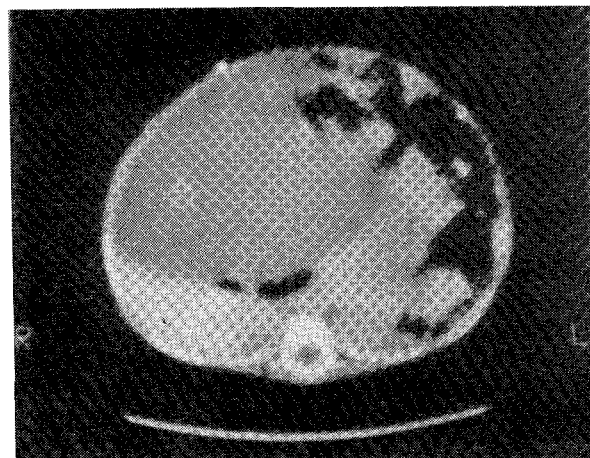


Fig. 1 Abdominal CT scan showing the distended abdomen with CSF displacing the bowel to the left. Hounsfield units of CT measurements: (1) Liver 73.5 SD = 5.4(2) CSF 17.9 SD = 4.6

There was no bacterial growth from the shunt tips and the CSF, as patient had a full course of antibiotics in another hospital before she was referred to A.C.H. A right VP shunt with a low-pressure valve was subsequently inserted in the operating room under general anesthesia. Patient had an uneventful postoperative period and was discharged home to out patient neurosurgical follow up. Over a period of two months at home, the parents observed a progressive increase in abdominal girth. When breathing became very difficult and the child could not take much food orally, the child was brought to the Emergency room. Physical examination showed an afebrile, dyspnoeic child, with stable vital signs, gross abdominal distension and a functioning right VP shunt. CT scan of the abdomen confirmed CSF ascites. This abdominal distension cleared up when the right VP shunt was converted into a right VA shunt in the operating room, under general anesthesia. Post operatively, she was able to breathe normally and improved. She was discharged home to out patient neurosurgical follow up.

## Case 3

A 10-month-old Saudi male infant, born with a large head, which was increasing in size, had a CT brain scan done. This demonstrated congenital communicating hydrocephalus, for which

\* Correspondence

a right low-pressure ventriculoperitoneal shunt was inserted. Progressive increase in abdominal girth and respiratory difficulty were noted 6 days post operatively. Gastric lavage and rectal tube insertion did not resolve the problem, in spite of audible bowel sounds and the passage of stool by the patient. Five days later, he developed a fever, which was proven by culture of the CSF to be due to *Escherichia coli*, ventriculitis. Removal of the VP shunt, repeated ventricular aspirations and intrathecal as well as parenteral antibiotics successfully treated the ventriculitis. Serial CT brain scans showed compartmentalization of the lateral ventricles. Abdominal CT scan as well as paracentesis confirmed the fluid to be CSF. A right VA shunt was subsequently inserted under general anesthesia in the operating room. Post operatively, the abdominal girth and respiration returned to normal. Patient has been well three months since he was discharged home and he is being followed up in the out patient clinic.

#### Discussion

All three patients were infants who had communicating hydrocephalus and had been effectively treated with a functioning ventriculoperitoneal shunt. Early abdominal distention occurred within two weeks, of the shunt insertion in two of them, while there was a two-month interval in the third patient. Longer periods of delay before the manifestation of CSF ascites have been recorded in the literature.<sup>5,6</sup> These are a 17-year-old male patient with hydrocephalus, treated with a VP shunt and subsequently developed ascites due to cerebrospinal fluid accumulation, 11 years, afterwards (5) and a 15-year-old girl, with hydrocephalus and a ventriculoperitoneal shunt who 12 years, afterwards, developed CSF ascites. Both were successfully treated with the insertion of ventriculoatrial shunts. The abdominal distension in our three patients was confirmed both by plain abdominal x-rays, ultrasound, CT and MRI studies, as well as chemical analysis of fluid aspirated, to be due to excess cerebrospinal fluid in the peritoneal cavity. All the patients had audible bowel sounds, passed faeces and had no evidence of mechanical intestinal obstruction (Fig. 1). The abdominal distension was the cause of the respiratory distress and

this was eliminated when the functioning VP shunt was changed to a VA shunt. Ventriculitis was common to all the cases. *E. coli*, *Staphylococcal epidermidis* and *Staphylococcus aureus* were the bacteria grown in the CSF. Intrathecal and parenteral antibiotics successfully treated the CSF infection.

#### Conclusion

Cerebrospinal fluid ascites is an entity, which is not uncommon and can occur as a complication in patients who have a functioning ventriculoperitoneal shunt inserted because of hydrocephalus. Abdominal distention is due to fatigue in the absorptive capacity of the peritoneal cavity. A reversed osmotic gradient in the peritoneal cavity, due to infection and accumulation of protein rich CSF, are usually the cause. This may occur early or late. Ventriculoatrial shunt insertion is a satisfactory method of dealing with the problem.

#### References

1. Ignelzi RJ and Kirsch WM: Follow-up analysis of ventriculoperitoneal and ventriculoatrial shunts for hydrocephalus. *J Neurosurgery* 1975; 42:697-682.
2. Keucher TR and Mealey J: Long term results after ventriculoatrial and ventriculoperitoneal shunting for infantile hydrocephalus. *J Neurosurg* 1979; 50:179-186.
3. Bucholz RD and Pittman T: Endoscopic coagulation of the choroids plexus using the Nd: YAG laser: initial experience and proposal for management. *Neurosurgery* 1991; 28 (3): 421-6; discussion 426-7.
4. Tang TT, Whelan HT, Meyer GA, Strother DR, Blanc EL, Camitta. BM and Franciosi RA: Optic chiasm glioma associated with inappropriate secretion of antidiuretic hormone, cerebral ischaemia, nonobstructive hydrocephalus and chronic ascites following ventriculoperitoneal shunting. *Childs. Nev. Syst.* 1991; 7 (8): 458-61.
5. Perez PF, Aparicio CG, Lopez AJA, Alonso CC, Br. As, Mata. GP and Serrano RM: Ascites due to cerebrospinal fluid accumulation. *Rev. Clin. Esp.* 1990; 187 (3): 128-30.