

Eosinophilic enteritis -A diagnostic dilemma

*J.N.A. Clegg- Lamptey, Y.Tettey¹, E.K. Wiredu¹, and E.Y. Kwawukume²

¹Departments of surgery, Pathology¹ and Obstetrics/ Gynaecology²
University of Ghana Medical School
P.O. Box 4236, Accra

Summary

Eosinophilic enteritis is a rare condition of unknown aetiology, although it is generally believed to be due to intestinal allergy. It may mimic peptic ulcer, subacute (or chronic) intestinal obstruction, gastroenteritis, irritable bowel syndrome, and inflammatory bowel disease. The diagnosis is often difficult to make and most cases are only diagnosed after laparotomy/laparoscopy and biopsy. It can be successfully treated with corticosteroids. We report a case of Eosinophilic enteritis in a 27 year old woman the symptoms of which appeared within six weeks of childbirth. With repeated episodes of abdominal pain, vomiting, occasional loose stools with weight loss, she was investigated and treated for many weeks in three hospitals without success. All investigations were inconclusive. Finally laparotomy revealed inflamed segments of small bowel, a biopsy of which showed Eosinophilic enteritis. The patient was subsequently treated successfully with Prednisolone.

Keywords: *Eosinophilia, Enteritis, Gastroenteritis, Abdominal pain, Intestinal obstruction, Laparotomy, Corticosteroids*

Résumé

Eosinophilic enteritis est une condition rare de aetiology inconnu, bien qu'il soit généralement cru pour être grâce à l'allergie de intestinal. Il peut imiter, subacute (ou chronique) intestinal, gastroenteritis, irritable intestin, et inflammatory intestin. Le diagnostic est souvent faire et la plupart des cas seulement sont après diagnostiqué laparotomy/laparoscopy et biopsie. Il peut être traité avec succès avec corticosteroids. Nous rapportons un cas de Eosinophilic enteritis dans un 27 ans femme les symptômes de qui ont apparu dans six semaines de childbirth. Avec répété épisodes d'abdominal douleur, vomiting, occasionnel detache tabourets avec; elle a été examiné et a été traité pour beaucoup de semaines dans trois hôpitaux sans succès. Toutes investigations étaient peu concluantes. Finalement laparotomy a revele des segments enflammés de petit intestin, une biopsie de qui a montré Eosinophilic enteritis. Le malade a été traite par la suite avec succès avec Prednisolone.

Introduction

Abdominal pain is one of the most common presenting complaints in surgical practice. In many cases a diagnosis can easily be made after detailed history and examination. Sometimes, especially in subacute cases, it is by more detailed investigations and observing how the clinical features evolve that the diagnosis becomes clear. Occasionally patients with "non-specific abdominal pain" are seen but these tend to be self-limiting. The surgeon very occasionally has to manage the patient whose diagnosis can only be made by laparotomy. Laparoscopy is less invasive and is preferred in such patients. We report a case of Eosinophilic enteritis that posed such a diagnostic dilemma until after laparotomy and biopsy of the intestinal wall.

Case report

A 27-year-old female developed abdominal pain (predominantly epigastric) with vomiting six weeks after delivery. She had no past history of allergies and was referred from a regional hospital to Accra when her symptoms persisted. An upper gastrointestinal endoscopy was reported as "normal." Her symptoms, which

were episodic, continued in spite of treatment and she finally referred herself to a third hospital where she was admitted for investigation.

Her main symptoms, when she came to us, were episodic severe colicky abdominal pain, occasional vomiting and constipation and had been ill for seven weeks. On examination she had lost weight but did not look acutely ill. There was no abdominal distension, she had only slight tenderness, and had periods of high-pitched bowel sounds associated with her pain. There were days on which she had no symptoms at all. By the second week of admission she had begun to have intermittent blood-stained watery stools. Investigations performed showed a normal total white cell count with eosinophilia of 11%. An ultrasound scan was normal except for some fluid in the rectouterine pouch of Douglas. Stool examination showed no ova or protozoa, but a very high number of red and white blood cells, and no growth on culture. Retroviral screening was negative. Two plain abdominal X-rays 5 days apart showed a persistent air-fluid level formation around the umbilicus. A decision was then taken to perform an exploratory laparotomy.

At operation there was over 1 litre of serosanguinous fluid in the peritoneal cavity. There was no gross dilatation of the intestines but segments of small bowel (two in the ileum and one in the jejunum) were oedematous, red and thick-walled. There were prominent mesenteric lymph nodes. The rest of the abdominal viscera were normal. An impression of Crohn's disease was made and a full thickness biopsy of the ileum done. In view of the fact that multiple segments were involved, no resection was done.

Histology of the bowel (Fig. 1) showed broadening of the villi with elongation of the crypts. Numbers of eosinophils were seen in the mucosa and in the submucosa, which also showed focal densities. The muscularis propria was thickened and contained numerous eosinophils. No parasites were seen. A diagnosis of Eosinophilic enteritis was made.

The patient was put on Prednisolone and her symptoms resolved very quickly. She began to put on weight and is currently on long-term follow-up.

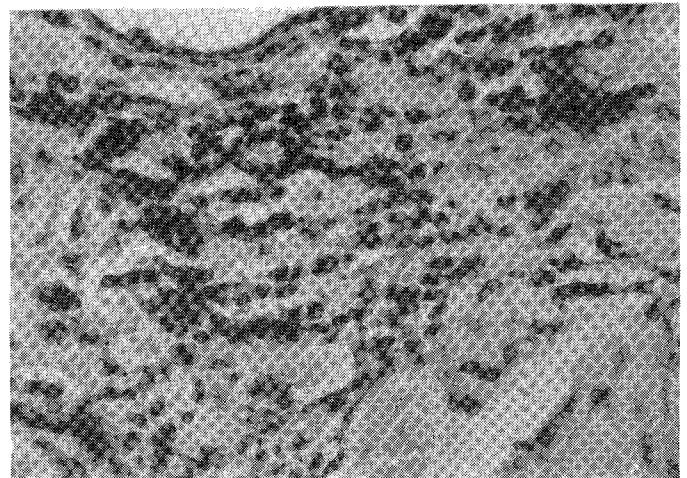


Fig. 1 Photomicrograph of ileum showing an intense infiltrate of eosinophils in the mucosa. The submucosa and muscle layer show the same features (x40)

*Correspondence

Discussion

Eosinophilic enteritis is a rare condition of unknown aetiology and is characterised by eosinophilic infiltration of the gastrointestinal tract.¹⁻⁵ The accumulation of eosinophils has been shown to be antigen induced.⁶ Previous associations with food allergy, atopic dermatitis and elevated IgE levels suggest an atopic disposition in its pathogenesis.² Allergy to the hookworm *Ancylostoma caninum* has been implicated in northeastern Australia where although the more generalised form (Eosinophilic gastroenteritis) is rare, eosinophilic enteritis is fairly common.¹ Allergy to drugs has also been reported.² The diagnostic criteria are gastrointestinal symptoms, eosinophilic infiltration proven by biopsy, and the absence of parasitic infection.²

The presentation may be varied.³ In a review of 6 patients presenting with the condition in 10 years in India the symptoms included abdominal pain and vomiting (100%), weight loss (57%), diarrhoea (43%) and abdominal distension (43%). Peripheral blood eosinophilia was present in all patients.³ The condition may therefore mimic intestinal obstruction,⁷ pseudo-obstruction,⁸ Crohn's disease,⁹ peptic ulcer, diverticular disease,⁴ irritable bowel syndrome and nonspecific abdominal pain.

Laboratory results may be nonspecific,⁵ although most patients have blood eosinophilia.^{3,10} Radiographic findings may show evidence of intestinal obstruction, but may be inconclusive.⁵ The diagnosis is made following intestinal biopsy at laparoscopy or laparotomy. When the stomach is affected (Eosinophilic gastroenteritis) endoscopic biopsy will lead to a diagnosis.¹¹

The appearance of the bowel at surgery depends on the severity of the disease, whether it is predominantly mucosal, submucosal or muscular.³ Variable segments of the bowel are involved and this may be confused with inflammatory bowel disease. There is usually oedema of the bowel, ascites and regional lymphadenopathy¹ as was found in this patient. Surgical resection has been used successfully when severe disease is localised.^{3,9} Corticosteroid therapy is very effective in treating the condition^{3,11} as shown in this patient. There may be recurrence if the offending antigen is not found and eliminated from the diet. In the long term strictures have been known to develop in affected segments of small intestine.⁹

That this patient had a long period of investigation without success is consistent with other reports.^{7,10} Although she had a gastroscopy early in the disease a biopsy was not taken probably because the stomach looked normal. Later in the disease her symptoms mimicked chronic/subacute intestinal obstruction but did not warrant laparotomy without further investigations. Stool tests showed no intestinal parasites but showed the presence of red and white cells. Screening for retroviral infection was done on account of the weight loss and episodic diarrhoea. She did have an eosinophilia of 11% but it was the evidence of some degree of obstruction in the radiographs and the fact that the condition had persisted for

so many weeks that prompted the decision to operate.

It is suggested that fiberoptic endoscopic biopsy might be needed to identify Eosinophilic gastroenteritis if an allergic patient with blood eosinophilia complains of severe gastrointestinal symptoms.¹¹ The biopsy should then be performed even if the stomach appears quite normal. Laparoscopy is another useful option and surgeons should continue to encourage its use in similar patients with ill-defined abdominal pain, nonspecific laboratory results and radiological findings that are inconclusive and do not allow one to initiate appropriate therapy.⁵ Where laparoscopy is not available, laparotomy may have to be the last resort.

References

1. Walker N I, Croese J, Clouston A D, Parry M, Louka and Prociw P.: Eosinophilic enteritis in northeastern Australia. Pathology, association with *Ancylostoma caninum*, and implications. *Am J Surg Pathol*; 1995; 19(3): 328-37
2. Lee J Y, Medellin M V and Tumpkin C.: Allergic reaction to gemfibrozil manifesting as eosinophilic gastroenteritis. *South Med J*; 2000; 93 (8): 807-8
3. Venkataramam S, Ramakrishna B S, Mathan M, Chacko A, Chandy G, Kurian G and Mathan V I.: Eosinophilic gastroenteritis - an Indian experience *Indian J Gastroenterol*; 1998; 17(4): 48-9
4. Mortensen N J.: Inflammatory disorders. In *Oxford Textbook of Surgery* Ed Morris P, Malt R Oxford University Press: 1994; 1036-8
5. Edelman D S.: Eosinophilic enteritis. A case for diagnostic Laparoscopy *Surg Endosc* 1998; 12(7): 987-9
6. Hogan S P, Mishra A, Brandt E B, Forster P S and Rothenberg M E.: A critical role for coxixin in experimental oral antigen-induced eosinophilic gastrointestinal allergy *Proc Natl Acad Sci U S A* 2000; 97(12): 6681-6
7. Yamada S, Chakrabandhu T and Lertprasertsuke N: Eosinophilic enteritis caused chronic partial small intestinal obstruction: a case report and review of the literature *J Med Assoc Thai*. 2000; 43(8): 953-8
8. Losanoff J E, Kjossev K T and Katrov E T.: Eosinophilic enterocolitis and visceral neuropathy with chronic intestinal pseudo-obstruction *J Clin Gastroenterol* 1999; 28(4): 368-71
9. Gjersee P, Rasmussen S N and Hansen B F.: Eosinophilic enteritis. *Ugeskr Laeger*. 2000; 162(19): 2756-7 (abstract)
10. Rodriguez H E, Djohan R S, Cahill W J, Connolly M M and Podbielski F J: Laparoendoscopic diagnosis of eosinophilic enteritis *J Soc Laparoendosc Surg*. 1998; 2(2): 181-4
11. Park H S, Kim H S and Jang H J.: Eosinophilic gastroenteritis associated with food allergy and bronchial asthma *J Korean Med Sci*. 1995; 10(3): 216-9