

Schwannoma of the left brachial plexus mimicking a cervicomedial goiter in a young Nigerian lady.

*D. O. Irabor¹, J. K. Ladipo¹, F. N. Nwachokor² and J. O. Thomas²

Departments of Surgery¹ and Pathology², University College Hospital, PMB 5116, Ibadan, Nigeria

Summary

The schwannoma is thought to arise from the schwann cells of the nerve sheath. This tumor is usually solitary and may arise from any cranial or peripheral nerve¹. It is encapsulated and appears to arise focally on a nerve trunk so that the nerve itself is stretched over the tumor rather than running through it as in neurofibroma¹. This report is unusual as the tumor started as a cervical swelling which subsequently grew into the mediastinum simulating a retrosternal goiter. The patient, a 25 year-old female was referred to the University College Hospital, Ibadan, 24 hours after an attempted thyroidectomy at a private hospital. The history was of a painless anterior neck swelling of 4 years duration devoid of symptoms of hyperthyroidism with associated dysphagia and weakness of the left hand. Examination showed an asthenic young woman. Her voice was hoarse but there were no eye signs suggestive of thyrotoxicosis. On the anterior neck was a sutured skin-crease scar over a diffuse anterior neck swelling which one could not get below. The left hand showed wasting of the thenar and hypothenar eminences. Thyroid function test results were within normal limits, indirect laryngoscopy showed a left vocal cord paralysis, packed cell volume was 38%. Her chest x-ray showed a huge left retrosternal and apical soft tissue mass displacing the trachea to the right (figure 1). A fine needle aspiration cytology was reported as a chronic lymphocytic thyroiditis. A presumptive diagnosis of thyroid carcinoma with retrosternal extension was made.

At surgery, manipulation of the mass was difficult as the tissue was soft, slimy and ruptured easily. Severe hemorrhage was encountered necessitating a median sternotomy to control the bleeding vessels. Her post-operative period was stormy, however she thereafter made gradual progress to warrant her discharge six weeks post surgery.

Résumé

On avait pensé que le schwannoma se produit à travers les cellules schwann du nerf de gaine. D'ordinaire, cette tumeur est toujours solitaire et peut se produire à travers n'importe quel crânien ou nerf périphérique il s'était capsulé et il paraît qu'il se produit surtout sur un nerf de tronc du manière que le nerf lui-même s'étend sur la tumeur au lieu d'aller directement comme en est le cas dans le neurofibrome. Ce rapport se voit rarement parce que d'abord la tumeur commence comme une bosse cervicale qui se développe et finalement devient un médiastinum avec la tendance d'être un goitre retrosternal. La malade est une femme. Elle avait 25 ans et envoyée au Collège Hospitalier Universitaire d'Ibadan, tout juste 24 heures après un effort de faire la thyroïdectomie dans un hôpital privé. L'histoire de la maladie est que l'extérieur de son cou est gonflé et elle ne sentait aucune douleur au cours d'une période de 4 ans et il n'y avait pas de symptômes de l'hyperthyroïdisme lié avec la dysphagie et la faiblesse dans la main gauche. Après avoir passer une visite médicale, on avait pu noter que cette femme avait la maladie d'asthénique. Sa voix enrouée il n'y avait pas de signes dans les yeux qui peuvent indiquer la thyrotoxicosis. A l'extérieur du cou se trouve une cicatrice d'une suture sur l'antérieur du cou gonflé. Dans la main gauche, on peut voir très clairement le thenar et l'hypothenar. Les résultats d'examen du

fonctionnement de la thyroïde était normal. Le laryngoscope indirect, la méthode, indirecte du laryngoscope a montré que la paralysie des cordes vocales de l'endroit gauche, le tamponnement du volume de la cellule était 38%.

Le rayon X de sa poitrine a montré un grand retrosternal dans l'endroit gauche et une collection de tissu apical mou qui avait déplacé la trachée artère vers le côté droite (illustration 1). On avait pu noter une aiguille fine aspiration cytologique comme un lymphocytic thyroiditis chronique. On avait effectué une diagnose de la thyroid carcinoma avec retrosternal prolongé.

Au cours de la chirurgie le manoeuvre de cette collection était difficile parce que le tissu était mou, limoneux et facilement rompu. On avait subi à une hémorragie grave ce qui avait nécessité une veine médiane sternotomie pour régler les vaisseaux saignants. Sa période postopératoire était très très touchante; heureusement, elle s'est rétablie d'une manière progressive et six semaines plus tard après la poste chirurgie elle est sortie de l'hôpital.

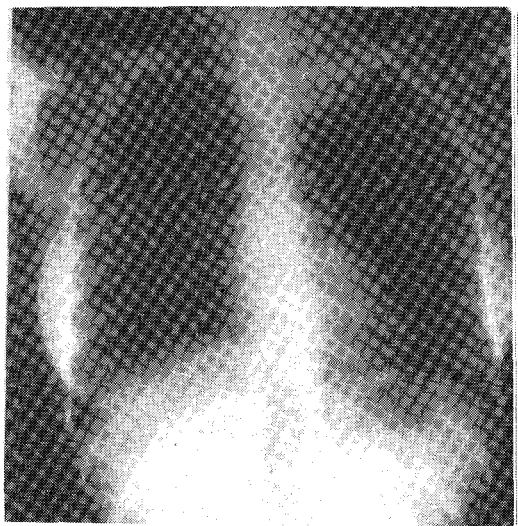




Fig. 1 Plain chest X-ray of the patient showing a cervicomedial mass displacing the trachea to the right



Photomicrograph showing Antoni A differentiation within the same excised specimen.

*Correspondence



Photomicrograph showing Antoni B differentiation

Comments

Schwannomata could be likened to the "great imitators" like tuberculosis, syphilis and lipomata. This is due to their ability to arise from any organ or tissue that possesses myelinated nerves, thus they may produce mass lesions which could mimic disease otherwise caused by the particular organ or tissue in that location^{2,3,4}. The patient in this report had a schwannoma of the left brachial plexus presenting as a cervicomedial goiter. Schwannomas of the salivary glands mimicking pleomorphic adenomas are reported^{2,3}, also reported are schwannomas of the cervical sympathetic chain leading to Horner's Syndrome⁵ and schwannomas of the vagus and phrenic nerves appearing as mediastinal masses^{6,7}.

Brachial plexus schwannomata have been reported to manifest as causing nerve compression symptoms⁸ which our patient experienced or an abnormal mediastinal shadow on plain chest-xray due to intrathoracic extension⁹. Preoperative diagnosis of schwannomata is difficult especially in the head and neck where they are reported to be rare⁴. Fine needle aspiration cytology may be helpful in some cases, however the pitfall of aspiration cytology is that it can be non-specific¹⁰. In the absence of Verocay bodies, the cytological appearance of schwannomas can be non-specific with differential diagnosis including a number of spindle cell lesions. The diagnostic accuracy however can be enhanced by the use of electron microscopy and immunocytochemistry¹⁰.

Major of the diagnoses of schwannoma are therefore made at surgery or through histopathological examination. Features that supported a cervicomedial goiter included the anterior cervicomedial mass, the chest-xray appearance, the left vocal cord paralysis and the fine needle aspiration cytology report suggesting thyroiditis.

The lessons learnt from this case underscores that fact that not all anterior neck swellings are of thyroid origin, and when features do not quite fit what should be a "spot diagnosis" type of lesion, one should think of any of the great imitators.

Acknowledgement

We wish to thank Mr. Musa Usman, Photographic superintendent of the international institute of tropical agriculture for helping with the photomicrographs.

References

1. Walter JB, Israel MS (eds) General pathology 5th Edition Churchill Livingstone, Edinburgh, London and New York 1979. Pages 319-320.
2. Mair S, Leiman G. Benign schwannoma masquerading as pleomorphic adenoma of the submandibular salivary gland. Acta cytologica, 1989; 33, 907 - 10.
3. Samet A, Podoshin L, Frandis M et al. Unusual sites of schwannoma in the head and neck. Journal of Laryngology and otology 1985; 99, 523 - 8.
4. Mikosch P, Gallowitsch HJ, Kresnik E, Lind P. Schwannoma of the neck simulating a thyroid nodule. Thyroid 1997; 7, 449-51.
5. Myssiorek DJ, Silver CE, Valdes ME. Schwannoma of the cervical sympathetic chain. Journal of Laryngology and otology; 1988; 102, 962-5
6. Hasegawa M, Ogasawara A, Yano S et al. A case of mediastinal schwannoma originating from the intrathoracic vagal nerve. Kyobu Geka - Japanese journal of thoracic surgery, 1989; 42, 474-7.
7. Morisaki Y, Sano S, Sakawaki T et al. A case of schwannoma of the intrathoracic right phrenic nerve. Kyobu Geka - Japanese journal of thoracic surgery, 1989; 42, 239 - 43.
8. Atasoy E. Thoracic outlet compression syndrome caused by a schwannoma of the C7 nerve root. Journal of Hand Surgery, 1997; 22, 662-3.
9. Tokitsu T, Tachibana S, Kawakami M et al. A case of schwannoma arising in the brachial plexus with intrathoracic extension, Kyobu Geka - Japanese journal of thoracic surgery, 1997; 50, 598-601.
10. Zbieranowski I, Bedard YC. Fine needle aspiration of schwannoma. Value of electron microscopy and immunocytochemistry in the preoperative diagnosis. Acta cytologica, 1989; 33, 381 - 4.