

Grinding machine: Friend or Foe

*I. A. Adigun¹, S. A. Kuranga² and L. O. Abdulrahman¹

Division of Plastic & Reconstructive Surgery¹, Division of Urology²

Department of Surgery, University of Ilorin Teaching Hospital

P. M. B. 1459 Ilorin, Kwara State, Nigeria.

Summary

Few cases of traumatic losses of the external genitalia have been reported in this part of the world. In a developing country like ours, grinding machines are commonly being used by the people for domestic purposes. Children in their mid-fifteens are usually employed to man and operate the machine without proper training and apprenticeship. Many of them have fallen victims of various genito-urinary injuries from grinding machine. Treating a child for complete traumatic loss of penis is rare and challenging any where in the world.

A 12 years old boy presented to the emergency unit of our hospital with penile amputation 18 hours after the injury was sustained. A penile reconstruction of corporal cavernosa phalloplasty was used. This method of reconstruction may be used by clinician in our sub-region where other treatment modalities such as replantation by microvascular surgery, use of free radial fore-arm flap or sex reassignment to the female gender may not be feasible or acceptable.

Keywords: *Grinding machine, Problems, Management*

Résumé

Peu de cas des pertes traumatiques des organes génitaux externes ont été rédigés dans cette partie du monde. Dans les pays en voie de développement comme le notre, le gens utilisent le plus souvent des moutures pour des usages de ménage. Le plus souvent, on engage des enfants dans les années mi-quinze de manœuvrer et opérer la machine sans une formation et apprentissage adéquate. La plu part d'entre eux sont victime de blessures génitales urinaires diverses de mouture. Traitement médical pour un enfant souffrant de la perte traumatique totale de penis est rare et provocant n'importe où dans le monde entier.

Un enfant âgé de 12 ans a été admis à la salle d'urgence de notre hôpital victime de l'amputation du penis 18 heures après s'être blessé. Une reconstruction pénil de la phallo plastie cavernuse corporelle a été adopté. Cette méthode à travers la reconstruction peut être utilisée par des cliniciens dans la sous région ou des autre méthodes de traitement telles que la replantation à travers la chirurgie micro vasculaire, free radial fore-arm flap ou le sexe relocation au genre féminine ne sont pas réalisables ou acceptables

Introduction

Cases of traumatic losses of the external genitalia have not been commonly reported in this part of the world. In developed countries where such cases have been reported, electrocautery accidents during circumcision¹ or injury by domestic animals² are frequently implicated causal agents. Victims of abuse and motor vehicle accidents have also been reported.³ In a developing country like ours, grinding machines are commonly being used by the people for domestic purposes. Thus cases with lacerations, avulsion injury of the external genitalia have presented to our emergency unit in the past. These cases have been managed either by simple suturing or adequate wound dressing. To the best of our knowledge, the authors have not come across report of complete loss of external genitalia due to trauma in this part of the world.

Management of penile amputation in children can pose a serious problem to the clinician in the developing countries. The only alternative to adequate penile reconstruction is sex re-assignment

for a child less than 1 year of age to the female gender which may be unacceptable to the people in our environment. Management and problems associated with management of penile amputation is discussed in this paper with a case illustration of a 12 year old boy who presented to the emergency unit of our hospital with penile amputation. The clinical, photographs at pre, intra and post-operative periods are as shown in the pictures.

Case history

Patient S. A. with hospital number 218267 is a twelve year old boy who presented with 18 hours history of injury to the perineum by a grinding machine. He was referred from a General hospital in Saki, Oyo State of Nigeria. Patient sustained the injury when he attempted to switch off a grinding machine after being used by his mother for a commercial purpose. The fan belt was said to have caught his cloth and dragged the patient towards the machine. In the process the penis was mangled. The patient bled profusely from the injury sustained on the perineal region but no other injury was noted in other parts of the body. He is not a known epileptic and there was no history of any contributory pre-morbid condition. He is the second of a set of twins in a family with 3 children.

General examination revealed a near total amputation of the phallus with a degloving injury of the proximal stump which was a little bit less than 2cm. The distal fragment which was held by skin tag was cold and pale. There was a deep laceration on the scrotum and root of the penis but the testicles were intact. Multiple abrasions around the perineum and the thighs were noted. An assessment of penile amputation secondary to trauma from a grinding machine was made. Patient had wound debridement and dressing done as well as catheterization of the urethral stump. He was given tetanus prophylaxis, antibiotics (Cefuroxime and Gentamycin) and generous analgesics. Blood was taken for packed cell volume, serum electrolyte, Urea and Creatinine, as well as grouping and cross matching.

Patient was to have phalloplasty and meatoplasty done as well as possible but because of financial incapability on the part of the parents of the boy and logistic problems on two occasions, the procedure of phalloplasty with full thickness skin graft was done 8 weeks after the injury was sustained. Immediate post-operative condition was uneventful. Fifth day post-operative, the grafted skin was inspected and 100% take was recorded. A second review on the 10th day post-operative showed some epidermolysis and a loss of about 20% of the grafted skin. Wound was cleansed with normal saline and dressed with sufrattule. Patient was discharged home two weeks after. Skin sensitivity over the reconstructed penis was poor and it was difficult to assess its erection ability, patient could however void standing. He was seen once in the clinic for follow up.

Surgical technique for Corporal Cavernosa Phalloplasty

Fig. 1 shows amputation of the penis with the distal fragment held by skin tag. Using the general anaesthesia, patient was cleansed and draped to expose the perineum and lower abdomen. A circular incision was made 2cm from the catheter to excise the fibrous tissue as shown in figure 2a. The corporeal stumps was identified and 2-sutures were passed through the distal end for traction as show in figure 2b. Corporeal dissection was advanced carefully

* Correspondence




Fig. 1 Showing amputation of the penis with the distal fragment held by skin tag

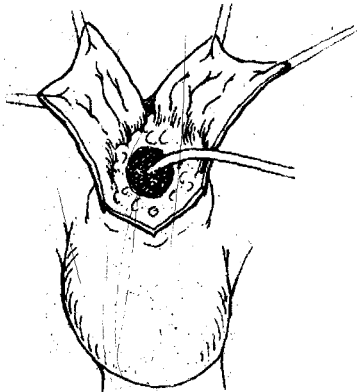


Fig. 2a Showing a circular incision made 2cm from the catheter to excise fibrous tissue

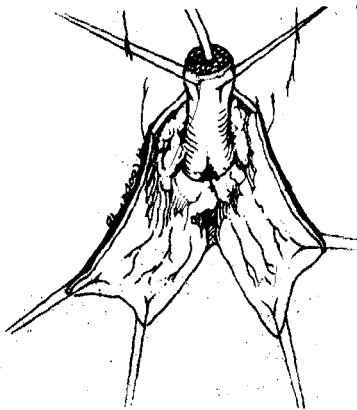


Fig. 2b Sutures passed through the distal end of corporal stumps for traction

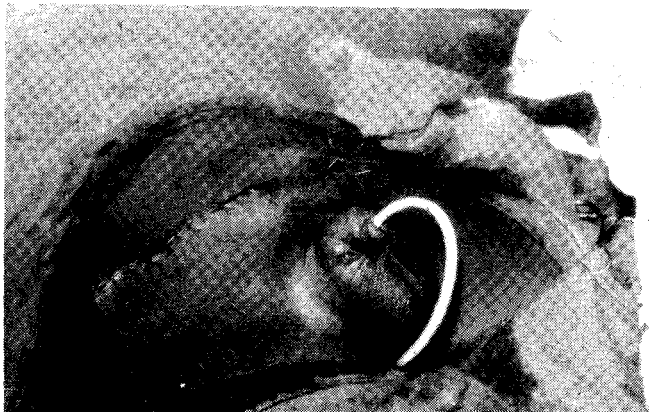

Fig. 3 Showing mobilized corpora and urethra wrapped with full thickness skin graft taken from the two sides of the groin.

down close to the ischiopubic rami of one public bone with special care not to injure the blood supply. The suspensory ligament was divided to give additional length. The mobilized corpora and urethra were long enough to protrude at least 5cm above perineal skin level. They were then wrapped with full thickness skin graft taken from the two sides of the groin as shown in fig 3. The donor sites were closed directly.

Discussion

Amputation is the ultimate penile injury and treating a child for complete traumatic loss of the penis is rare and challenging anywhere in the world. The success of the treatment depends on some crucial factors like the nature of lesion, time interval between the time of injury and presentation to the hospital, the time interval between the time of presentation to the hospital and the treatment and finally the age of the child is extremely important. Grinding machine is a common domestic machine used in our sub-region for grinding some ingredients and some food materials. Children in their mid-fifteens are usually employed to man and operate the machine without proper training and apprenticeship. Often times, these children out of curiosity, stand as on lookers. Many of them have fallen victims of various genito-urinary injuries from grinding machines. It is therefore pertinent to emphasize the need to inform the populace through health education, the health hazards that can result from this child abuse.

Traumatic amputation of the penis is managed initially by re-plantation. This is preferable when the distal segment is available in good condition (Viable) and the ischaemic time is less than 18 hours.⁴ Initial management includes cleaning of the injured penis wrapped in a sponge or gauze wet with saline and placed inside a nylon or polythene bag wrapped inside a box of ice-cubes. Re-implantation can be done if the ischaemic time is within 18 hours. Various treatment options are available for penile reconstruction.

Free radial fore-arm flap has become the main stay of penile reconstruction procedures. The ischaemic time of the patients that present to us usually exceed 18 hours most times. This can be explained from the point of view of poverty, poor transportation system in cases of distant place of injury, poor socio-economic state of our patients, ignorance of possible treatment for such injury and finally lack of man power and relevant equipment for the management of such patient in most towns and villages.

In the illustrated case, the ischaemic time was about 16-18 hours, and the distal phallus was already gangrenous as shown in fig 1, hence the possibility of re-anastomosis was not considered. It is a known fact that longer ischaemic time may be permissible if severed phallus is well prepared and preserved in an iced saline gauze environment and if expertise and equipments are available for successful microvascular procedure. Interest in microvascular surgery is just developing in our sub-region.

Functional reconstruction of severely contused or amputated penis is rarely achieved and considered accumulated results have shown that the outcome is usually poor.^{5,6} People have also described procedure like dermal or skin phalloplasty. It is important to emphasize that there is no replacement in the human body for penile erectile tissue. In dermal phalloplasty, the constructed phallus cannot be compared functionally and structurally with the normal penile erectile tissue. Sex reassignment is considered the best option for a boy younger than 1 year with the loss of penis, it is also indicated in other conditions like, 46XY individuals of male intersex disorder, penile agenesis, male infants with circumcision complications due to electrocautery and cloaca extrophy^{7,8,9,10}.

Sex reassignment which seems the best option for these category of patients may be unacceptable in this region for religious, traditional and social reasons.

The method of re-construction used in the management of this illustrated case is therefore recommended in our environment.

Conclusion

Treating a child with complete traumatic loss of the penis is rare and challenging. Grinding machine commonly used as a domestic instrument in our sub-region can pose-serious health hazard to our children especially when operated by inexperienced and virtually overzealous ones. We therefore advocate for public health education to the people to refrain from child abuse by using untrained children to merely operate this dangerous machine without proper supervision. Phalloplasty using the method of reconstruction used in the illustrated cases may be used by clinician in our sub-region.

References

1. Gearhart J P and Rock J.: Total ablation of the penis after circumcision with electrocautery: a matter of management and comparison with human bites. *J. Urology.*, 1993; 149: 286.
2. Wolf J S Jr., Turzan C, Cattolica E U and MC Aninch J W.: Dog bites to the male genitalia: Characteristics, management and comparison with human bites. *J. Urology.*, 1993; 149: 286.
3. Bernedo O: Trauma of the external genitalia in children: Amputation of the penis and Emasculation. *J. Urology*, 1998; 160: 1116-1119.
4. Engelman E R, Polito G, Perley J, Bruffy J and Martin D C: Traumatic amputation of the penis. *J. Urology.*, 1974; 112: 714.
5. Hage J J, Bloem J J and Suleiman H M.: Review of the literature in techniques for phalloplasty with emphasis on the applicability in female to male transsexuals. *J. Urology*: 1993; 150: 1093.
6. Money J: Sex errors of the body and related syndromes: A guide to Counselling children, Adolescence and their families 2nd Edition. Baltimore John Hopkins University Press, 1994.
7. Gearhart J P and Rock J: Total ablation of the penis after circumcision with electrocautery. A method of management and long term follow up. *J. Urology*: 1989; 142: 799.
8. SoderWahl D W and Brossman S A et al: Penile agenesis. *J. Urology*: 1972; 108: 496.
9. Meyer-Balbury H F L: Gender identity developing in intersex patients. *Child. Adolescence. Psychiatry Clinic of North America Journal*: 1993; 2: 501.
10. Money J and Mazur J.: et al. Micropenis, Family mental health and neonatal management. A report of 14 rared as girls. *J. Prevent. Psychiatry*. 1981; 1: 17.