

# Congenital dislocation of the knee in Ibadan, Nigeria

\*B. Omololu, S. O. Ogunlade and T. O. Alonge

Division of Orthopaedics and Trauma,

College of Medicine U. I. Ibadan

E-mail: badelolu@skannet.com.

## Summary

Between January 1996 and December 2001, 41 congenital dislocations of the knee joints (30 patients) were reduced with closed methods by immediate reduction without anaesthesia and serial casting in plaster of Paris immobilization for a period of six to eight weeks.

The patients' age ranged from the age of one week to four weeks with a male to female ratio of 1.5:1.

The right knee was involved in 46.65% the left in 16.6% and bilateral involvement in 36.65% of patients.

Routine check of the hip did not reveal any patient with hip instability.

All the patients followed up after 2 years showed excellent results.

We conclude that congenital knee dislocation when discovered early and without any other congenital malformation can be managed conservatively with excellent results.

**Keywords:** Congenital, Knee dislocation, children

## Résumé

Entre janvier 1996 et décembre 2001, 41 cas de dislocation congénitales d'articulation de genou chez 30 patients ont été réduits avec la méthode fermée à travers la réduction immédiate sans l'anesthésie et serial casting dans le moulage en plâtre immobilisation pour une période de six à huit semaines.

Les patients âgés d'une semaine à quatre semaines avec la proportion male femme de 1,5 : 1.

Le genou droite concerne en 46,65%, le genou gauche en 16,6% et concerne bilatéralement en 36,65% des patients.

Vérification de façon systématique de la hanche n'a pas indiqué le cas d'aucun patient avec l'instabilité de la hanche. Après l'examen de contrôle à long terme d'une durée de 2 ans tous les patients avaient indique les resultats excellents.

De ceci nous concluons que la malformation congénitale peut être traitée de façon classique avec des résultats parfaits.

## Introduction

Congenital dislocation of the knee (CDK) is a relatively rare condition with incidence estimated to be less than 1% of the incidence of congenital dislocation of the hip at 1/40,000 to 80,000 live births.<sup>1</sup> CDK is usually diagnosed at birth and characterised by a position of knee recurvatum and difficulty of knee flexion.

We do not know of any English literature relating to congenital dislocation of the knee in Africans, which is supposedly rarer than in Caucasians

The aetiology of CDK is controversial though several factors have been implicated such as oligohydramnios, extended breech position, abnormality of the anterior cruciate ligament and quadriceps contracture.<sup>2,3,4,5,6,7,8</sup>

It has been postulated that the basic defect in CDK is absence or hypoplasia of cruciate ligaments;<sup>4</sup> while other investigators consider these findings secondary to the dislocation.<sup>5,6</sup>

Early recognition of CDK is important, as treatment is remarkably good. In the newborn with mild to moderate hyperextension or subluxation, conservative treatment methods such as the use of Pavlik harness<sup>7</sup> for posturing of the knee in a continued position and serial casting to increase knee flexion are most likely to succeed. Occasionally in patients that do not respond to conservative

measures the use of skeletal traction for correction is an option.

We report our experience in the treatment of a series of patients with CDK without any other associated musculoskeletal abnormalities in an African society.

## Materials and Methods

Between January 1996 and December 2001, 30 patients with 41 CDK were treated at the University College Hospital, Ibadan, Nigeria. Twenty of the patients have been followed up for more than 2 years with excellent results. This prospective study includes 18 boys and 12 girls ranging in age from 1 week to 3 weeks. Side of involvement included the right knee in 14 and the left knee in 5 and bilateral involvement in 11 knees.

The birth history was obtained from the parents and also from the medical records in those delivered in the University College Hospital. All our patients had conservative management with manipulation and serial casting of the knee in flexed positions for six weeks. The casting was changed every 2 weeks for 6 weeks with each change of casting accompanied by further flexion of the knee.

Radiography of both knees is done 8 weeks after treatment to confirm congruent anatomic reduction.

## Findings

All our cases were spontaneous vaginal deliveries and 18 of our patients presented within the first week of birth while 12 presented after the first week but none presented more than 4 weeks after birth. Twenty of the mothers were primiparous while five were multiparous women. There was no actual parity history obtained from the remaining patients as they were brought by concerned relatives. We did not get any relevant information from parents as regards any family history of congenital malformations in all our patients.

There was no associated musculoskeletal anomaly physically observed or noted in all the patients.

## Management

All the patients had immediate passive stretching and gradual reduction of the knee with serial casting for six weeks with the cast being changed every two weeks for 6 weeks with each change of casting accompanied by further flexion of the knee. All reduction and casting were done without any anaesthesia in the plaster room; in the presence of the first author. An above knee frontal slab is usually applied to encompass about  $\frac{3}{4}$  of the circumference of the knee. All patients were followed up every 2 weeks for the first 6 to 8 weeks and then 3 monthly until 1 year of age and then annually if parents are still worried. No specific rehabilitation was given.

There was no patient treated with traction or surgical intervention.

## Results

The twenty (20) patients followed up after 2 years have had excellent results.

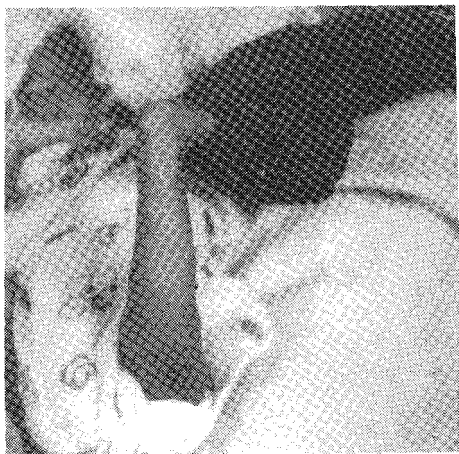Figure 1 shows an anterior CDK before casting while Fig 2 shows the leg with cast in place.

The right knee was involved in 46.6%; the left knee in 16.6% while there was bilateral involvement in 36.6% of patients.

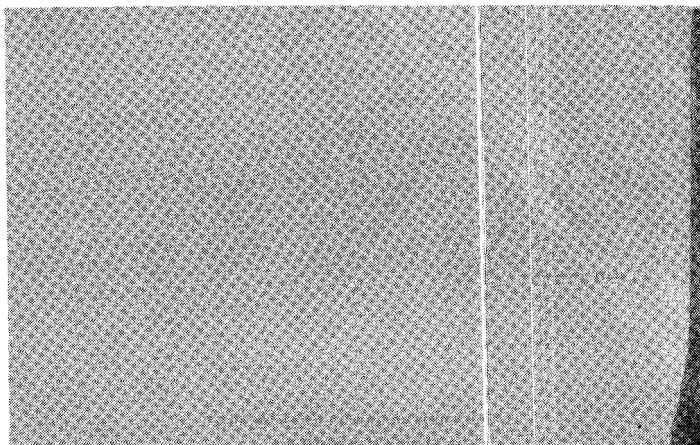
The male to female ratio was 1.5:1

The clinical photograph of the reduced knee is shown in Fig 3 while the radiograph of both knees after eight weeks of immobili-

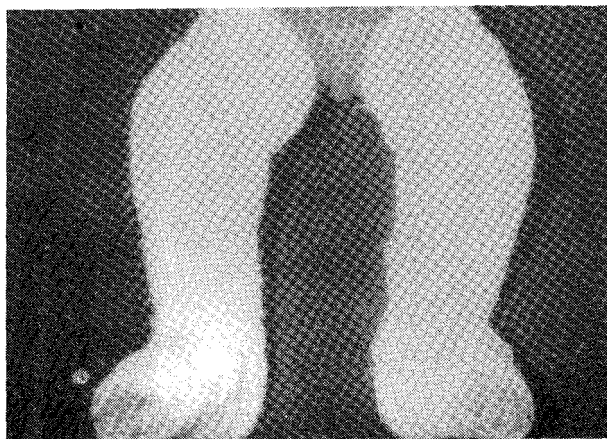
\* Correspondence



**Fig. 1** *Anterior dislocation of the knee before plaster immobilisation*



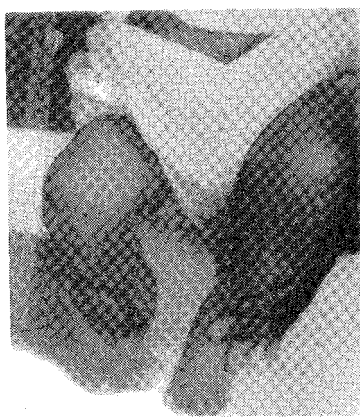**Fig. 5** *Schematic diagram of grades of severity from simple hyperextension to complete dislocation.*



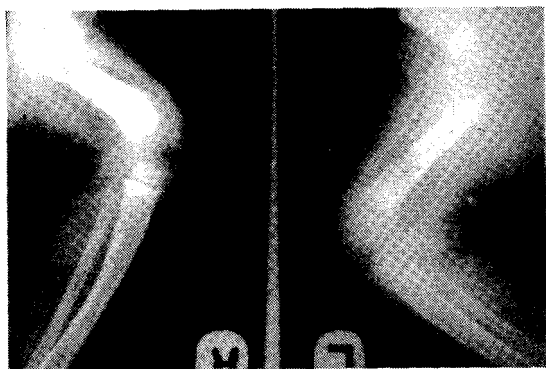
**Fig. 2** *Anterior CDK with plaster immobilisation in place.*



**Fig. 6** *Photograph of patient standing at one year of age*



**Fig. 3** *Clinical Photograph of reduced knee*



**Fig. 4** *Radiograph of both knee showing congruent anatomic reduction.*

the twenty five patients followed up for more than two years have had excellent results with full range of motion in the involved knees and no history of recurrence of deformities.

**Discussion**

Although several factors have been postulated as to the aetiology of CDK, a genetic defect aetiology is supported by the observation of familial occurrence, whereas a non-genetic dysplastic etiology is supported by the random occurrence of widely dispersed skeletal anomaly found in 40-100% of cases.<sup>2,3,4,6</sup> However in all the cases discussed above, there was no obvious skeletal anomaly and there was no definite family history of any congenital malformation obtained from the patients.

Congenital hyperextension of the knee is only the first of three grades of severity of a single abnormality. These are congenital hyperextension, congenital hyperextension with anterior subluxation of the tibia on the femur and hyperextension with anterior dislocation of the tibia on the femur. See Fig. 5.

The pathologic condition usually varies with the severity of the deformity but always the anterior capsule of the knee and the quadriceps mechanism is contracted. Majority of our patients presumably had the first of the three grades as there was no absence of patella but there was definite contraction of the anterior capsule of the knee joint as full flexion was not possible in the majority of cases at the initial visits but was possible subsequently after the serial castings. As the severity of the anterior displacement of the tibia increases, other findings include intra articular adhesions and absence of the patella. Further the suprapatellar pouch may be obliterated by the adherent quadriceps tendon and the patella may be displaced laterally.<sup>2,7,8</sup>

In severe anterior dislocation, the collateral ligaments coursed

anteriorly from their femoral attachments and the hamstring muscles in some patients may be subluxated anteriorly to function as extensors of the knee in this deformed position.

However, in our series, there were no skeletal abnormalities found in all the cases. Abnormal intrauterine position is suggested by observation of hyper extended knees in breech presentation, however, this cannot account for majority of the dislocations<sup>3,5,9</sup>. This fact is also strongly not supported by our cases where there was no breech presentation. Most authors recommended early conservative treatment and if not successful after 8 weeks, arthrography was advised but Haga et al<sup>5</sup> suggested that it was advisable to wait 1 month for spontaneous reduction of CDK in cases not associated with clubfoot, arthrogryposis multiplex congenital and Larsens syndrome.

These different options make the treatment of CDK confusing but like most authors,<sup>6,7,8,9</sup> we subscribe to the early management of the patients with excellent results as can be seen with the radiograph of our patients standing comfortably at one year of age Fig. 6.

Also in this environment where follow-up of patients is very abysmal, it is worthwhile treating the patients early as they may seek the traditional healers help with disastrous consequences.

Curtis and Fisher<sup>4</sup> in their review of 15 operated knees noted that all their patients were unable to flex beyond 35° before surgery and that the upper age for a satisfactory result was 2 years. They also found that arthrograms were technically difficult to perform and were not helpful in determining the program of management. However none of our patients required arthrograms or surgery as they all did well with conservative management. Curtis and Fisher described a procedure for correction of CDK for children between the ages of 6 and 18 months. The technique combines anterior capsular release, lengthening of the quadriceps mechanism, release of intra articular adhesions and reduction of the tibia on the femur. However, osteotomy of the femur or tibia may be required adolescents.

In older children with subluxation or dislocation, surgery is indicated and in those with both CDK and DDH (Developmental dysplasia of the hip) surgical correction of the knee first is advisable.

In our series passive stretching of the quadriceps and the anterior knee capsule combined with casting of the knee in an increasingly flexed position for 6 weeks was the method of treatment. There was no evidence of adverse effect on the knees when treatment was started early after birth in our series. We therefore recommend that a dislocated knee should be reduced and splinted as soon as possible.

Curtis and Fisher in a study of 15 knees with CDK found an abnormality of the hip in each. Johnson Andell and Oppheim<sup>3</sup> found other abnormalities in 88% of their 17 patients and MacEwen reported congenital hip dysplasia in 50% of their 17 patients.<sup>4</sup>

A large number of associated conditions have been described, the most common of which are congenital hip dislocation (Developmental dysplasia of hip DDH), clubfoot, arthrogryposis and Larsens syndrome<sup>4,7,10,11,12</sup>.

The prognosis of CDK is said to be adversely affected by these associated anomalies, delay in treatment and generalised joint laxity.<sup>3</sup> These factors were not present in all our cases and may be partly responsible for the excellent result in our series with the

early serial casting playing a significant role.

We have been fortunate in our series as there was no clinically detectable associated DDH both at first visit and subsequent visits till the age of one year, and this brings to mind the possibility of rarity of DDH in the African society. However more can be done in the way of ultrasonography of all babies noticed to have clicky hips so as to rule out any clinically missed DDH.

Although clubfoot deformity is prevalent in our practice in Ibadan, Nigeria, there was no clubfoot associated with all the cases of CDK that was seen over the 4 year period.

### Conclusion

For CDK which has been diagnosed early within the first few weeks of life, we recommend early passive stretching with serial plaster cast immobilization for a minimum period of six to eight weeks.

Following the correction patient should be followed up for a period of two to five years so as to detect any recurrence or instability in the knee.

### References

1. Bensahel H, Dal Monte A, Hjelmstedt A, et al: Congenital dislocation of the knee, *J Paediat Orthop* 1989; 9: 174-177.
2. Curtis B H, Fisher R L: Congenital hyperextension with anterior subluxation of the knee. *J. B. JS Am.* 1969; 51:255-69.
3. Johnson E, Andell R, Oppenheim W L, Congenital dislocation of the knee. *J. Pediatr. Orthop.* 1987; 7: 194-200.
4. Nogi J, MacEwen G D. Congenital dislocation of the knee. *J. Pediatr. Orthop.* 1982; 2: 509-13.
5. Haga N, Nakamura S, Sagaguchi R, Yanagisako Y, Taniguchi K, Iwaya T. Congenital dislocation of the knee reduced spontaneously or with minimal treatment. *J. Pediatr. Orthop.* 1997; 17: 59-62.
6. Katz M P, Grogono J S, Soper K C. The etiology and treatment of congenital dislocation of the knee. *JBJS Br.* 1967; 49: 112-20.
7. Lawrence M. Genu recurvatum congenitum *JBJS Br.* 1967; 49: 121-34.
8. Unthoff H K, Ogata S. Early intrauterine presence of congenital dislocation of the knee. *J. Pediatr. Orthop.* 1994; 14: 254-7.
9. Ferris B, Aichroth P. The treatment of congenital knee dislocation - a review of nineteen knees. *Clin. Ortho.* 1987; 216: 135-40.
10. Gilber R J, Larsen L J, Ashley K, James P M. Open reduction with patella tendon elongation for congenital dislocation of the knee. *JB JS Am.* 1975; 57: 133-137
11. Munk S. Early operation of the dislocated knee in Larsen's syndrome. *Acta Orthop Scan* 1988; 59: 582-4.
12. Ooishi T, Sugioko Y, Matsumoto S, Fujii T. Congenital dislocation of the knee; its pathologic "features and treatment. *Clin. Orthop.* 1993; 287: 187-92.
13. Johnson E, Andell R, Oppenheim W L; Congenital Dislocation of the knee. *J. Pediatr. Orthop.* 1987; 7:194-200.