

# EUTUBS: A Mnemonic for the complete endoscopic examination of the lower urinary tract.

\*E. O. Olapade-Olaopa<sup>1,2,3</sup>, C. P. Nelson<sup>1</sup>, S. A. Adebayo<sup>2</sup>, A. D. Fakolujo<sup>3</sup> and D. A. Bloom<sup>1</sup>.

<sup>1</sup>Section of Urology, Department of Surgery, University of Michigan, Ann Arbor, MI, USA, and <sup>2</sup>Divisions of Urology and Paediatric Surgery,

<sup>3</sup>Department of Surgery, College of Medicine, University of Ibadan, Nigeria  
PMB 5116, University of Ibadan, Ibadan, Nigeria. e-mail: okeoffa@yahoo.com

## Summary

Urethroscopy is now routinely done in standard urological practice. The availability of the flexible cystoscope for outpatient procedures has further increased the number of cystoscopists. However, there are currently no formal training schedules for urethroscopy. This mnemonic has been developed to serve as a template for complete endoscopic examination of the lower urinary tract to which the cystoscopist may refer when undertaking this operation. It focuses on the common abnormalities that the endoscopist may encounter, and is not intended to be an exhaustive list of all abnormalities of the lower urinary tract. Furthermore, it is not meant to obviate the need for practical training of those wishing to carry out the procedure as part of their clinical practice.

**Keywords:** Cystoscopy, Surgery Residency Training, Endoscopy, Mnemonic.

## Résumé

L'urethroscopie est fait d'office dans une méthode urologique courante. La disponibilité de la cystoscopie souple pour les services des consultation externes a augmenté de plus le nombre des cas de cystoscopistes. Toutefois, à présent, il n'y a pas un programme de formation conventionnelle pour l'urethroscopie. Cette mnémorique a été élargie afin de servir comme une sablière pour un examen endoscopique complet de l'appareil urinaire inférieur à quoi le cystoscopiste peut se rapporter au cours de la chirurgie.

Son objet est de mettre en relief les anomalies que l'endoscopie peut éprouver et elle n'est pas destinée d'être une liste exhaustive de toutes les anomalies de l'appareil urinaire inférieur.

De plus, elle n'est pas destinée d'obvier à la nécessité pour la formation pratique de ceux qui veut suivre le mode de procédure comme une section de leur étude clinique.

## Introduction

Endoscopic examination of the male and female lower urinary tracts [Figures 1 & 2] (urethroscopy) is fundamental to urological practice and is now a routine procedure. The availability of the flexible cystoscope for outpatient procedures has further increased the number of cystoscopists<sup>1, 2</sup>. However, there are

## The Mnemonic

### (E) External examination.

#### 1. Sexual Development

##### a. Paediatric / Adolescent

- Tanner stage of sexual development<sup>3</sup>

Pubic hair (P1 - V1)

Male genitalia (G1 - V)

##### b. Adult

- Hair distribution appropriate for gender - Yes/No.

#### 2. Female Genitalia

##### Uncircumcised / Circumcised

Introitus (Labia external and internal) - Normal / Abnormal

Urethral Meatus - Normal / Stenosis / Protruding urethral caruncle

Clitoris - Present - Normal / Abnormal

Absent

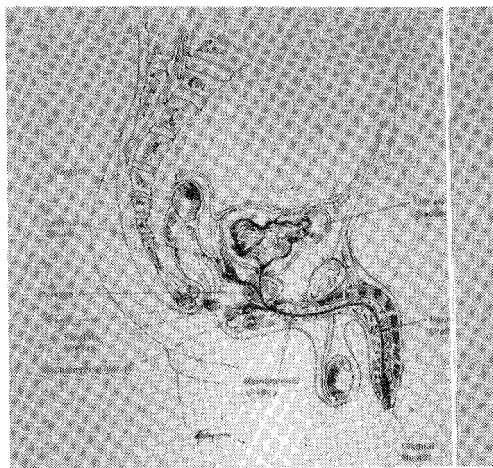


Fig. 1 Mid-sagittal section through the male pelvis showing the anatomy of the lower urinary tract

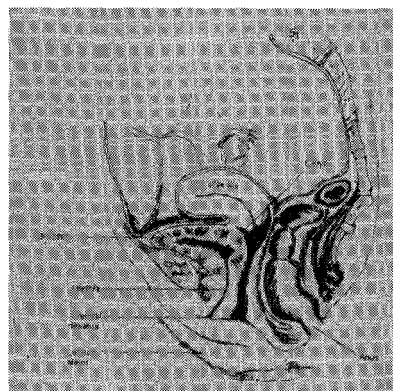


Fig. 2 Mid-sagittal section of the female pelvis showing the anatomy of the lower urinary tract

currently no accredited training protocols for the procedure. We have developed an easily remembered mnemonic that would guide complete endoscopic examination of the lower urinary tract, and to which the cystoscopist may refer when undertaking this operation. The mnemonic focuses on the common abnormalities that the endoscopist may encounter, and is not intended to be an exhaustive list of all abnormalities of the lower urinary tract.

- Vagina
- Paediatric - Normal / Abnormal
  - Preadolescents - Transverse introital diameter <0.7cm (Normal)
  - Transverse introital diameter >0.7cm (Abnormal)
  - Adult - Normal
  - Abnormal - Prolapse (Specify) / Tumour
3. *Male Genitalia*
- a) Scrotum
- Normal / Hydrocoele / Hernia
- i) Testes
- Number
  - Descent - Normal / Maldescent/ Ectopic
  - Lie - Normal / Transverse
  - Size (Orchidometer) - Normal / Atrophic
  - Consistency - Normal / Soft / Hard
  - Mass - No
  - Yes-Size / Consistency / Position
- ii) Epididymis (Caput / Body / Tail)
- Normal / Abnormal
  - Mass - No
  - Yes - Size / Consistency / Position
- b) Penis
- Foreskin
- Circumcised / Uncircumcised
  - Phimosis - No
  - Yes - Unfibrotic / Fibrotic (Balanitis Xerotica Obliterans [BXO])
- Glans
- Normal / BXO / Tumour
- Meatus
- Position - Normal / Hypospadias / Epispadias
  - Stenosis - No
  - Yes - Idiopathic / Post circumcision / BXO
- Shaft
- Normal / Abnormal
  - Chordee - No / Yes - Dorsal / Ventral / Lateral
4. *Genital/Perineal Skin*
- Normal
  - Rash / Infections - No / Yes - Distribution
  - Dampness - No / Yes
  - Injury - No / Yes - New / Old (Scars)
5. *Anus (may be deferred until end of cystoscopic examination)*
- Inspection
- Normal / Discharge (describe) / Sinuses / Fistulae / Masses
- Digital rectal examination
- Peri-anal reflex (if patient awake) - Present / Absent
  - Sphincter tone - Normal / Abnormal - Lax / Increased
  - Rectal wall - Normal / Abnormal (Describe)
  - Prostate (males) - Normal / BPH / CAP
  - Other pelvic masses - No
  - Yes (describe).

**(U) (Endoscopic examination of the) Urethra**

- Normal
- Abnormal - Stenoses / Stricture
- Location
  - Length - Short / Long
  - Passable / Impassable
- Posterior urethral valves (Males)
- No
  - Yes - Occlusive / Non-occlusive
- Diverticulum / Tics / False passages
- No
  - Yes - Location
- Mass lesions / Foreign bodies / Calcifications - Location
- External sphincter
- Normal / Abnormal
- Prostate (Males)
- Normal / Cristae / Voves)
- Urine sample
- Microscopy / Culture and sensitivity / Cytology

**(T) (Endoscopic examination of the) Trigone**

- Bladder neck
- Patent / Contracture - Idiopathic / Post-resection
  - Elevation (Males) - No / Yes
- Trigone proper
- Anatomy - Shape
  - Ridge - Normal / Abnormal
  - Epithelium - Normal transitional / Squamous metaplasia/Tumours

**(U) (Endoscopic examination of the) Ureteric orifices**

- Number - Single / Duplex
- Position - Normal / Ectopic (State positions)
- Shape/configuration - Normal
- Abnormal - Capacious / Stenotic

**(B) (Endoscopic examination of the) Bladder**

- Epithelium - Normal
- Abnormal - Erythema }  
Glomerulations } (State anatomical locations)  
Tumours }  
Post-filling bleeding / Petechiae - No / Yes
- Abnormal openings - No
- Yes (State anatomical locations)
- Saccules (incomplete bladder wall protrusions)
- Diverticulae (complete protrusions through bladder)
- Fistulae - Entero-vesical (males/females),  
Vesicovaginal (female).
- Trabeculations - No / Yes - Grade I / II / III
- Unstable bladder contractions - No / Yes
- Capacity - Paediatric (Average capacity = {Age [years] + 2 x 30} [40])  
Adults (Normal capacity = 450-600mls).

**Considerations in special groups**

This mnemonic should be modified as appropriate when carrying out endoscopic examination in patients who have had gender reassignments or surgical reconstruction of the lower genital tract (e.g. Neobladders or epispadias repairs).

**Conclusion**

This mnemonic is applicable to both rigid and flexible cystoscopic examination whether done under local or general anesthesia. However, it is not meant to replace formal tuition in the art of cystoscopy and therefore assumes that the endoscopist has a good knowledge of the anatomy of the lower urinary tract and its possible abnormalities. We would therefore like to recommend EUTUBS both as guide to complete endoscopic examination of the lower urinary tract and a complement to current urethrocytoscopic

documentation.

**References**

1. Flower CG, Badenoch DF and Thakar DR.: Practical experience with flexible fiber-optic cystoscopy in out-patients. *British Journal of Urology*. 1984, 56: p. 618-21.
2. Gidlow AB, Laniado ME and Ellis BW.: The nurse cystoscopist: a feasible option? *BJU International*. 2000. 85, p. 651-654.
3. Tanner JM.: *Foetus into man. Physical Growth from Conception to Maturity*. 2nd edn. Castlemead Publications. 1989.
4. Koff SA, Lapidus J and Piazza DH.: Association of urinary tract infections and reflux with uninhibited bladder contractions and voluntary sphincter obstruction, *Journal of Urology*. 1979. 122,p 373-376.