

Alveolar bone regeneration pattern following surgical and non-surgical treatment in Juvenile Periodontitis.

E. B. Dosumu¹, *M. O. Arowojolu¹ and K. O. Savage²

¹Department of Preventive Dentistry, College of Medicine, U. C. H. Ibadan

²Department of Preventive Dentistry, College of Medicine, University of Lagos, Idi-Araba Lagos.

Summary

One hundred and fifty six interproximal sites, with periodontal pockets deeper than 5mm and showing loss of bone on standard dental periapical radiographs, were treated by subgingival instrumentation and open periodontal flap debridement in 12 patients properly motivated and given thorough oral hygiene instructions.

The indices of gingival condition, plaque, calculus, oral hygiene and degree of mobility with loss of attachment were measured at baseline, 1,3 and 6 months after treatment.

Standardized reproducible radiographs of the interproximal sites were taken before and 6 months after treatment. Alveolar bone levels pre and post treatment were measured with a grid in square millimetres using a view box (Watson and sons, London) and the Dunning and Leach gingival bone count index for both treatment procedures.

Radiographic analysis showed statistically and clinically significant increases in bone fill of both the superficial and deep bone defects for the surgical technique ($p < 0.05$). This study has shown that surgical procedure resulted in a better bone regeneration than subgingival instrumentation.

Keywords: Alveolar Bone, Regeneration, Surgical, Non-Surgical, Treatment, Juvenile Periodontitis.

Résumé

Cent cinquante six sites inter proximales avec des poches périodontales de la profondeur de 5mm et le modèle dental périapical radiographique et montrant la perte d'os, ils ont reçu des soins à travers l'instrumentation sous-gingivale et le lambeau debridement périodontal ouvert chez 12 patients qui ont été convenablement motivés et ont reçu des instructions d'hygiène orale. Des indices de conditions gingivales, la plaque, le calcul, l'hygiène orale, et le niveau de la mobilité avec la perte de l'attachement ont été mesurés à la ligne de fond, 1,3 et 6 mois après le traitement. Les radiographies reproductives uniformisées de sites inter proximales ont été notées avant et 6 mois après traitement. Poste et pré traitement niveau alvéolaire d'os ont été mesurés avec une grille mesurée en millimètre carrés utilisant une boîte d'observation (Watson et sons, London) et le dunning et Leach gingivite compte indices d'os pour les deux méthodes de traitements. L'analyse radiographique a statistiquement et cliniquement montré un accroissement significatif dans le remblai d'os du superficiel et défaut de la profondeur d'os les deux pour la technique chirurgicale ($P < 0,05$). Cette étude a montré que procédé chirurgical avait pour résultat une meilleure reconstitution d'os plus que l'instrumentation sous gingivale.

Introduction

A characteristic feature of juvenile periodontitis (JP) is loss of alveolar bone and the ability of *Actinobacillus actinomycetemcomitans* (Aa) to induce such bone destruction¹⁻³. Aa causes bone resorption by its surface-associated material^{1,2} (SAM) and its 62kDa membrane protein, demonstrating a molecular chapter on GroEl of *Escherichia coli* having a tissue degrading activity³ and a group of its outer membrane proteins (lipid A-associated proteins, LAP) which have been shown to be potent osteolytic agents.⁴ Another characteristic feature of JP is a reduction in gingival collagen fibre density which may be accounted for in part by

Aa collagenase production.⁵ Aa also exhibits both acid and alkaline phosphatase activity and this could contribute to bone destruction if the enzymes were to reach the alveolar bone and if they were active under the existing conditions.⁶

SAM from the organism has been shown to be a potent inhibitor of DNA and collagen synthesis by cultured murine calvarian and osteoblasts.⁷ Hence, bone resorption which is a characteristic feature of JP could result from an increased rate of bone resorption, a decreased rate of bone formation, or a combination of both.^{7,8}

Much controversy had existed regarding the most appropriate treatment of intrabony defects associated with juvenile periodontitis. Recent advances in periodontics made it possible to treat patients with JP using autogenous bone grafts,⁹ allografts¹⁰ and alloplasts.¹¹ Rosling et al¹² concluded that the different techniques used to eliminate diseased periodontal tissues in intrabony pockets resulted in the amelioration of the bony defects.

Wennstrom et al,¹³ Matchei et al,¹⁴ Sewon et al,¹⁵ Sirirat et al¹⁶ and Loprez et al¹⁷ reported better bone regeneration responses in the surgical treatment than the non-surgical treatment. No such study has been reported in Nigeria where most JP patients present late and usually with very deep pockets. This present study was undertaken to assess and compare alveolar bone fill patterns in a surgical and non-surgical treatment modalities among Nigerian JP patients.

Subjects and Methods

Subject population

Twelve adolescents, 5 males and 7 female with age ranging from 15-23 years were selected from the patient population referred to the periodontology unit of the Dental Centre, University College Hospital, Ibadan. The selection criteria were: diagnosis of JP, general good health, not having taken systemic antibiotics in the preceding 6 months, good plaque control after initial oral prophylaxis, and the presence of at least 4 pairs of teeth with interproximal intrabony defect. Clinically, the interproximal lesions were confirmed by the presence of a pocket of at least 5 millimetres (mm) and radiographically from the periapical radiographs of the sites showing vertical alveolar bone loss using the long cone paralleling technique.

Experimental design

Following examination, patients underwent initial treatment which consisted of scaling and polishing with oral hygiene instruments. The patients were motivated and they all complied to maintenance of good oral hygiene throughout the study period.

The baseline examinations included oral hygiene status (plaque index,¹⁸ calculus and oral hygiene index - simplified¹⁹ and the gingival condition status (gingival index²⁰). These measurements were repeated at 1,3 and 6 months post-treatment. Full mouth periapical radiographs were taken at baseline and 6 months after treatment. The radiographic measurements were done by two methods:

1. Using a grid made with a wiremesh in square millimetres placed on the radiographs (similar to the one used by Sirirat et al¹⁶). The radiographs were viewed on a radiograph viewer (1.5 magnification) with the grid in place and the radiographic parameters measured as done by Novak et al²¹ in millimetres (mm) were:

* Correspondence

- a. The distance from the Cemento-Enamel Junction (CEJ) to the alveolar bone crest. The CEJ was designated as that point where the outer edge of the crown intersected the outer edge of the dentine of the root. The alveolar bone crest for a specific tooth surface was identified as the most coronal point of bone adjacent to the tooth surface where the periodontal ligaments had a uniform width.
- b. The distance from the CEJ to the root apex. The root apex was identified as the most apical extent of the root surface where the root met the apical aspect of the tooth.
- c. The percentage of interproximal bone repair. Bone repair was defined as the percentage reduction in the supracrestal area between the baseline and 6 month radiograph for each lesion.

- II. Using the Dunning and Leach gingival bone count index which identifies the intrabony defect changes at the margin and at the base of the defect. The score assigned by this index ranges from zero to five (0-5) for lesions ranging from nil to complete bone loss with severe mobility respectively.

After baseline examination and initial treatment, the 77 pairs of defects in the 12 patients were randomly selected for surgical and non-surgical treatments, such that if one side (upper and lower jaws) of the patient was treated surgically, the contra-lateral side received non-surgical treatment which is basically the split mouth therapy technique.

Clinical technique

The non- surgical technique that was employed was the subgingival curettage while the surgical technique was the open flap curettage.

Sub gingival curettage was performed with fine through the lumen of the pocket and the connective tissue subjacent to the level of the alveolar crest. This procedure was done under local anaesthesia and sterility. The tissues attached between the bottom of the pocket and the alveolar crest were removed with a scooping motion of the curette to the tooth surface. The area was flushed with normal saline to remove debris, and the tissue was partly adapted to the teeth by gentle finger pressure and Peripac (Dentsply) periodontal dressing placed.

In open flap curettage, buccal and lingual fill thickness mucoperiosteal flaps were raised to expose the defects for better visibility and access. The initial incision was an internal bevel incision to the alveolar crest starting 0.5mm away from the gingival margin with scalloping following the gingival margin. Vertical releasing incisions 2-3mm long were made at each end of the initial incision. Flaps were reflected areas derided with normal saline, removing all tissue tags and granulation tissue with sharp curettes. The flaps were adapted back onto the teeth and sutured into place with interrupted direct 3.0 black silk sutures. Peripac periodontal dressing were placed and the patients were placed on capsules Tetracycline 250mg, six hourly for one week. Sutures were removed one week post-surgery. All the patients were recalled at 1,3 and 6 months post-treatment for professional tooth cleaning and polishing with oral hygiene instructions.

Data recording

The amounts of bone regeneration from the cemento-enamel junction of adjacent teeth to the base of the defect using the grid were calculated in square millimetres and the means at baseline and 6 months recorded. The Dunning and Leach gingival bone count score for each defect site was also recorded to assess the level of bone regeneration and the means for each treatment technique for all the subjects was also calculated at baseline and 6

months.

The means of the oral hygiene status and gingival condition indices at baseline, 1,3 and 6 months post-treatment were also recorded.

Statistical analysis

The student t-test was used for the measured variables in comparing the two means (Surgical and Non-surgical treatments). Analysis of variance was performed using ANOVAS which allows for the comparison more than two sample means.

Results

Table 1 represents the means and standard deviation of the oral hygiene status indices at the various periods of examination. All the patients were found to maintain remarkable improvements in GI, PI, CI and OHI-S although these indices increased at the 6 months follow-up examination.

Table 1 Means and standard deviation of the gingival condition and Oral Hygiene Status indices

Period of Examination (Months)	GI	PI	CI	OHI-S
0 (Baseline)	1.24 ± 0.45	1.50 ± 0.47	1.19 ± 0.46	2.68 ± 0.86 2.69
1	0.20 ± 0.34	0.31 ± 0.2	0.12 ± 0.14	0.41 ± 0.32
3	0.18 ± 0.15	0.42 ± 0.31	0.23 ± 0.19	0.66 ± 0.48
6	0.40 ± 0.31	0.69 ± 0.34	0.50 ± 0.28	1.18 ± 0.47

Table 2 and figure 1 represent the bone fill using the grid measured in millimetres (mm) for both treatment modalities at baseline and 6 months following treatment, while table 3 and figure 2 represent the bone fill using the Dunning and Leach gingival bone count score for both treatment modalities also at baseline and 6 months following treatment. Whilst all sites demonstrated gain in bone fill

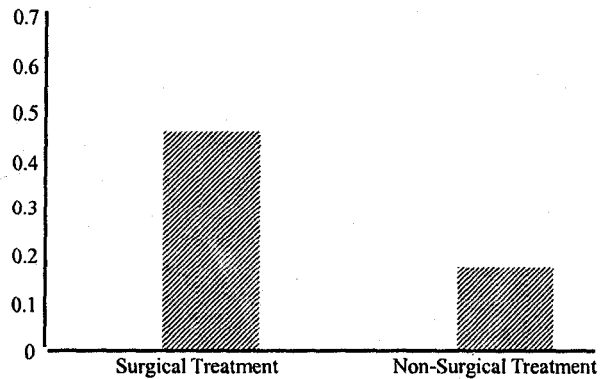


Fig. 1 Mean bone repair using the Grid

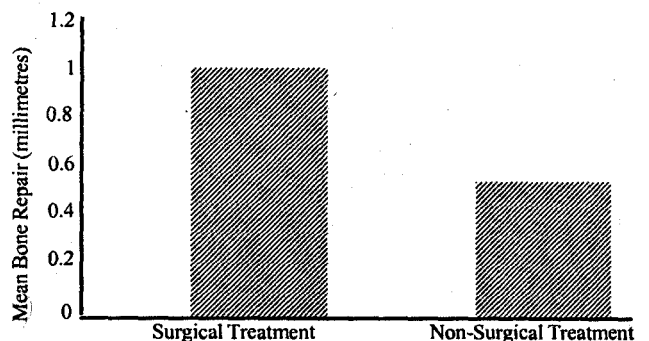


Fig. 2 Mean bone repair using the Dunning and Leach bone count score

Table 2 Changes in mean bone fill (mm) using the grid

Period of examination (Months)	Surgical treatment	Conservative treatment	P Value	Wilcoxon Statistical value	Level for significance
0	-	-	-	-	-
6	0.462 ± 0.068	0.129 ± 0.058	0.002	0	Significant

Table 3 Changes in mean bone fill (mm) using the Dunning and Leach bone count score

Period of examination (months)	Surgical Treatment	Conservative Treatment	P V alue	Level of Significance
Baseline	-	-	-	-
0	-	-	-	-
6	1.010 ± 0.33	0.568 ± 0.26	0.050	Significant

Table 4 Anova summary table for changes in mean bone repair related with Age, Gender and Types of treatment

Source of Variation	Value	Sum of Squares	Mean Squares	F Value	P Value	Level of Significance
Age	1	0.039	0.039	15.957	0.001	Significant
Gender	1	0.014	0.014	3.597	0.072	Not Significant
Type of treatment	1	0.638	0.0638	260.184	0.000	Significant

with no site losing clinical attachment following both treatment modalities, the response was better in the surgical treatment. Student t-test showed significant difference between the treatment modalities (Surgical and Non surgical) with a clinically and statistically significant improvement from the baseline and 6 months post-treatment (P<0.05). Table 4 shows that the age of the patient and the type of treatment significantly improved the mean bone repair (p<0.05) while patient's gender do not have any significant effect on it.

Discussion

Rosling et al¹¹ reported that the most favourable periodontal tissue healing potential occurs when an optimal plaque control regimen is established. In the present study all the patients maintained a good oral hygiene level, which must have been responsible for the favourable healing conditions that existed during the entire follow-up period.

Regeneration of the periodontal defect is a major goal of periodontal treatment. The results from this study demonstrate that bone regeneration occurred in the intrabony defect treated both surgically and conservatively, although more significantly with the surgical treatment. This finding is similar to those of Wennstorm et al¹³, Matchei et al,¹⁴ Sewon et al,¹⁵ Sirrirat et al¹⁶ and Loprez et al¹⁷ who also reported better response in the surgical treatment than the non-surgical treatment.

Clinically, defect repair is usually evaluated using radiographs. Findings from the study of DiBattista et al²³ showed that radiographs were a better predictor of volumetric bone fill than either probing depth or clinical attachment level even though, at best, they represented a 2-dimensional picture of a 3-dimensional defect. Despite efforts to standardize radiographs, it is difficult to avoid a small change in angulation for a minimal bone defect and therefore may alter data.

Radiographic comparison of treated sites in this study showed progressive improvement in healing over time for both treatment procedures. No signs of root resorption were noted in any of the

154 sites treated. In the treatment of intrabony defects, the number of walls generally influences the degree of bone fill. There is evidence that 3 wall defects can fill with debridement alone.²⁴

Sirrirat et al¹⁶ concluded in their radiographic analyses of bone regeneration following surgical treatment of early-onset periodontitis that sub- straction technique was superior in detecting alteration of the interproximal bone than the view box. Orthman et al²⁵ have reported that digital subtraction radiography is capable of localizing a lesion when as little as 1% to 5% of the bone mineral is lost. Jeffcoat²⁶ also reported that interpretative radiography is a relatively crude tool which does not register the alveolar bone loss or gain until 30% to 50% of the bone mineral is destroyed. The relatively low bone fill values recorded in this study could therefore be due to the fact that the view box was used to analyse the radiographs, the real amount of bone regeneration might not have been obtained as reported by Orthman et al²⁵ and Jeffcoat.²⁶

Attempts to compare the radiographic analyses of the results of this study with other reports of treatment of JP are difficult due to different methodologies.

The Anova summary as related to subject's age/gender, type of treatment and the period of examination in this study showed that the subject's gender did not have any significant effect

on the bone repair while the type of treatment, the period of examination and the subject's age significantly improved the bone regeneration. This significant effect of the subject's age could be the reason for the exemplary result reported by Mattout et al²⁷ following the conservative treatment of a 12 year old JP girl over 6 years period. The youngest age of the patients in this study was 15 years indicating a delay in presentation during which the disease would have progressed. The small number of patients may be considered a limitation in the present study.

Conclusion

Whereas much controversy exists as to the best treatment for JP, from this study we may conclude that:

- (1) Surgical and conservative treatment modalities can be used in the treatment of intrabony defects of JP;
- (2) Both treatment modalities can give improvement in bone regeneration, although more significant with surgical treatment modality;
- (3) If patients present early at about age of 12 years, the extent of the disease may be less and hence the conservative treatment technique may show an equal improvement as the surgical technique.

Recommendations

1. Dental awareness of the community should be improved to encourage early presentation by the patient.
2. All available dental facilities should be upgraded and made affordable to the patients for adequate management.
3. The type of treatment modality to be used for an individual JP patient should be determined by the extent of progress of the disease.

References

1. Wilson M, Kamin S and Harrey W.: Bone resorbing activity of purified capsular material from *Actinobacillus actinomycetemcomitans*. *J. Periodont. Res.* 1985; 484-491.
2. Meghji S, Wilson M, Barber P and Hendersen B.: Bone resorbing activity of surface associated material from *Actinobacillus actinomycetemcomitans* and *Elkenella corrodens*. *J. Med Microbiol* 1994; 41; 197-203.
3. Nair S, Kirby A, Meghji S, Wilson M and Hendersen B.: GroEl from *Actinobacillus actinomycetemcomitans* stimulates calvarial bone resorption. *J. Dent. Res.* 1995.
4. Reddi K, Meghji S, Wilson M and Hendersen N.: Comparison of the Osteocytic activity of surface - associated protein of bacteria implicated in periodontal disease. *Oral Dis* 1995; 1, 26-31.
5. Robertson PN, Lantz M, Marucha PT, Korman KS, Trummel CL and Holt SC.: Collagenolytic activity associated with bacteroides species and *Actinobacillus actinomycetemcomitans* *J periodont Res.* 1982; 17; 275-283.
6. Frank R and Voegel JC.: Bacterial bone resorption in advanced cases of human periodontitis *J. Periodont Res.* 1978; 13; 251-261.
7. Wilson M, Meghji S and Harvey W.: The effect of capsular material from *Haemophilus actinomycetemcomitans* on bone collagen synthesis in vitro. *Microbios* 1988; 54; 181-185.
8. Fletcher JM and Wilson M.: Acid and alkaline phosphatase activity of *Actinobacillus actinomycetemcomitans* *J. Dent Res.* 1994; 73; 797.
9. Sargarman MM and Sugarman EF.: Precocious periodontitis: A clinical entity and treatment responsibility. *J. Periodontol* 1977; 48: 397-409
10. Mabry TW, Yukna RA and Sepe WW.: Freeze-dried bone allografts combined with tetracycline in the treatment of juvenile periodontitis. *J. periodontol* 1985; 56: 74-81.
11. Hoexter DL and Minichetti JC.: The use of Durapatite Ceramin implant in the treatment of juvenile periodontitis. A case report. *Compendium Cont Educ Dent* 1986; 7: 458-467
12. Rosling B, Nyman S, Lindhe J and Jern B.: The healing potential of the periodontal tissue following different technique of periodontal surgery in plaque - free dentitions (A2- year clinical study), *J. Clin periodontol* 1976; 3: 233-250.
13. Wennstrom A, Wennstrom J and Lindhe J.: Healing following surgical and non-surgical treatment of juvenile periodontitis. *J. Clin periodontol* 1986; 13: 859-882.
14. Machtei EE, Zubery Y, Datz Y, Boultchin J and Ben Yeouda A.: Multiple therapy approach to juvenile periodontitis; a case report. *Quintessence Int* 1991; 22: 365-370.
15. Sewon LA.: Rapid bony healing in localized juvenile periodontitis, a case report. *Scand J. Dent Res.* 1993; 101: 371-4
16. Sirirat M, Kasetsuwan J and Jeffcoat MK.: Comparison between 2 Surgical Techniques for the Treatment of Early onset periodontitis. *J periodontitis* 1967: 603-607.
17. Loprez B, Beacin P and Cimasoni GA.: Care of localized juvenile periodontitis, treatment and 3 years follow-up with super impossible radiographs. *J Clin periodontol* 1996; 23: 557-62.
18. Silness J and Loe H.: Periodontal disease in pregnancy II, Correlation between oral hygiene and periodontal condition. *Actodontol Scand* 1964; 22: 121-135.
19. Greene JC and Vermillion JR.: The simplified oral hygiene index. *J AM Dent Assoc.* 1964; 68: 7-15.
20. Loe H and Silness J.: Periodontal disease in pregnancy I. Prevalence and severity. *Actodontol Scand* 1963; 21: 533-551.
21. Nsovak JM, Polson AM and Adair SM.: Tetracycline therapy in patients with early onset juvenile periodontitis. *J. Periodontol* 1988; 6: 59 - 66.
22. Dunning JM and Leach LB.: Gingival bone count: a method for epidemiological study of periodontal disease. *J Dent Res.* 1960; 39: 506.
23. DiBattista P, Bissada NF and Ricchetti PA.: Comparative Effectiveness of periodontitis. *J. Periodontol* 1995; 66: 673-78.
24. Prichard JF.: The infrabony technique as a predictable procedure. *J periodontol* 1957, 28-202.
25. Orthman LF, Dunford R, McHenry K and Hausmann E.: Subtraction radiography and computer assisted densitometric analysis of standardized radiographs. A comparison with 125-I absorptionmetry. *J periodont Res* 1985; 20: 644-651.
26. Jeffcoat MK.: Radiographic methods for the detection of progressive alveolar bone loss. *J. Periodontol* 1992; 63: 367-372.
27. Mattout P, Moskow BS and Fourel J.: Repair potential in LJP. A case in point. *J. Periodontol* 1990; 61: 633-660.