

# Mandibular segmental reconstruction with iliac crest

\*A. E. Obiechina, S. O. Ogunlade<sup>1</sup>, A. O. Fasola and J. T. Arotiba  
 Department of Oral & Maxillofacial Surgery and Department of Surgery<sup>1</sup>  
 University College Hospital, Ibadan  
 P. O. Box 22573, University Post Office  
 Ibadan.

## Summary

Twenty patients consisting of 14 males and 6 females with benign destructive lesions of the mandible were reconstructed using free nonvascularised iliac crest. Harvested bone was contoured and secured with 0.5mm stainless steel wire and reinforced with maxillo-mandibular fixation. Five patients has hemimandibulectomy with immediate reconstruction. The other 15 patients had 1 to 3 segments of the mandible reconstructed. There was only one failure.

Mouth opening and closure were centric except in the patients that had hemimandibulectomy without condylar reconstruction. Mastication and facial appearance were satisfactory. In conclusion, the iliac crest is recommended for reconstruction of hemimandible as well as long contiguous segments of the mandible.

**Keywords:** Mandible, Reconstruction, Iliac crest.

## Résumé

Vingt patients consistent en 14 mâles et 6 femmes atteints des lésions destructives bénignes dans la mâchoire ont été réparés tout en utilisant la crête iliaque sans vascularisée libre. L'os récolte était courbé et solide avec un fil en acier inoxydable de 0.5mm et renforcé avec une fixation maxillo-mandibulaire.

Cinq patients atteints d'hémimandibulectomie avec une réparation rapide. On a réparé 1 à 3 segments de la mâchoire des autres 15 patients. Il y avait eu un échec seulement. L'ouverture et l'hémimandibulectomie sans la réparation condylienne.

La mastication et l'aspect du visage étaient satisfaisants. En Conclusion, on dit beaucoup de bien d'iliaque pour la réparation d'hémimandible de même que des segments longs

contigus de la mâchoire. Par ce moyen, nous présentons ces deux cas.

## Introduction

Destruction of the mandible is a common occurrence with tumours affecting the jaws. The extent of destruction has often been associated with the duration of the lesion and late presentation of these lesions have been reported, resulting in the need to resect and reconstruct the damaged portions of the jaw<sup>1</sup>. Resection of part of the mandible result in functional, aesthetic and psychological disability<sup>2</sup>. These underscore the need for reconstruction, in order to reduce or eliminate these disabilities.

Several materials and methods for mandibular reconstruction have been reported. These include the use of alloplasts and autogenous bonegrafts. Alloplast materials in use include stainless steels<sup>3</sup>, titanium<sup>4</sup>, dacron urathane<sup>5</sup>, hydroxyapatite<sup>6</sup> and silastic<sup>7</sup>. Free nonvascularised graft for mandibular reconstruction include ribs<sup>8</sup>, frozen autogenous bone<sup>9</sup> and iliac crest<sup>10,11</sup>. Although iliac crest is more readily vascularised than the rib, its use has often been limited to the reconstruction of relatively short segments of the mandible.

A search through available literature on mandibular reconstruction with iliac crest revealed that only a few studies have been reported within our sub region. The aim of this study is to determine the efficacy of iliac crest bone in the reconstruction of segments of the mandible and to present our experience in the management of these cases.

## Patients and methods

Patients with benign destructive lesion of the mandible

Table 1 Distribution of reconstructed mandibular segments

No	Sex	Age	Lesion	Site (Segments of the Mandible)	No of Segments	Outcome	Follow-up (months)
1	M	18	Ossifying fibroma	Left body	1	Satisfactory	25
2	M	18	Ossifying fibroma	left body	1	Satisfactory	14
3	F	40	Ossifying fibroma	Right body	1	Satisfactory	10
4	M	40	Ameloblastoma	Right body	1	Satisfactory	4
5	M	42	Fibromyxoma	Left body	1	Satisfactory	6
6	F	27	Fibromyxoma	Left body	1	Failed	6
7	M	40	Ameloblastoma	Right body	1	Satisfactory	12
8	F	27	Ameloblastoma	Right parasymphiseal + body	2	Satisfactory	24
9	M	14	Ameloblastic fibroma	Left parasymphiseal + body	2	Satisfactory	16
10	F	26	Ameloblastoma	Left symphyseal + body	2	Satisfactory	8
11	M	15	Ameloblastic fibroma	Left symphyseal + body	2	Satisfactory	13
12	M	11	Ameloblastoma	Left body + angle + ascending ramus	3	Satisfactory	14
13	M	21	Ameloblastoma	Right body + angle + ascending ramus	3	Satisfactory	15
14	F	30	Ameloblastoma	Right body + angle + ascending ramus	3	Satisfactory	24
15	M	32	Ameloblastoma	Right body + angle + ascending ramus	3	Satisfactory	12
16	M	14	Fibromyxoma	Left Symphyseal + body + angle + ascending ramus	4	Satisfactory	18
17	M	28	Ameloblastoma	Left Sympheal + body + angle + ascending ramus	4	Satisfactory	2
18	M	23	Ameloblastoma	Right parasymphiseal + body + angle + ascending ramus	4	Satisfactory	25
19	F	22	Ameloblastoma	Right Symphyseal + body + angle + ascending ramus	4	Satisfactory	7
20	M	23	Ameloblastoma	Left parasymphiseal + body + angle + ascending ramus	4	Satisfactory	21

\*Correspondence

between January 1995 to December 2001, were selected. Under endotracheal anaesthesia, resection and immediate reconstruction of the mandible was done. Approach was extraoral in all cases. Full thickness nonvascularised iliac crest was harvested from the same side as the lesion, thus leaving the opposite side free from injury. The harvested bone was contoured and secured with 0.5mm soft stainless steel wire and reinforced with mandibulo-maxillary fixation for 4 weeks. Patients were fed through nasogastric tube for 10 days post operatively, and were also placed on prophylactic antimicrobial therapy of Ciproxacin 500mg 8 hourly and Metronidazole 200mg 12 hourly for 5 days each.

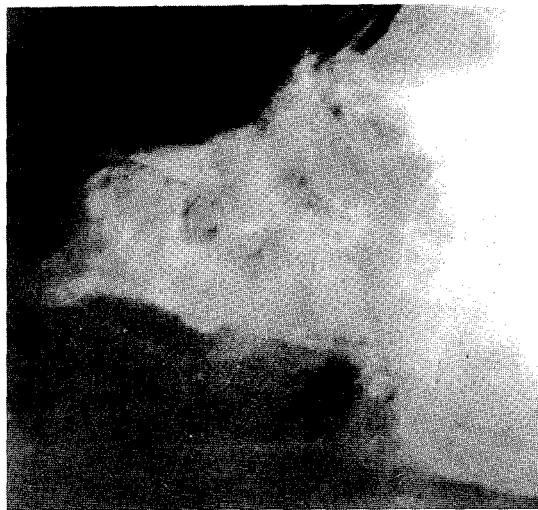


Fig. 1 Reconstruction of the symphyseal region, body and angle of the mandible.

### Results

There were 20 patients. Fourteen were males and 6 females. Their ages range from 11 to 42 years with a mean of 25.5 years, standard deviation 9.5. Thirteen patients presented with ameloblastoma, 2 ameloblastic fibroma, 3 ossifying fibroma and

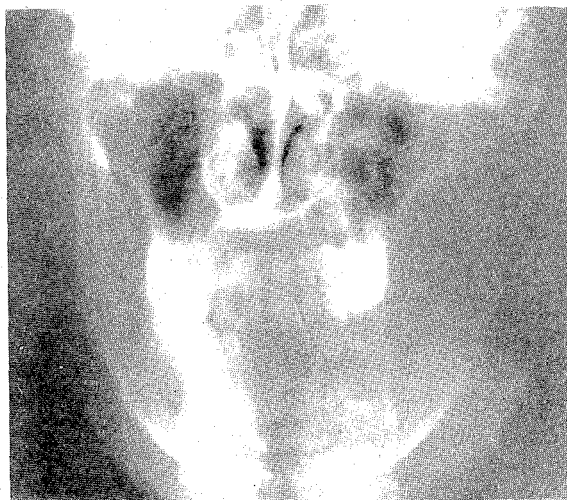

Fig. 2 Reconstruction of the hemimandible

2 fibromyxoma (Table 1).

Twenty mandibular resections with immediate reconstruction were done. In 5 patients where the lesion extended from the symphyseal region to the ascending ramus compromising the condyle, hemimandibulectomy was done. In 15 patients, 1 to 3 segments of the mandible were resected and the iliac crest was sufficient to span the defect (Figure 1). However, in 5 patients where the lesion extended from the symphyseal region to the ascending ramus compromising the condyle, hemimandibulectomy and reconstruction were done without condylar reconstruction, because the graft fell short of the glenoid fossa (Figure 2). Costochondral graft was not added to the iliac

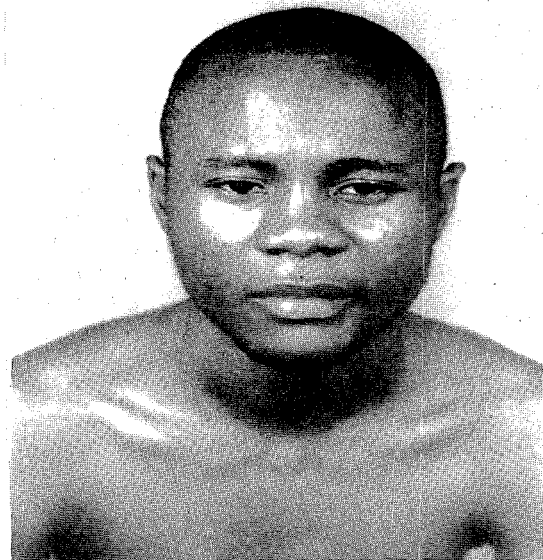


Fig. 3 Patient whose radiograph was shown in Figure 1, after reconstruction

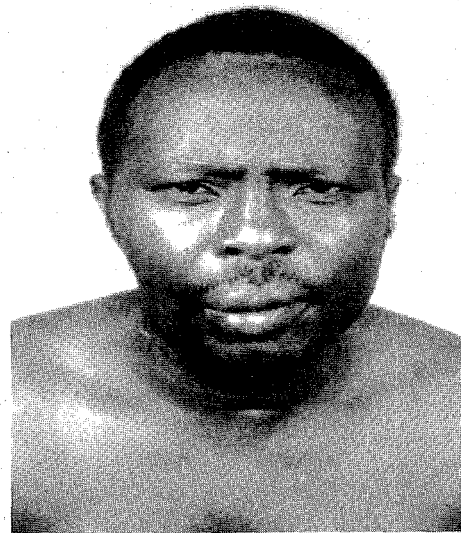

Fig. 4 Patient whose radiograph was shown in Figure 2, after reconstruction

crest because miniplates which were required for rigid fixation, were not available and affordable. There was one failure and the graft was removed after 2 weeks when antimicrobial therapy failed to control infection. Graft failure was due to wound

dehiscence and subsequent contamination and infection. In 2 patients, the gait was affected when walking, for a period of 12 days post operatively, but recovered fully thereafter. Ameloblastoma recurred in one patient after 13 months. All the patients had moderate to severe pain at donor site, after surgery. Pain improved to become mild within 10 to 14 days post operatively. None of the patients developed abnormal sensation, unsightly scar, herniation of abdominal content or permanent gait abnormality.

Mouth opening and closure were centric except in patients without condylar reconstruction. These patients had mild deviation of the mandible to the same side on full opening of the mouth. Mastication was generally satisfactory and the patients were pleased with their facial appearance and the outcome of surgery (Figures 3 & 4).

### Discussion

Ablative tumour of the mandible often causes continuity defects, which could lead to disturbances of function and aesthetics. The loss of parts of the mandible result in impaired mastication and speech. Frequently there is asymmetry of the mandible either during function or at rest, with concomitant soft tissue collapse because of loss of skeletal support. Immediate replacement of resected segment of the mandible is therefore imperative if these disabilities are to be eliminated or minimised.

Several materials available for mandibular reconstruction, and these include alloplasts and autogenous grafts. While alloplasts can effectively bridge defects and restore aesthetics and function, they are foreign to the body and are often rejected or exposed; a situation that necessitates another surgery for their removal and further reconstruction. Furthermore, they are relatively expensive. Because of the state of the economy in most underdeveloped countries, the psychological and financial stress on patients undergoing surgery is all too obvious.

Among the autogenous grafts, the rib, which consists predominantly of compact bone, has the advantage of strength and rigidity. However, this same property renders the rib relatively difficult to contour and when grafted, it takes less readily than cancellous bone. Recently, free micro vascular transfers with fibula<sup>12</sup>, radial forearm<sup>13</sup> and ilium<sup>14</sup> among others are being advocated. While the advantages of these new advances are not in question, sophisticated equipment is required and surgeons have to be adequately skilful in this area. The procedure is not readily available in several underdeveloped countries.

In consideration of these limitations, full thickness graft (cortico-medullary) of the ilium was the graft of choice, thus taking advantage of its properties. With its generous cancellous component sandwiched by compact bone, the iliac crest has both rigidity and strength, while the cancellous part enhanced the take of the graft. In 4 patients who were followed up for two years, resorption was minimal. This could be attributed to the quick integration of the graft and resistance of resorption of the compact parts of the bone. The iliac crest thus provided adequate base for denture support and the bulk of the graft seemed sufficient to support osteointegrated implant. Although dental implant was not placed in any of the grafts, the suitability of the iliac crest in securing osteointegrated implants have been reported<sup>15, 16</sup>.

Unlike most cases where the iliac crest was used to bridge continuity defect of one to two contiguous segments, we were able to bridge as much as four contiguous segments, from the symphysis to the ascending ramus in patients where hemimandibulectomy was done, contrary to the assertion by

Cordeiro *et al*<sup>17</sup> who recommended the use of fibula free flap. With the inclusion of an orthopaedic surgeon in the team it was possible to confidently harvest relatively long span of the iliac crest for reconstruction. This underscores the advantages of multi-disciplinary approach in patient management. Our results showed that the iliac crest has proved to be a good reconstruction material that was readily provided by the patient with satisfactory functional and aesthetics result. It is probably under utilised for extensive mandibular reconstruction in underdeveloped countries.

### References

1. Arotiba JT, Ogunbiyi JO, Obiechina AE. Odontogenic tumours: a 15-year review from Ibadan. *Br. J Oral Maxillofac Surg.* 1997; 38: 363 – 367.
2. Tucker MR, Terry BC, White RP, Van Sickles JE. Rigid fixation for maxillofacial surgery. Publishers: JP Lippincott Company, New York 1991 Edition.
3. Freitag V, Hell B, Fischer H. Experiment with AO reconstruction plates after partial mandibular resection involving its continuity. *J Craniomaxillofac Surg.* 1991; 19: 191 – 198.
4. Spencer KR, Sizeland A, Taylor GI, Weisenfeld D. The use of titanium mandibular reconstruction plate in patients with oral cancer. *Int J Oral maxillofac Surg.* 1999; 28: 288 – 190.
5. Cheung LK, Samman N, Tong ACK, Tideman H. Mandibular reconstruction with dacron urathane tray: a radiographic assessment of bone remodelling. *J Oral Maxillofac Surg.* 1994; 52: 273 – 280.
6. Dumbach J, Rodmeyer H, Spitzer WJ, Steinhauser EW. Mandibular reconstruction with cancellous bone, hydroxylapatite and titanium mesh. *J Oral Craniomaxillofac Surg.* 1994; 22: 151 – 155.
7. Bhatena HM, Kavarana NM, primary reconstruction of the mandible in head and neck cancer with silastic implant: a review of 69 cases. *Acta Chirurgiae Plasticae.* 1998; 40: 31 – 35.
8. Banerjee AR, Westmore GA. Free rib graft reconstruction of the mandible; a forgotten option? *Annals of Royal College of Surgeons of England.* 1995; 77: 273 – 282.
9. Dong YJ, Zhang GZ, Wang SP, Li Z. The use of immediate frozen autogenous mandible for benign tumour mandibular reconstruction. *Br. J Oral Maxillofac Surg.* 1996; 36: 58 – 61.
10. Verhoeven JW, Cune MS, Terlouw M, Zoon MAC, de Putter C. The combined use of endosteal implants and iliac crest onlay graft in the severely atrophic mandible: a longitudinal study. *J Int Oral maxillofac Surg.* 1997; 26: 351 – 357.
11. Hotz G. Reconstruction of mandibular continuity defects with delayed nonvascularised free iliac bone grafts and endosseous implants: a clinical report. *Journal of Prosthetic Dentistry.* 1996; 76: 350 – 355.
12. Bahr W, Stoll P, Wachter R. Use of "double barrel" free vascularised fibula in mandibular reconstruction. *J Oral maxillofac Surg.* 1998; 56: 38 – 44.
13. Zenn MR, Hidalgo DA, Cordeiro PG, Shah JP, Strong EW, Kraus DH. Current role of radial forearm free flap in mandibular reconstruction. *Plastic and Reconstructive Surg.*

- 1997; 99: 1012 – 1017.
14. Safak T, Klebuc MJ, Mavili E, Shenaq SM. The new design of the iliac crest microsurgical free flap without including the “obligatory” muscle cuff. *Plastic and Reconstructive Surg.* 1997; 100: 1103 – 109.
15. Schliephake H, Schmelzeisen R, Husstedt H, Schmidt-Wondera LU. Comparison of the late results of mandibular reconstruction using nonvascularised or vascularised grafts and dental implants. *J Oral Maxillofac Implants.* 1999; 57: 944 – 950.
16. Keller EE, Tolman D, Eckert S. Endosseous implant and autogenous bone graft reconstruction of mandibular discontinuity: a 12 year longitudinal study of 31 patients. *Int J Oral Maxillofac Surg.* 1998; 13: 767 – 780.
17. Cordeiro PG, Disa JJ, Hidalgo DA, Hu QY. Reconstruction of the mandible with osseous free flaps: a 10 year experience with 150 consecutive patients. *Plastic and Reconstructive Surg.* 1999; 104: 1314 – 1320.