

# Shunt-responsive dementing illness in a Nigerian – A case report

\*E. O. Komolafe, A. O. Malomo, A. Ogunniyi, M. T. Shokunbi,  
T. O. Odebode and A. A. Adeolu

Department of Surgery and Medicine,  
Obafemi Awolowo University Teaching Hospitals Complex,  
P.M.B. 5538, Ile-Ife, Osun State and  
University College Hospital Ibadan, Nigeria.

## Summary

**Dementia is a growing medico-social problem worldwide because of the rising population of the elderly. About 10–30% of the cases have been found to be treatable or reversible with the improvement in neuro-diagnostic and neuro-imaging techniques. These reversible cases should be diagnosed without over-investigating the many patients with irreversible disease.**

**We present a case of a reversible dementia due to Normal Pressure Hydrocephalus with dramatic surgical therapeutic response.**

**Keywords: Dementia, Hydrocephalus, Treatable.**

## Résumé

La démence est un problème médecine-social partout dans le monde entier à cause d'augmentation de la population des vieux. On a appris qu'on peut soigner environ 10–30% des cas ou bien réversible avec l'amélioration du neuro-diagnostic et des techniques néuro-imagings.

On devrait diagnostiquer ces cas réversible sans trop faire l'enquête des beaucoup de patients atteints de la maladie irréversible.

Nous présentons un cas de la démence réversible attribuable à la pression Normale Hydrocephalus avec la réponse de la chirurgie thérapeutique dramatique.

## Introduction

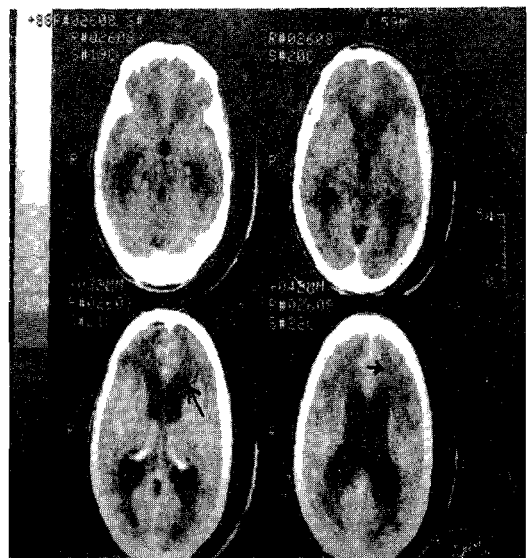
Dementia is defined as global impairment in higher cerebral functions sufficient to impair the activities of daily living in the conscious and alert state. It is a rising medico-social problem globally because of the rapid increase in the population of the elderly as a result of longer life span who are at increased risk of developing the condition<sup>1</sup>. It imposes considerable strain on family members who have to provide care and prevent injuries. The financial implication (both direct and indirect costs) is also huge especially when young individuals are affected. In the United States of America, for instance, the cost of care was estimated at over 113 billion US dollars in 1992 alone<sup>1</sup>. About 10–30% of the cases of dementia have been found to be treatable or reversible with the improvement in neuro-diagnostic and neuro-imaging techniques<sup>2</sup>. Therefore, every effort must be made to look for treatable causes to save costs on the long run and ensure meaningful existence for those that might be otherwise condemned to have hopeless illness.

Recently, we successfully managed a 58-year-old Nigerian patient who had a dementing illness, due to normal pressure hydrocephalus (NPH), which hitherto had not been reported in this environment. The clinical features and management are presented in this communication.

## Case report

I. D (903746) is a 58-year-old right-handed male teacher

who presented in September 1998 with a two-week history of difficulty with walking, urinary incontinence, confusion, difficulty with speaking and vomiting. There was a history of a fall without loss of consciousness during which he sustained a bruise on his forehead prior to the presentation. He had noticed urinary frequency, hesitancy, nocturia and feeling of incomplete voiding one year previously but urological assessment was normal. In October 1997, he started noticing difficulty with concentration and recall of events. He neither took alcohol nor smoked cigarettes. He had a past medical history of recurrent vertigo, hearing loss and tinnitus diagnosed as Meniere's disease in the Ear-Nose-Throat Clinic of the University College Hospital, Ibadan in 1995. The condition responded to perchloperazine (Stemetil) and vitamin supplements. In May 1997, he presented to the neurologist for the first time with simple partial sensorimotor seizures involving the left upper limb and face. The problem had been on going for about six months and the episodes recurred weekly. Examination revealed bilateral sensorineural deafness without other localizing features. The Interictal electroencephalography was normal as well as the serum electrolytes, urea, creatinine, HIV status, full blood count, clotting profile and chest radiograph. His brain computerised tomography (CT) scan was reported to be normal. He was commenced on phenobarbitone 180mg per day, which was later changed to carbamazepine (100mg nocte for the first 3 days then 200mg nocte daily) by the neurologist after confirming the partial nature of the seizure attacks and ruling out structural lesion in the CT scan. In addition, moduretic (Hydrochlorothiazide with amiloride) was prescribed for the elevated blood pressure. From February 1998, his seizures, which were hitherto well controlled on medications, became more frequent and were



**Fig. 1 Pre-operative Cranial CT Scan showing gross ventriculomegaly and transependymal CSF seepage (arrow).**

\*Correspondence

associated with loss of consciousness with injuries.

Assessment on August 29, 1998 revealed normal orientation in terms of time, place and person. Calculation, judgement and abstraction were found to be normal but the patient had impaired recent memory and spastic gait changes were noticeable. A possible diagnosis of vascular dementia was entertained. On admission one week later, he was unable to walk and he was aphasic. He was therefore investigated to exclude a chronic subdural haematoma as a result of the previously documented falls and trauma to the head region.

A repeat cranial CT Scan (Fig. 1) showed multiple hypodense area bifrontally suggestive of small infarcts. The lateral and third ventricles were dilated with evidence of transependymal CSF leakage suggesting hydrostatic hydrocephalus. Neurosurgical evaluation was suggestive of possible improvement following a cerebrospinal fluid (CSF) diversion based on the above CT scan findings and the relative clinical improvement after CSF tap via lumbar puncture.

He subsequently had a ventriculo-peritoneal (V-P) shunt inserted with dramatic improvement in his clinical and neurological status by the third post-operative day. The spastic gait and cognitive impairment (i.e. short term memory) virtually disappeared. He had no repeat seizures since surgery, while still on his anticonvulsants. He no longer had urinary incontinence. Serial follow-up clinic attendance showed steady and sustained improvement. He had since gone back to his job.

## Discussion

The syndrome of dementia is of grave significance as it usually reflects progressive degenerative disease that threatens the very integrity of the patient. Moreover, dementia occurs in the setting of many neurological disorders necessitating a broad differential diagnosis and wide ranging investigations. In this group of patients, the clues to the diagnosis and direction of subsequent investigations are usually provided by the additional neurological abnormalities picked during the clinical assessment<sup>1</sup>. The proportion of reversible dementia identified is increasing with the improvement in neuro-diagnostic and neuro-imaging modalities. Most of the cases that were thought to be hopeless are now found to be treatable with the identification of specific treatable aetiology<sup>1</sup>. When the dementia syndrome is identified, the patient must be thoroughly investigated for treatable causes of the intellectual impairment. Potentially reversible disorders (e.g. chronic subdural haematoma, cerebral tumours, hypothyroidism, alcohol or substance abuse, depression, heavy metal poisoning and thiamine and other vitamin deficiencies) will be found in 10–30% of all demented patients, and illness in which treatment may significantly alter the course of the behavioural and neuro-psychologic deterioration occur in another 20–40%<sup>2</sup>. Other causes of reversible dementia are well enumerated by various authors<sup>1,2,7,8</sup>.

Treatable disorders will result in permanent dementia unless an accurate diagnosis is made and appropriate treatment offered. For every new case of dementia, efforts should be made to fully investigate these patients particularly to confirm or rule out a treatable condition. The treatment of the reversible dementia is directed at the identified aetiology. In the case reported, the diagnosis of normal pressure hydrocephalus (NPH) was made. However, before the classical features of NPH develops, most patients present with features referable to other central nervous system states such as depression, mass effects, psychosis<sup>3</sup> and in this case, seizures.

Also, for accurate diagnosis, in addition to the clinical features and basic laboratory tests, a cranial CT scan should at least be done, however, small infarcts such as those in Binswanger's disease<sup>5</sup> are clearly better visualised with magnetic resonance imaging (MRI)<sup>6</sup>.

The delay in the diagnosis of the case presented was due to the relative expensive cost of the CT and the patient's poor income level. This also reflects the inability to get post-operative CT scan done. However efforts should be made, if clinically indicated, to get a cranial CT scan done, as the diagnosis of the dementia may be primarily surgical<sup>7,8</sup>.

The difficulty posed to the surgeons is the selection of patients that will benefit from CSF diversion when the diagnosis is NPH. The present consensus is that when there is a short history, a known cause of hydrocephalus, predominance of gait disorders, and CT or MRI suggesting hydrodynamic hydrocephalus, about 50–70% will do well after surgery<sup>9</sup>. However, in situations where access to ancillary investigations with a high predictive accuracy is limited, the reasonable next step would be a therapeutic trial. In this case, continuous external lumbar CSF drainage for four to five days could help in such decision making and to shunt only patients with an unequivocal clinical improvement<sup>9</sup>.

In conclusion, painstaking clinical evaluation is the mainstay of diagnosis in dementia but auxiliary tests are indispensable to detect potentially reversible causes. Accurate aetiological diagnosis is crucial in the subsequent management and the diagnosis of irreversible or permanent dementia should be by exclusion.

## References

1. Ogunniyi A. Dementia. Review Article. Nigerian Journal of Medicine 1999; 8: 47 – 53.
2. Cummings JL. Treatable Dementias In: Mayeux R, Rosen WG (Eds). The Dementia Raven Press new York 1983.
3. Pinner G, Johnson H, Bouman WP, Isaacs JC. Psychiatric Manifestations of Normal – Pressure hydrocephalus. A short review and unusual case. International Psychogeriatrics 1997; 9: 465 – 470.
4. Rossor MN. Management of Neurological Disorders: Dementia Journal of Neurology, Neurosurgery and Psychiatry 1994; 7: 1451 – 1456.
5. Roman GC. Senile Dementia of the Binswanger Type. A vascular Form of Dementia in the Elderly JAMA 1987; 258 : 1782 – 1788.
6. Corey-Bloom J, Thal LJ, Galasko D, Folstein M, Drachman D, Raskind M, Lanska DJ. Diagnosis and evaluation of dementia 1995; 45: 211 – 218.
7. Nakai K, Umezawa H, Kohyama S, Ohtani N, Ono K, Katoh E et al. Dural Arteriovenous Fistulas Presenting as Acute Onset Dementia: A case report. No Shinkei Geka – Neurological Surgery 1997; 25: 349 – 54.
8. Datta NN, Rehman SU, Kwok JC, Chan KY, Poon CY. Reversible Dementia One to Dural Arteriovenous Fistula: A simple Surgical option. Neurosurgical Review 1998; 21: 174 – 6.
9. Editorial: Three Decades of Normal Pressure Hydrocephalus. Are we Wiser Now? Journal of Neurology, Neurosurgery and Psychiatry 1994; 57: 1021–1025.