

Delayed primary realignment of posterior urethral rupture

*O. B. Shittu, L. I. Okeke, T. B. Kamara and S. A. Adebayo

Division of urology, Department of Surgery
College of Medicine, University of Ibadan and University College Hospital
Ibadan, Nigeria.

Summary

The treatment of acute posterior urethral rupture is controversial. Twelve patients who presented with acute posterior urethral rupture over a five-year period were treated by delayed primary realignment of the injury. The technique of this procedure and the outcome are the subject of this presentation. Eight patients had successful realignment without strictures. Two patients with strictures responded to simple dilatations with bougies and the other two had formal urethroplasty.

Keywords: Urethral rupture, Delayed realignment, Posterior urethra.

Résumé

Le traitement de l'éclatement aigu d'urètre postérieur est controversé. Douze patients atteints de l'éclatement aigu d'urètre postérieur au cours d'une période de cinq ans ont été soignés grâce au ré-alignement retardé premier de la blessure. La méthodologie de ce protocole et le résultat sont l'objet de cet étude.

Huit patients avaient connu une réussite à travers le ré-alignement sans des rétrécissements. Deux patients avec des rétrécissements ont réagit au dilatation simple avec des bougies et les deux autres avaient l'uréthroplastie formelle.

Introduction

The treatment of posterior urethral rupture is controversial. There are those who do suprapubic cystostomy only and wait, believing that passing a urethral catheter might introduce infection or might convert a partial rupture into a complete rupture. On the other hand there are those who do an emergency urethrogram or pass a urethral catheter and if either of these suggest a urethral rupture, realign the urethra immediately by one means or the other¹.

Patients who suffer posterior urethral disruption from severe injuries often have other associated injuries involving intra-abdominal structures, pelvic bone and bones of the extremities. Attempts at immediate exploration of the retropubic space to try and realign the urethra often lead to considerable blood loss and significant morbidity and mortality². Delayed primary realignment of posterior urethral rupture has therefore been advocated, because as at the time of exploration, the patient's general condition has usually improved and pelvic haematoma can be evacuated without the bleeding starting all over again, but fibrosis has not yet set in and the urethral ends are still mobile. As these are rare injuries and because most patients who sustain these injuries rarely present to the urologist acutely, it is difficult for any single urology unit to accumulate enough cases for randomization.

Aim of the study

The aim of the study is to find out the outcome of pa-

tients who sustained posterior urethral rupture and were managed by delayed primary realignment.

Materials and methods

All suitable patients who presented with posterior ure-

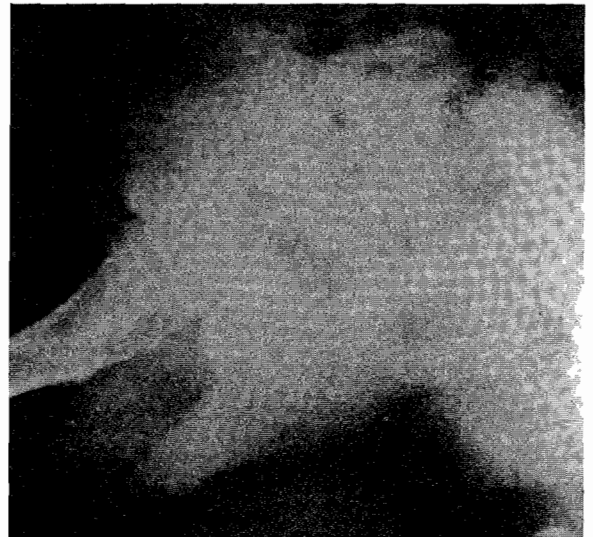


Fig. 1 Pre-operative retrograde urethrogram showing posterior urethral rupture and contrast extravasations into pelvic haematoma.

thral rupture in the accident and emergency department of the University College Hospital Ibadan between February 1994 and January 1999 were enrolled prospectively into the study. Patients with intra-peritoneal rupture of the bladder were excluded. The events that lead to the injury were recorded along with the patient's bio-data. The patients were resuscitated as demanded by the extent of their injuries. A retrograde urethrogram (RUG) was performed with a water-soluble contrast medium in all patients with full aseptic technique. An ultrasound examination of the kidneys, ureters and the bladder was done to assess the upper tracts. Where indicated, an intravenous urography (IVU) was performed. In those in whom the RUG confirmed a complete rupture of the urethra (Fig. 1), a suprapubic cystostomy is performed and the patient left on continuous drainage. All patients had antibiotics administered during the interval before delayed realignment, consisting of cefuroxime and gentamicin. The realignment is done when the patient is fairly stable and between 10 days and two weeks after the injury.

At surgery, the retropubic space was explored through a mid-line sub-umbilical incision in all cases. The organising haematoma was evacuated and the extent of injury to the urethra ascertained. The bladder is opened anteriorly between stay sutures through the previous cystostomy site and a well lubricated curved (antegrade) bougie passed through the bladder neck into the distal end of the ruptured urethra. This bougie was

*Correspondence

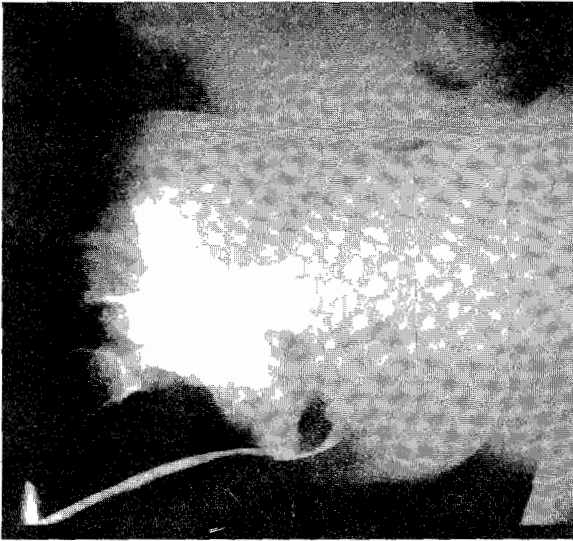


Fig. 2 Post-operative peri-catheter urethrogram outlining the entire urethra without extravasations of contrast.

then manipulated out of the external urethral meatus where a size 14 silastic foley catheter was then tagged onto it (the curved bougie has an 'eye' at the tip). The bougie is then withdrawn back into the bladder, drawing the catheter along with it. The balloon of the catheter was then inflated. The bladder was then subsequently closed over a suprapubic catheter, which was connected for continuous drainage of urine. The urethral catheter was spigotted and used essentially as a splint.

On the 21st post-operative day, a pericatheter urethrogram was performed. If there is no extravasation of contrast as shown in Fig. 2, the urethral splint was removed and the suprapubic catheter occluded. The suprapubic catheter was removed completely once the patient has voided well. The urinary flow rates were then measured and patients discharged to be followed up in the outpatient clinic.

Results

During the period of the study, 12 suitable patients were seen with multiple injuries that included posterior urethral rup-

Table 1 Mode of injuries

Hit by a vehicle
Passenger in a vehicle (RTA)
Crushed by a log of wood
Fall off a moving vehicle
Gored by cow horn
Ran over by a vehicle

Table 2 Additional injuries

Extra-peritoneal bladder rupture
Fractured pubic bone
Cerebral concussion
Rib fractures
Haemothorax
Clavicular fracture
Radial bone fracture
Knee fracture
Ankle fracture
Scrotal rupture
Scrotal haematoma
Perineal perforation

ture. The age ranged between 17 and 55 years with the mean age of 31.58 years.

The source of injury was usually violent and the mode ranged from vehicular accident to vicious attack from a bull (table 1). Most of the patients sustained additional injuries apart from the urethral rupture as shown in (table 2).

Ten patients, or 83% of the patients had pubic bone fracture. Two patients had been catheterised per urethram, by the casualty officer before being seen by the urologist on call. These two patients however only drained scanty amount of blood via the urethral catheter, apparently because the catheters did not enter the bladder. The patients were explored between the 10th and 14th day post injury with the exploration being performed on average on the 12th day.

One patient had extra-peritoneal rupture of the bladder in addition to the posterior urethral rupture. Five of the patients did not require any blood transfusion, either before or during exploration. Four patients had one unit each of blood transfusion while two had two units each of blood transfusion. One patient, who was crushed severely by a truck required a total of 10 units of blood.

There was no mortality recorded in any of these patients. After the urethral catheter was removed, 8 patients could void well straight away with very good flow rates of 18 to 28mls/second and a mean flow rate of 21ml/second. Two patients required calibration with bougies on a single occasion, when a 13/16 Lister bougie could be passed without difficulties following which they could pass urine well. One of these patients subsequently passed a bone-fragment through the urethra. Two other patients did not respond to repeat dilatation and they subsequently had urethroplasty performed. Two patients developed erectile dysfunction (impotence). Period of follow-up ranged between 15 months and 6 years.

Discussion

The management of posterior urethral rupture continues to be quite controversial. Immediate exploration and realignment may minimise the incidence of stricture formation³, but could provoke severe bleeding and necessitate transfusion of significant amount of blood that may not be readily available in our environment. The incidence of impotence is also reported to be higher⁴.

The patient could have a suprapubic diversion in the acute phase of the urethral rupture and later have a formal urethroplasty done to treat the almost inevitable urethral stricture that would develop if he had suffered a complete urethral rupture^{5,6}.

This option provides little or no control over the extent of the stricture that may be formed following the injury. Where extensive, subsequent management can be difficult and may necessitate multiple operations and recurrent strictures^{7,8}.

Delayed primary realignment has been advocated as a middle-of-the road course between the two options earlier mentioned¹. As at the time of exploration, the patient's general condition has usually improved and pelvic haematoma can be evacuated without the bleeding starting all over again, but significant fibrosis has not yet formed and the urethral ends are still mobile. A splinting catheter is usually left across the realigned area of rupture to serve as a scaffold over which epithelial continuity can be re-established without resorting to use of sutures as had been attempted in the past⁹.

In recent times, a third option of management has been introduced, and that is early endoscopic realignment. This

method is reported to be able to re-establish urethral continuity without increased incidence of impotence, stricture formation, or incontinence. It is also reported that in case of failure, endoscopic realignment does not compromise the result of secondary urethroplasty¹⁰. Radiological assessment is quite important to confirm that there is a urethral rupture before embarking on exploration, as there may be pelvic fractures and significant distraction without urethral rupture¹.

Before catheter removal, it is important to assess the area of injury for complete healing with a pericatheter urethrogram. Where extravasation of contrast can be demonstrated, it is advisable to leave the catheter for a little longer, to allow this area to heal completely. If the patient could not void well in the immediate period after catheter removal, it is advisable to do a urethral calibration with a bougie as there may be a mild stricture or foreign body obstruction of the urethra, as demonstrated by one of our patients. We have found the option of delayed primary realignment quite satisfactory as the procedure rarely lasts more than 90 minutes and bleeding is usually quite minimal. The need for blood transfusion was minimal. Only one of our patients needed more than two units of blood. There was also no mortality recorded in any of these patients during the period of the study.

Two of our patients are impotent since after their injuries. The cause of impotence following these injuries is probably multi-factorial. Some people believe it is due to neuro-vascular damage caused by the pelvic fracture and distraction at the time of primary accident, while some others believe it is due to the injury inflicted during attempts at repair. It should be noted however that there may be up to 30% impotency rate even where these injuries are managed primarily by endoscopic techniques¹¹. All our patients have been continent of urine. In a follow up period of 6 years, all our patients who could void well after catheter removal have been able to maintain adequate flow rates. Two patients, who could not pass urine immediately after urethral catheters were removed, presumably from strictures, have responded to simple dilatation. Two of our patients who did not respond to this simple measure have had urethroplasty performed with good outcome.

Delayed primary realignment of posterior urethral rupture is an effective and safe method to treat posterior urethral rupture in our environment.

References

1. Mundy AR. Urodynamic and Reconstructive surgery of the lower urinary tract Churchill Livingstone, publishers, 1993; Pgs 242 – 244.
2. Peters PC, Sagalowsky AI. Genitourinary trauma. In: Walsh PE, Gittes RF, Perlmutter AD and Stamey TA (Eds.) Campbell's Urology, 5th Ed. Philadelphia. WB Saunders Co., 1986, pgs 1192 – 1246.
3. Myers RP, Deweerd JH. Incidence of stricture following primary realignment of the disrupted proximal urethra. J Urol. 1972; 105: 265.
4. Aboutaieb R, Sarf I, Dakir M, el Moussaoui A, Joual A, Meziane F, Benjelloun S. Surgical treatment of traumatic ruptures of the posterior urethra. Progress in urology. 2000; 10: 58 – 64.
5. Pierce JM Jr. Management of dismemberment of the Prostatic-membranous urethra and ensuing stricture disease. J Urol. 1972; 107: 259.
6. Yasuda K, Yamanishi T, Isaka S, Okano T, Masai M, Shimazaki J. Endoscopic re-establishment of membranous urethral disruption. J Urol 1991; 145: 977.
7. Waterhouse K, Laungani G, Patil U. The surgical repair of membranous urethral strictures: experience with 105 consecutive cases. J Urol. 1980; 123: 500.
8. Corriere JN. I-Stage delayed bulboprostatic anastomotic repair of posterior urethral rupture: 60 patients with 1-year follow-up. J Urol; 2001; 165: 404.
9. Mitchell JP. Injuries to the urethra. In: Dudley H and Carter D (Eds.): Rob and Smith's Operative Surgery (Urology) 4th Ed. Butterworths. 1986. Pgs. 473 – 479.
10. Moudouni SM, Patard JJ, Manunta A, Guiraud P, Lobel B, Guille F. Early endoscopic realignment of pos-traumatic posterior urethral disruption. Urology 2001; 57: 628.
11. Jepson BR, Boullier JA, Moore RG, Parra RO. Traumatic posterior urethral injury and early primary endoscopic realignment: evaluation of long-term follow-up. Urology, 1999; 53: 1205.