

Testicular torsion on the Jos Plateau

*B. T. Ugwu, N. K. Dakum, S. J. Yiltok, N. Mbah, J. N. Legbo,
A. F. Uba, K. S. Orkar and V. M. Ramyil

*Department of Surgery
Jos University Teaching Hospital, Jos, Nigeria.*

Summary

In order to determine the pattern and the factors that influenced outcome, we retrospectively studied fifty-seven patients with torsion of the testis admitted to the Jos University Teaching hospital between August 1993 and July 2001. The age ranged from 2 to 55 years with a mean of 22.7 years. Majority (79%) of the patients were in the second and third decades of life. The main suspected precipitating factors in this study were cold weather and scrotal trauma; in 28% of the cases no cause could be ascertained. Eight (14%) patients presented within 4 hours and 35 (61%) presented after 24 hours of the onset of symptoms. Both sides were equally affected. Testicular pain, retraction and scrotal swelling were the most common presenting complaints. The highest incidence (65%) occurred between November and February when the weather on the Jos plateau is coldest. At surgery, 34 (60%) patients were found to have associated congenital anomalies; in 22 (39%) patients, the testis was non-viable. There was no mortality in this series and the complications were superficial wound infection (14%), testicular atrophy (7%) and sub-fertility (16%). High index of suspicion in a patient with acute scrotum, prompt and effective surgery will improve testicular salvage.

Keywords: *Testicular torsion, Early diagnosis, Prompt and Effective surgery.*

Résumé

Afin de décider la tendance et des facteurs qui influencent les résultats, nous avons rétrospectivement étudié cinquante sept patients atteints de la torsion admis au centre hospitalo-universitaire de Jos entre août 1999 et juillet 2001. La tranche d'âge étaient dans la deuxième et la troisième décennie de leur vie.

Des facteurs les plus précipitamment présumés dans cet étude étaient temps froid et traumatisme scrotal, dans 28% des cas on ne peut pas déterminer aucune cause. Huit soit 14% des patients se sont présentés en moins de 4 heures et 35 soit 61% se sont présentés après 24 heures du début des symptômes. Le deux côtés sont également concernés. Douleur du testicules rétraction et la bosse scrotale étaient des plaintes les plus fréquentes. La fréquence la plus élevée 65% est arrivée entre novembre et février quand le temps sur la plateau de Jos est trop froid. Pendant la chirurgie 34 soit 60% des patients étaient déjà atteints des anomalies congénitales, chez 22 soit 39% des patients, les testis étaient non-viables. Il n'y a aucun cas de la mortalité dans cette série et des complications sont des blessures d'infections superficielles 14%, atrophie du testicule 7% et sous fertilité 16%. Indice très élevé des soupçons chez un patient atteint du scrotum aigu, la chirurgie efficace et rapide vont améliorer des efforts de sauver le testicule.

Introduction

Testicular torsion was first reported in literature more than one and a half centuries ago by a French surgeon Delasiauve in 1840¹. It occurs in every society, and no age, climate or social status is exempt. The clinical presentation has remained fairly stable within this period, and so a high index of suspicion is the key to early diagnosis. Prompt and effective surgical treatment will ensure testicular salvage. Despite this, literature is awash with reports of delayed presentation, mis-diagnosis and unnecessary delay in offering adequate surgical treatment, leading to testicular wastage and/or subfertility^{1,2,3,4}.

In the temperate region testicular torsion occurs mostly in the second decade, as opposed to the tropics where it is known to affect young men between 20 – 29 years of age range². The reported precipitating factors include sudden drop in temperature, trauma to the scrotum, coitus and straining^{2,5}. However, in some patients, it occurs spontaneously. Some of the torsed testes harbour some congenital anomalies⁶.

The most common presenting features are sudden onset of scrotal and abdominal pain as well as vomiting. The testis is usually retracted and tender.

Some of the differential diagnoses are epididymo-orchitis, scrotal haematoma and strangulated inguino-scrotal hernia-all of which could be eliminated by diligent clinical examination. Ancillary imaging techniques such as ultrasonography⁷ may occasionally be required. In view of the possible teratogenic effects of radiation on the testis, the use of radiation and radioisotopes for diagnosis is controversial.

Time is of cardinal importance in achieving testicular salvage¹⁻⁵. Permanent damage may be done to the germinal epithelium after 4 hours of ischaemia, while the Leydig cells responsible for sex hormones may be irreparably damaged after eight hours^{2,4}. Therefore we set out to identify the pattern and factors that influenced outcome in the management of this disease on the Jos Plateau.

Materials and methods

The study analysed retrospectively cases of testicular torsion at the Jos university Teaching Hospital between August 1993 and July 2001. A total of sixty consecutive patients with acute scrotum (testicular pain of sudden onset) were explored during this period with a working diagnosis of testicular torsion. Three patients at surgery were found to have haemorrhaging testicular tumour and were excluded from this study.

The information obtained from the hospital records of the fifty-seven patients with testicular torsion were analysed for demographic data, clinical features, operative findings, treatment and outcome.

Results

During the 8-year period of this study, a total of 57 cases of testicular torsion were seen, with an age range of 2 to 55

*Correspondence

Table 1 Duration of symptoms at presentation

Duration of symptoms (Hours)	No. of Patients	Percentage (%)
Less than 4 hours	8	14%
4 – 24 hours	6	10.5%
More than 24 hours	43	75.5%

Table 2 Clinical features

Testicular pain	100%
Lower abdominal pain	91.2%
Vomiting	28.1%
Retraction of the testis	87.7%
Scrotal swelling	66.7%
Increased pain on scrotal elevation (Prehn's sign)	70.2%
Horizontal contralateral testis (Angel's sign)	73.4%
Palpable Twisted Cord (Denim's sign)	8.8%

years, and a mean of 22.7 years. Twenty-one (36.8%) patients were teenagers, while 24(42%) were between 20 and 29 years. All the social strata were involved, but the majority (59.6%) were students. Seventy--seven percent of the patients were single. In thirty seven (64.9%) patients it occurred between November and February, the coldest period on the Jos Plateau. In 4(7%) patients, the suspected trigger was trauma. Eight (14%) patients presented within 4 hours, 6(10.5%) cases between 4

Table 3 Associated congenital anomalies

Anomalies	No	Percentage (%)
High tunica investment	12	21%
Long mesorchium	10	17.5%
Inversion of testis	4	7%
Cryptochidism	8	14%

and 24 hours while 43 (75.4%) cases presented after 24 hours of onset of symptoms as shown in Table 1. The main clinical features are as listed in Table 2. It affected the right testis in 27 (47.4%) patients, the left in 26 (45.6%) and was bilateral in 4 (7%). Eight (14%) of the patients had unilateral cryptorchidism. General anaesthesia was used in 34 (59.6%) patients, local infiltration with plain 1% lignocaine in 21 (36.8%) patients and spinal anaesthesia was used in 2(3.5%) patients.

The degree and the duration of torsion were recorded in only 28(50%) of the patients: one complete twist in 16 pa-

Table 4 Site affected

Affected area	No of patients	Percentage (%)
Right testis	27	47.4%
Left testis	26	45.6%
Bilateral	4	7%

tients; one and a half twists in 6, two twists in 4, and two and half twists in 2 patients. In every one of these cases, the torsion was recorded as rotation away from the scrotal septum. The testis was viable in 35 (61.4%) patients and non-viable in 22 (38.6%). Orchidopexy was performed on all viable testes, as well as on the contralateral normal testes; orchidectomy was done for all non-viable testes.

Thirty-four (59.7%) patients had associated congenital testicular anomalies noted at surgery and these included high

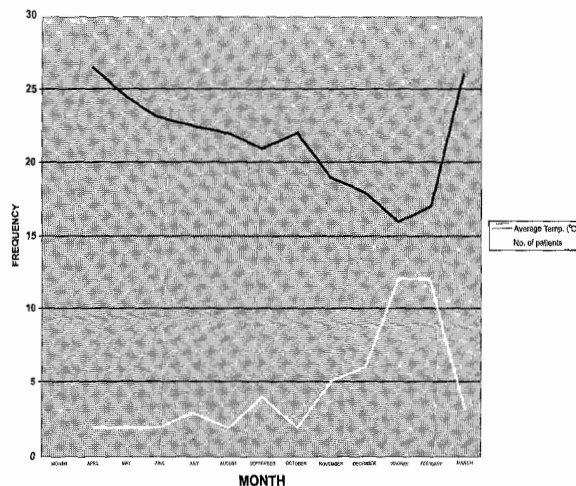


Fig. 1 Line graph showing relationship between average temperature and frequency of testicular torsion

tunica investment in 12 (21%) patients, long mesorchium in 10 (17.5%), and inversion of the testes in 4(7%) patients; eight (14%) other patients had cryptochidism. Ten (17.5%) patients were managed as day case procedure and the duration of hospitalisation for the remaining 47 (82.5%) was between one and eight days with a mean of 3.2 days.

The complications recorded were superficial wound infection in 8 (14%) patients, testicular atrophy in 4 (7%) and subfertility in 9 (15.8%) patients.

Thirty (52.6%) patients were followed-up for between 3 and 36 months. Ten patients consented to semen analysis; 9 of these patients had presented more than four hours after onset of symptoms and were subfertile with semen count of between $4 \times 10^6/ml$ and $8 \times 10^6/ml$.

Table 5 Types of anaesthesia

Method	No of patients	Percentage
General anaesthesia	34	59.6%
Local infiltration (Lignocaine)	21	36.8%
Spinal anaesthesia	2	3.5%

Discussion

Torsion of the testis is a world wide surgical problem affecting mostly adolescents and young men, though no age is

Table 6 Complications

Causes	No of patients	Percentage
Superficial wound infection	8	14%
Testicular atrophy	4	7%
Sub-fertility	9	15.8%
No-complication	36	63.2%

exempt²⁻⁶. In temperate climates, the incidence is highest amongst teenagers but reports from the tropics show that the incidence peaks between the 20 – 29 years age range. On the Jos Plateau however, the incidence in this study shows almost equal distribution between the 10-19 years and 20 –29 years age ranges. In all, adolescents and young men aged between 10 and 29 years made up 79% of all the cases in this study. All the social strata were affected though students constituted about 60% in this series; this risk group has also been identified by other workers^{2,3}.

The Jos Plateau stands more than 35000 feet above sea level and is peculiar for its temperature gradients. The temperature usually falls from an average of 28° Celsius between the months of March and October to as low as 11° Celsius between November and February. The temperature fluctuations could vary widely. About 65% of patients with testicular torsion presented between November and February as illustrated in fig. 1 and the incidence dropped sharply after the cold weather. It has been observed that these patients when exposed on the operating table, had markedly contracted scrota with prominent rugae. The sudden drop in temperature leads to contraction of the cremaster muscle in an upward and outward direction -- away from the scrotal septum. In 28 (50%) patients in whom the direction of torsion was recorded at surgery, they were all twisted laterally away from the scrotal septum. In four (7%) patients scrotal trauma was the trigger. In this study, both sides were equally affected.

The clinical features of testicular torsion (testicular pain, retraction and scrotal swelling) have remained almost stable over the centuries since the first report in 1840 by Delasiauve¹ and so with a high index of suspicion, diagnostic accuracy should be high especially in areas of depressed economy where modern gadgetery may not be available. None of our patients had doppler^{7,8} or radio-isotope imaging studies¹ as these were not available. The effects of radio-isotopes and radiation on the gonads of adolescents and young men make the place of these investigations controversial. Unnecessary scrotal explorations during the eight-year period of this study were reported in three patients who were confirmed at surgery and histologically as cases of haemorrhaging testicular tumours. These three patients were excluded from the study. The policy of promptly exploring every patient with acute scrotum even under local lignocaine infiltration, if need be, even if only to rule out testicular torsion, has been recommended by other workers²⁻⁴.

Only eight (14%) patients presented within four hours of onset of their symptoms- a period known for complete testicular recovery. Forty-three (75.4%) patients, resented after 24 hours. The severity of the pain associated with testicular torsion often compels patients to seek help early. The problem is misdiagnosis²⁻⁵ at the various levels of health facilities in our environment as well as by the recourse to unorthodox healers by some of these patients.

Twenty two (39%) patients had orchidectomy due to non-

viable testes giving about 61% testicular salvage rate in this series. Once the diagnosis of testicular torsion is entertained, only the most basic laboratory investigations such as the packed cell volume (PCV) and urinalysis may be required before scrotal exploration and this could be done under local anaesthesia with good sedative analgesia. This protocol saves time and thus improves testicular salvage. A total of twenty three (40%) patients were successfully explored under local or spinal anaesthesia. Most of the patients with testicular torsion were young and otherwise fit and so could be managed as day case procedure. Ten (18%) patients were managed as day cases in this study.

It would appear that majority of the torqued testicles harboured defects either in their development or descent which acted as predisposing factors to torsion²⁻⁶. We recorded a total of thirty four (60%) patients with congenital testicular anomalies and eight (14%) others with cryptorchidism.

External manual derotation was not employed in this series. It is a manoeuvre which is usually directed medially towards the scrotal septum - a manipulation reported by others^{2,3,4,5,9} to be of value. External manual derotation may improve the pain if the manoeuvre is successful, but as it is a blind procedure, it will not indicate if derotation is complete, and surely could not prevent recurrence. This view is shared by other workers¹⁰. We suspect that external manual derotation should be acceptable if it is done to gain time while waiting to get the theatre ready.

Oedema of the testis may be extensive and at surgery, the unwary may be confused as to which pole of the rotated testis should be superior. After complete derotation of a viable testis, the appendicis testis is the guide to the upper pole of the testis. In all the patients in this study, the derotated testis was fixed with fine atraumatic monofilament non-absorbable sutures at three or four points that would not allow rotation. The contralateral testis was also similarly fixed at the same surgery. There was no recurrence in our series unlike the experience of others^{10,11,18}. The tunica vaginalis should be opened and inverted before fixation of the testis as this enhances the formation of adhesions and stability of the testis¹⁸.

There was no mortality and the complications recorded were superficial wound infections, testicular atrophy and subfertility. Follow-up was poor. Only thirty (52.6%) patients could be followed up for between three and thirty-six months; four of them had ipsilateral testicular atrophy. There is a correlation between the duration of preoperative ischaemia and the ultimate testicular size though early reduction does not absolutely prevent the development of testicular atrophy³⁻⁴. Also only 10(18%) patients consented to semen analysis, nine of whom had orchidopexy performed on them more than 24 hours after the onset of symptoms and they were all subsequently subfertile with severe oligospermia. The other patient had a normal sperm count and differentials and had presented less than four before surgery. Time is of great importance in the surgical management of testicular torsion^{4,5,12,13-17,19}. After 4 hours of testicular ischaemia sufficient damage is inflicted on the affected testis enough to result in atrophy^{4,14}. Some workers have recorded sterility rate of 6% as a result of testicular torsion^{13,14}. Prolonged testicular torsion results in germinal cell ischaemia and necrosis. The products of the ischaemic germinal cells could act as antigens and thus stimulate immunological response against the affected as well as contralateral testes. Men with unilateral torsion have subsequently been reported to be subfertile even when they were offered orchidopexy early^{13,14}. We suspect that subfertility is not only related to the duration

of torsion but also to the degree of ischaemia. Ischaemia is directly related to the degree of twisting on the spermatic cord. A patient with a complete twist of the spermatic cord may be subfertile within a few hours of torsion while another with an incomplete twist of a longer duration may retain his fertility. In our community where a man's ability to sire a baby is highly rated and even influences his place in the land ownership system, infertility leaves the patient with a social stigma. Should the examining surgeon be in doubt, he should urgently seek the review of the patient by a more experienced senior surgeon while getting all the arrangements ready for emergency scrotal exploration at the earliest possible time^{20,21}. Identification of the group at risk, early diagnosis and prompt effective surgery will improve testicular salvage. Sustained public enlightenment and continuing medical education for physicians and primary health workers aimed at considering the possibility of testicular torsion in young men with acute scrotum, will go a long way in halting the ongoing testicular wastage^{12,15,16,17}.

References

1. Delasiauve L.J.F. Descente tardive du testicule gauche, prise pour une hernie étranglée. *Rév. Méd. Fr. Etran.* 1840; 1: 363.
2. Osegbe DN. Testicular torsion. *Medicine Digest* 1989; 15: 3 – 10
3. Lawani J. Torsion of the testis. *The Ibadan Surgeon* 1997; 1: 23 – 27.
4. Thomas WEG, Williamson RCN. *Diagnosis and outcome of testicular torsion.* *British Journal of Surgery* 1983; 70: 213 – 216.
5. Russel RCG, Williams NS, Bulstrode CJK editors. *Torsion of the Testis.* In Bailey and Love's Short Practice of Surgery, 23rd ed. London: Arnold, 2000: 1272 – 1273.
5. Caesar RE, Kaplan GW. Incidence of bell-clapper deformity in an autopsy series. *Urology* 1994; 44: 114 – 116.
7. Hamm B. Sonography of the testis and epididymis. *Andrologia* 1994; 26: 193 – 210.
8. Rodriguez WC, Rivera JJ et al. Doppler ultrasound versus testicular scanning in the evaluation of the acute scrotum. *Journal of urology* 1981; 125: 343 – 346.
9. Nkposong EO. Torsion of the testis in Ibadan: Report of 31 cases and review of literature. *Ghana medical Journal* 1972; 11: 252 - 255.
10. Osegbe DN, Amaku EO. Torsion of the testis in Nigerians. *Afr. J. Med. Sci.* 1982; 10: 97 – 105.
11. Thurston A, Whitaker R. Torsion of the testis after previous testicular surgery. *British Journal of Surgery* 1983; 70: 217.
12. May RE, Thomas WEG. Recurrent torsion of the testis following previous surgical fixation. *British J. Surgery* 1980; 67: 129 – 130.
13. Williamson RCN. Death in the scrotum: testicular torsion. *New England Journal of Medicine* 1977; 296: 338.
14. Sanjuan-Rodriguez S, de-Sande-Medel F, Molina-Ferbandez M, Gimeno-Benitez R, Miro-Arias A. Immunological response to testicular torsion. Experimental study on rats. *Actas Urol. Esp.* 1994; 18: 249 – 252.
15. Krarup T. The testis after torsion. *British Journal of Urology*; 1978; 50: 43 – 46.
16. Osegbe DN, Ogunkua O, Magoha GA. Testicular torsion rate in Nigerians. *Trop. Geogr. Med* 1987; 39: 372 – 375..
17. Editorial: Castration by neglect. *British Medical Journal* 1972; 1: 128.
18. Sells JJ, Moretti KL, Burfield GD. Recurrent torsion after previous testicular fixation. *ANZ J. Surgery* 2002; 72 46 – 48.
19. Cummings JM, Boullier JA, Sekhon D, Bose K. Adult testicular torsion. *Journal of Urology* 2002; 167: 2109 – 2110.
20. Corbett HJ, Simpson ET. Management of the acute scrotum in children. *ANZ Journal of surgery* 2002; 72: 226 – 228.
21. Hegarty PK, Walsh E, Corcoran MO. Exploration of the acute scrotum: a retrospective analysis of 100 consecutive cases. *Ir. J. Med. Sci* 2001; 170: 181 – 182.