

## **Eradicating Female Genital Mutilation: Case Series Evaluating the Effect of the Interventions**

**A S Adeniran\***

*University of Ilorin Teaching Hospital,  
Nigeria*

*E-mail: [acrowncord@hotmail.com](mailto:acrowncord@hotmail.com)*

**A P Aboyeji**

*University of Ilorin Teaching Hospital,  
Nigeria*

*E-mail: [abidunpeter@yahoo.co.uk](mailto:abidunpeter@yahoo.co.uk)*

**O R Balogun**

*Surulere Medical Center, Ilorin,  
Nigeria*

*E-mail: [ybalogun07@yahoo.com](mailto:ybalogun07@yahoo.com)*

**M A Ijaiyai**

*University of Ilorin Teaching Hospital,  
Nigeria*

*E-mail: [munirijaiya@yahoo.com](mailto:munirijaiya@yahoo.com)*

---

*Paper accepted on 17 November 2014*

### **Abstract**

Female genital mutilation (FGM) remains a source of abuse to females despite efforts to eradicate it. We present a cases series of two clitoral cysts and one each of post-mutilation haemorrhage, labial adhesion and excess crural flap. One of the victims intended to circumcise her daughters for cultural reasons but rescinded the decision after counseling and education. FGM is a continuing abuse, individual perception does not depend on the degree of complication experienced and there is need for increased education and enlightenment on its dangers.

**Keywords:** Female Genital Mutilation, Eradication, Interventions

**Running title:** Eradication of Female Genital Mutilation

*\*For correspondences and reprints*

## **1. INTRODUCTION**

Female genital mutilation (FGM) is the partial or total removal of the female external genitalia for non-medical reasons (Rashid et al., 2007); it is also called female circumcision/ cutting. It is performed from neonatal period to just prior to marriage (Cook et al., 2002) and remains a potential morbidity to females. However, there is paucity of reports to evaluate the effect of efforts by organizations and governments. FGM is prevalent in Africa, parts of Middle East and Asia and culture remains the commonest reason; others include controlling female sexuality, guaranteeing female virginity till marriage or the belief that a narrow opening heightens male sexual pleasure and fertility during coitus (WHO 2004). Its complications include haemorrhage, infection transmission, urinary retention, keloid, labial adhesion, clitoral cyst, psychological disorders (Brady, 1999), acquired gynaetresia and obstructed labour (Kasim et al., 2002) while mortality has been recorded (Koluchr, 2004). This report is a case series of four complications following FGM and the attitude of the victims to it.

### **Case Presentations**

#### *Case 1*

A three month old female baby was brought by the mother with history of bleeding from the external genitalia following circumcision. The procedure was performed by a local circumciser and facilitated by the paternal grandmother. The mother had declined an earlier request by the paternal grandmother for the circumcision but her husband did not comment on the request. Examination revealed a partially amputated clitoris with an actively bleeding blood vessel. Haemostasis was secured by ligating the bleeding vessel, antibiotics, analgesics and immunization against tetanus infection. The mother was circumcised in childhood but was not planning to circumcise her daughter; the couple was Muslims.

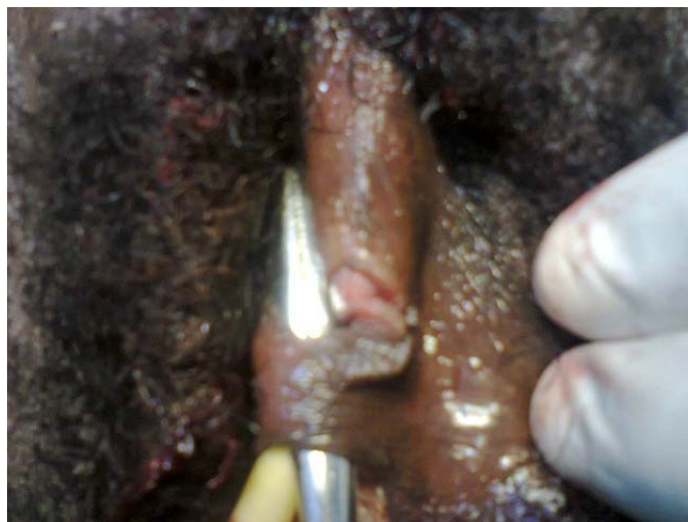
#### *Case 2*

A 14 year old premenarchial Junior Secondary School student presented with three years history of a painless, progressive vulva swelling with no associated abdominal pain or swelling. She was circumcised as a neonate; a Christian and had two female siblings who were circumcised but without complaints.

Examination revealed appropriate female sexual characteristics, abdominal examination was normal; pelvic examination revealed a partially amputated clitoris with excess left crura flap overlying a normal external urethral meatus and an intact hymen. The diagnosis was post-circumcision left crura skin flap. She and her mother were counseled, consented and had vulvoplasty. She expressed her decision not to circumcise her daughter.

### *Case 3*

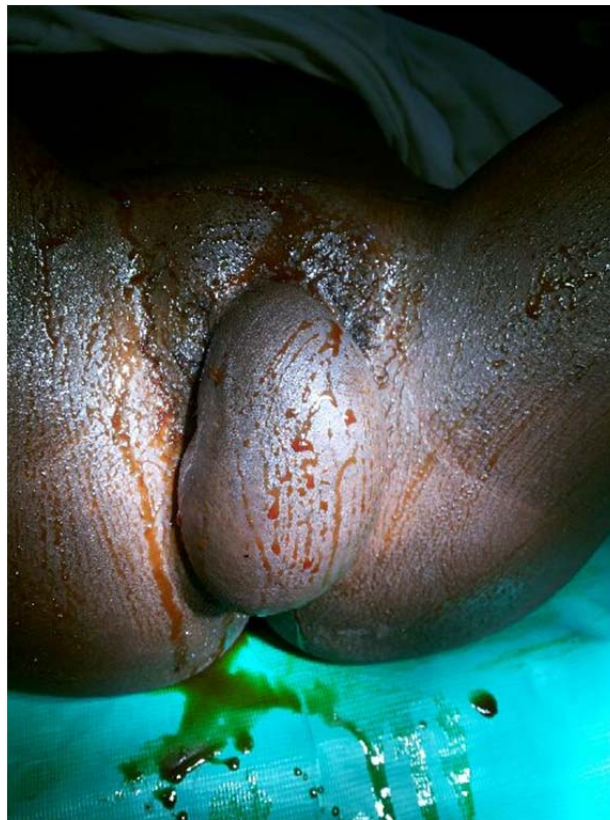A 25years old Para<sup>0+0</sup>, single Christian lady presented with history of passing urine from two orifices during micturition since childhood. There was no history of dysuria, frequency or urinary incontinence. She was circumcised in infancy and had two female siblings who were circumcised with no complaints. Menarche was 15years, had secondary school education, sexually active with no dyspareunia. General and abdominal examinations were normal. Pelvic examination showed a partially amputated clitoris with adhesion of the labia minora at the midline measuring 2cm anterior to the external urethral meatus with defects above and below the adhesion (Figure 1), other parts were normal. The assessment was labial adhesion complicating type II female genital mutilation. She was counseled, consented and had separation of the adhesion; the wound healed satisfactorily. She expressed her decision not to circumcise her daughter.



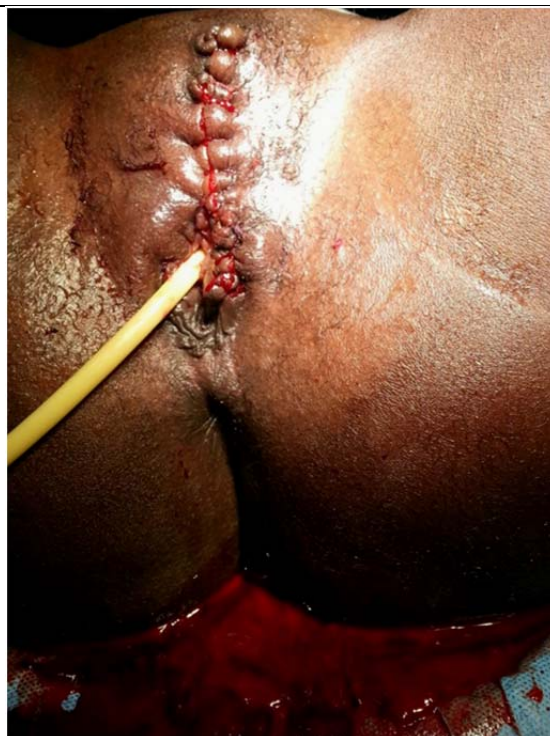**Figure 1:** Labial adhesion with artery forceps passing through the opening above and below the adhesion site

*Case 4*

A 25-year-old single para<sup>0+0</sup> Muslim lady presented with a progressive, painless vulva swelling of eight years duration; there was no vagina discharge or abdominal swelling. She was single, sexually active with no dyspareunia, circumcised in infancy and had two circumcised siblings with no complication. She completed primary education and was an apprentice seamstress. Pelvic examination showed a distorted vulva anatomy with a deviation to the left side due to a central oval mass occupying the anatomical position of the clitoris. It measured 15x10cm, soft, non-tender with normal overlying skin (Figure 2); other parts were normal. The assessment was a huge clitoral cyst following type I female genital mutilation. She was counseled, consented and had excision of the clitoral cyst and vulva reconstruction (Figure 3) with no complications. She expressed her desire to circumcise her daughter because she perceived it as a compulsory cultural act. However, after education and counseling, she rescinded the decision.



**Figure 2:** Huge clitoral cyst complicating female genital mutilation



**Figure 3:** Appearance of the vulva after excision of clitoral cyst and vulva reconstruction

## 2. DISCUSSIONS

This case series show that FGM is an ongoing abuse despite effort to eradicate it by government and support agencies. A 75% disapproval for its continuation suggests a positive effect of the eradication efforts; however, the 25% approval is disturbing since participants were victims of FGM. An extrapolation of the possible percentage of women without complications who may want to circumcise their daughters will reveal the potential magnitude of the abuse. The magnitude of the complication may not be a predictor of the attitude as the patient with the largest clitoral cyst approved of FGM. Also, older mutilated women remained proponents of FGM seeing it as essential in the identity of women and girls (Annas, 1996) as seen in case 1. Studies showed that 14.6% of pregnant women in Jos Nigeria (Dattijo et al., 2010), 84% of Somali refugees (Mitike et al., 2009) and 4.5% of women in Burkina Faso (Karmaker et al., 2011) planned to circumcise their daughters. Fikrie in 2010 reported that continuation of FGM was higher among Muslims but reduced with level of education and

increased access and exposure to the media although these were not reflected in this series. The indifference of men to FGM was demonstrated in case 1, this requires intervention because men are the head and decision-maker for homes in Africa and their indifference may signify an approval. This underscores the need for a renewed effort at obtaining the support of men towards eradication of FGM in Africa. In Africa, countries are categorized into those with laws specifying prohibition of FGM with varying punishments (Benin Republic, Egypt); those with no specific prohibiting law but existing criminal provisions for offences can be applied (Mali, Cameroon) and those with no law specifying prohibition (Nigeria, Sierra Leone) (Rahman et al., 2000). In Nigeria, the federal government publicly opposes FGM but made no legislation but a few states have legislations banning the act (Rahman et al., 2000). In Kwara State, Nigeria, there is no legislation against FGM but efforts at its eradication has been in form of jingles on the electronic media, were distribution of posters and collaboration at community level in partnership with non-governmental and other organizations. A systematic review showed paucity of high quality evidence regarding the effectiveness of interventions to prevent FGM and their insufficiency in drawing conclusions with a call for additional studies (Denison et al., 2009). Therefore, there is need for greater efforts at enlightenment and education towards the eradication of FGM.

### **3. REFERENCES**

- ANNAS, C.L (1996). Irreversible error: the power and prejudice of female genital mutilation.
- J Contemp Health Law Policy **12**: 325-353.
- BRADY, M (1999). Female genital mutilation: complications and risk of HIV transmission.
- AIDS Patient Care STDs **13**: 710-716.
- COOK, R.J., DICKENS, B.M. & FATHALLA, M.F (2002). Female genital cutting (Mutilation/ Circumcision): Ethical and Legal dimensions. Int J Obstet Gynecol **79**:281-287.

DATTIJO, L.M., NYANGO, D.D. & OSAGIE, O.E (2010). Awareness, perception and practice of female genital mutilation among expectant mothers in Jos University Teaching Hospital, Jos, North-Central, Nigeria. *Niger J Med* **19(3)**:311-315.

DENISON, E., BERG, R.C., LEWIN, S. & FRETHEIM, A (2009). Effectiveness of Interventions designed to reduce the prevalence of female genital mutilation/ cutting. Norwegian Knowledge Center for Health Sciences, Oslo.

FIRKIE, Z (2010). Factors associated with perceived continuation of female genital mutilation among women in Ethiopia. *Ethiop J Health Science* **2(1)**: 49-53.

KARMAKER, B., KANDALA, N., CHUNG, D. & CLARKE, A (2011). Factors associated with female genital mutilation in Burkina Faso and its policy implications. *J Equity in Health* **10**:20.

KASIM, Y.M., ABDUL, I.F. & BALOGUN, O.R (2002). Female Genital Mutilation and Reproductive Outcome. *Nig J Med* **11(3)**: 105-107.

KOLUCHR B (2004). Female genital mutilation: Disabling women and disabling society. *Disabling World* **23**: 124-129.

MITIKE, G. & DERESSA, W (2009). Prevalence and associated factors of female genital mutilation among Somali refugees in eastern Ethiopia: a cross-sectional study. *BMC Public Health* **9**: 264.

RAHMAN, A. & TOUBIA, N (2000). *Female Genital Mutilation: A guide to laws and policies worldwide*. Zed Publishers, London.

RASHID, M. & RASHID, M.H (2007). Obstetric management of women with female genital mutilation. *Obstet Gynecol* **8**: 95-101.

WORLD HEALTH ORGANIZATION (2004). Fact sheet No. 241. Female Genital Mutilation.

WHO Press, Geneva.