

Antifertility potential of the extracts of *Aloe barbadensis* Miller on the testes and reproductive hormones of male rats

Sekegor, C. O.^{1*}, Ekpenyong, J. F.², Udoh, P. B.² and Udoh, F. V.³

¹Department of Biology Education, School of Sciences, Delta State College of Education Mosogar

²Department of Zoology and Environmental Biology, Faculty of Biological Sciences, University of Calabar, Calabar

³Department of Pharmacology, Faculty of Basic Medical Sciences, University of Calabar, Calabar.

*Corresponding author: Crecentia Sekegor. crescentiaojenikoh.sekegor@descoem.edu.ng

Received: 18 November, 2023

Revised: 15 December, 2023

Accepted: 31 December, 2023

Keywords: *Aloe barbadensis*, Reproductive hormones, Testes, Male antifertility.



© 2023 Zoological Society of Nigeria



This is an Open Access article distributed under the terms of Creative Commons Attribution License 4.0 (CC BY-NC-SA)

Introduction

Fertility regulation comprising contraception and management of infertility forms an important component of reproductive health. Fertility regulation agents are drugs that control fertility and are also called oral contraceptives. The antifertility substance is deemed to be active in females when it prevents fertilization, ovulation, and implantation and destroys the zygote or causes abortion. In males, it prevents spermatogenesis, inhibits testosterone or affects the gonadotropin of the organs (Daniyal and Akram 2015).

Though considerable progress has been made in the development of highly effective, acceptable and reversible methods of contraception among females, progress and possibilities on males are still slow and limited (WHO 2018). With recent progress towards a better understanding of male reproductive physiology, there is a need to develop new contraceptive modalities for males.

In the world, several medicinal plants have been associated with anti-fertility properties in male and female individuals. Even though many indigenous plants have been shown to prevent birth, only a few plants have so far been studied for anti-fertility activity. Some of these plants had spermicidal effects; others caused

Abstract

There is a plethora of effective female contraceptives with varied efficacy, usability, and acceptability levels but not for males, who have condoms with a high failure rate and vasectomy with poor reversibility. This study was to determine the antifertility potential of the extracts of *Aloe barbadensis* as a herbal contraceptive for males. Gel and aqueous leaf extracts of *Aloe barbadensis* were administered orally to thirty-five sexually matured albino male rats for 30 days, to determine their effects on the reproductive hormones and histopathology of the testes. The animals were divided into 7 groups A, B, C, D, E, F, and G. Each group was for a treatment regimen having 5 rats. Group A, the Control, was given a normal ration and water. Groups B, C, and D were administered 10mg/kg, 30mg/kg, and 70mg/kg of fresh *A. barbadensis* gel daily for 30 days while groups E, F, and G were administered 10mg/kg, 30mg/kg, and 70mg/kg of aqueous leaf extract respectively. A significant reduction in testosterone levels ($p < 0.05$), insignificant reduction in follicle-stimulating hormone levels, and an increase in luteinizing hormone levels that were also not significant ($p > 0.05$) were observed. Histopathological alterations of disrupted cytoarchitecture, absence of Leydig cells, and scanty spermatozoa in the lumen of seminiferous tubules were observed in the tissues of the testes of the treated groups of rats, and as such the extracts may be possible effective natural antifertility agents for males although, toxic constituents of the plant extracts should be screened out before it is allowed for consumption.

reduction in the sperm counts and altered the mobility of the sperms. Some of them caused testicular changes and altered hormone levels (Joshi *et al* 2011).

Few researchers have investigated and reported the antifertility effect of *Aloe barbadensis* like anti-androgenic activity of extract of the leaves on male dogs (Dixit and Joshi 1983), impairment of fertility (Lang 1993) and so have advised precaution in the use of *Aloe vera* plant as well as the deleterious effect of the aqueous leaf extract of *A. barbadensis* on the testis of Sprague-Dawley rats that caused a reduction in testicular weight, sperm count and motility (Oyewopo *et al* 2011). On the other hand, 60mg/kg body weight of *A. barbadensis* powder was observed to enhance the rate of fertility and litter size of rabbits (Iwu 2014). It reported that the extract of *A. barbadensis* influenced reproductive functions in animals (Ahmadi *et al* 2012).

Increased levels of blood testosterone and cholesterol by the ethanolic extract of *A. barbadensis* have also been reported which could be the possible mechanism of action for its aphrodisiac property (Erhabor and Idu 2017). The hydro-alcoholic extract of *Aloe vera* increased the number of stem cells and primary spermatocytes significantly in all the treatment groups of 50, 100, and 200mg/kg doses. Testosterone was increased, while Luteinizing hormone and Follicle-

stimulating hormone did not show significant changes (Modaresi and Khodadadi 2014).

It has been reported that stem cells and primary spermatocytes showed the highest apoptosis under androgen deprivation (Lee 2001). Researchers have shown undesirable effects of free radicals on reproductive activity and fertility of sperms. These radicals caused failures in natural activity of cells if they are not controlled permanently. Immunity from pathological and cytotoxic lesions have a positive effect on spermatogenesis trend and transition from germ cells to mature sperm cells. Considering that flavonoids and A, C and E vitamins of *Aloe vera* can reduce free oxygen radicals, it can support sperm production and health against oxidative stresses.

In a study on the effects of pharmaceutical plants on the male reproductive system, it was observed that the gel of *A. vera* had high spermatogenic activity, increasing sperm parameters like sperm numbers and testis weight (Cross *et al* 2002). *Aloe vera* extracts can affect spermatogenesis directly via its effects on germinal cells and the stimulation of their physiological activity and cell division. The extract can also affect spermatogenesis indirectly via the stimulation of Leydig cells and increase in testosterone (Modaresi and Khodadadi 2014).

Although some contraceptives have been developed from plant extracts, their potentiality has not been determined precisely. In addition, their mode of action has been due to challenges in identifying the active portion of the plant extract used for the development of the herbal contraceptives. Studies on the antifertility effect of the leaf extract of *A. barbadensis* on male gonads have been reported (Dixit and Joshi 1983; Lang 1993; Oyewopo *et al* 2011) but in these studies, no attempts were made to investigate the effect of the gel alone on the male reproductive efficiency. This research is an attempt to investigate the effects of *A. barbadensis* gel and aqueous extract of the leaf on male fertility regulation of albino rats.

Worldwide there are several plants associated with antifertility properties in males and females. The search for a potent, safe and less expensive method of contraceptives that require infrequent and self-administration with long-lasting but complete reversible antifertility effect could become a reality if biologically active botanical substances or fertility-regulating agent of plant origin is explored.

This research was to determine the more potent of the extracts, gel or the leaf extracts of *A. barbadensis* Mill. as a herbal fertility regulating agent on male albino rats which is the gap recognized from other researches by investigating their effects on the testes, and the reproductive hormones of male albino rats.

Materials and methods

Aloe barbadensis collection

Aloe barbadensis plant was obtained from the Botanical Garden of the University of Calabar, Calabar and was identified based on the name tag on the plant with the assistance of Mr. Frank Okpopoye of the University of Calabar Botanical Garden, Calabar, Cross River State.

Phytochemical screening of *Aloe barbadensis* plant

The extracts of the plant were screened for the presence of phytochemicals as described by Sofowara (1993) and Ebana *et al* (2015).

Preparation of gel and aqueous leaf extract

The fresh leaves of *A. barbadensis* were washed with running tap water to remove impurities. The preparation of the gel was according to the methods of Ejoba (2012) with little modifications as stated thus: the gel in the leaves was removed daily by cutting the leaf with a blade. Thereafter, the gel was scraped off with a spatula into a clean beaker and ground with a laboratory mortar and pestle. Whatman No. 1 paper was used to filter the gel to remove lumps and leaf particles. The filtrate was measured with and administered to experimental animals using an orogastric tube.

The leaves after the removal of the gel were cut into bits and then ground in a mortar. After filtration, the filtrate was measured and administered to experimental animals using an orogastric tube.

Experimental animals

Thirty-five sexually mature male albino rats of the Wistar strain were procured from the Pharmacology Department, Medical School, University of Calabar, Calabar. The rats were acclimatized for ten days with feed and water *ad libitum* in a hygienic, well-lit, and ventilated animal house of the Department of Zoology and Environmental Biology, University of Calabar, Calabar. The rats weighed 118–131g and were about 11–12 weeks old.

Experimental protocol

The rats were divided into 7 groups of 5 rats each and kept in well-ventilated cages labeled A to G at room temperature in the animal house of the Department of Zoology and Environmental Biology, University of Calabar, Calabar. Group A was the Control and was given their normal ration of rat chow (Vital Feeds Nigeria Limited) and water using the method of Saritha and Anilakumar (2010). Group B, C, and D were given orally 10, 30 and 70mg/kg of fresh *A. barbadensis* gel daily for 30 days, respectively with an orogastric tube. Groups E, F and G were given orally 10, 30 and 70mg/kg of the aqueous leaf extract of *A. barbadensis* for 30 days, respectively. The doses were decided after acute and sub-chronic toxicity testing to estimate LD₅₀ of the gel and aqueous leaf extract of *A. barbadensis*.

Animal sacrifice and tissue removal

Permission was sought from the Research Ethical Committee of the Faculty of Biological Sciences of the University of Calabar, in line with the Directive 2010/63/EU on the protection of animals for scientific purposes before the experimental rats in each group were sacrificed 24 hours after the 30th day of treatment administration. The rats were sacrificed using ketamine peritoneal injection as anesthesia. They were dissected, the testes removed and fixed in Bouin's fixative.

Histopathology

The organ used for histopathology was the testes. The paraffin embedding procedure was adopted for this

research (Carson 2007). The steps in paraffin embedding used were dehydration by passing them through increasing concentrations of ethanol (30%, 50%, 70%, and 100%) for an hour in each concentration. Clearing of the tissues was done in xylene for 1 hour. Embedding was carried out by placing them in warm paraffin wax and allowing them to cool. After cooling, the hardened tissues were cut into thin slices of between 2 and 5µm thick with a SearchTech Rotary Microtome SKD – 202A and placed on slides. The slides were put in a hot air oven at 60°C for 1 hour. The tissues were then passed through xylene and then rehydrated by passing them through decreasing strengths of ethanol (100%, 90%, 80%, 70%, 50% and 30%) and finally over running water for 5 minutes.

The tissues were stained in Hematoxylin for 2 minutes and then placed under running tap water for 5 minutes, counter-stained with Eosin for 30 seconds and then transferred quickly into 60% ethanol (10 dips of 1 dip per second). The slides were then transferred to 70%, 80%, 90%, and 100% ethanol in the same manner of 10 dips each. They were then blotted with tissue paper and cleaned one after the other before they were put into xylene for 5 minutes and cover slips were put on the slides immediately to prevent the sections from drying out from xylene. The prepared slides were then examined under a light microscope, Nikon Model Eclipse E100LED MVR.

Estimation of sex hormones

Quantitative determination of testosterone, Follicle-Stimulating Hormone (FSH) and Luteinizing Hormone (LH) was done using commercially available ELISA 96-test kit (Enzo Life Sciences PA) for testosterone and FSH and LH ELISA kit (Eagle Biosciences INC., Nashua).

Data analysis

Descriptive statistics was used to analyze the data. Graphs were used to show the means of the hormones at different concentrations of the gel and leaf extract. Analysis of variance was used to test for significant differences in hormone levels at the different doses of *Aloe barbadensis* gel and leaf extract. Chi-square was used to test for significant differences between the gel and leaf extract in the parameters examined.

Percentage increase or reduction in the levels of hormones investigated was also calculated thus: Difference between control and experimental/control * 100

Results

Phytochemical screening of *Aloe barbadensis*

The qualitative analysis of the gel and aqueous leaf extract of *A. barbadensis* are presented in Table 1. The results showed that both test substances contained different bioactive compounds, which include tannins, saponins, flavonoids, alkaloids, quinones, glycosides, and cardiac glycosides in addition to terpenoids, phenols, amino acids, steroids, and phytosteroids. Alkaloids were of equal levels in both the gel and leaf extract of the plant while the highest level was recorded for saponins in the aqueous leaf extract.

Hormonal assay

Testosterone

Testosterone values were greatly reduced in all the male albino-treated rats as shown in Table 2 (about 85% reduction). There were no significant changes between the doses for gel and leaf extract but there was high significant reduction in the dose when compared with the control ($p < 0.05$) as shown in Table 2. Testosterone levels were greatly affected in rats treated with 70mg/kg of the gel which gave a mean value of 0.14.

Luteinizing Hormone (LH)

Approximately 93% increase in the levels of LH in the male albino rats treated with the gel and aqueous leaf extract of *A. barbadensis* when compared with the control was observed as shown in Table 3. There was no significant increase between the control and other treatments for both the gel and leaf extract of *A. barbadensis* ($p > 0.05$) as shown in Table 3.

Follicle-stimulating hormone (FSH)

There were about 26% increased levels of FSH in all the treated male albino rats especially the ones treated with 70mg/kg but were reduced in rats treated with 10mg/kg leaf extract as shown in Table 4. There was no significant increase between the control and other treatments for both the gel and leaf extract of *A. barbadensis* ($p > 0.05$) as shown in Table 4.

Histopathological studies

Histopathological alterations were observed in the testes of rats treated with the gel and aqueous leaf extract of *A. barbadensis* at the doses of 10, 30, and 70mg/kg body weight as compared with the control rats. The sections of the testes showed that the effect was neither dose-dependent nor plant-part-specific.

Plate 1 are photomicrographs of seminiferous tubules of testes of control rats (A) showing normal cytoarchitecture, and that of experimental rats (B-D which were treated with 10, 30, and 70mg/kg of the gel of *A. barbadensis* respectively). Seminiferous tubules treated with 10mg/kg showed slight disarrangement of the spermatogonia cells and epithelial membrane, and some of the tubules were observed to have lumen with scanty spermatozoa shown in B. Seminiferous tubules of rats treated with 30mg/kg body weight of gel showed loss of spermatogonia cells, primary and secondary spermatocytes, and the lumen were observed to have clumps of dead spermatozoa as shown in C. Apoptosis of the spermatogonia cells and basal membrane of the seminiferous tubules in addition to distorted Sertoli cells were observed in the seminiferous tubules of rats treated with 70mg/kg body weight of the gel. The sites of Leydig cells were observed to be empty as shown in D.

Plate 2 are sections of testes showing seminiferous tubules of control (A) and experimental rats (B-D treated with 10, 30, and 70mg/kg of aqueous leaf extract of *A. barbadensis* respectively). The spermatogenic arrest with disarrangement of the spermatogonia cells is shown in the seminiferous tubules of rats treated with 10mg/kg of aqueous leaf extract (B).

Table 1: Phytochemical constituents of the gel and aqueous leaf extract of *Aloe barbadensis*

| Bioactive components | Gel extract | | Aqueous leaf extract | |
|----------------------|-------------|----|----------------------|-----|
| Tannins | + | | + | |
| Saponins | | + | | +++ |
| Flavonoids | | + | | ++ |
| Alkaloids | | ++ | | ++ |
| Quinones | | + | | + |
| Glycosides | | + | | ++ |
| Cardiac Glycosides | | + | | + |
| Terpenoids | | + | | + |
| Phenols | + | | + | |
| Steroids | + | | + | |
| Phytosteroids | | + | | + |
| Amino acids | | + | | + |

+ present, ++ present in good quantity, +++ present in abundance

Table 2: Test for significant difference in Testosterone concentration at different doses of *A. barbadensis* gel and leaf extract

| Groups (Gel) | Testosterone (ng/ml) | Groups (Leaf) | Testosterone (ng/ml) |
|-----------------------------------|----------------------|------------------------------------|----------------------|
| <i>A. barbadensis</i> gel 10mg/kg | 0.27 ^b | <i>A. barbadensis</i> leaf 10mg/kg | 0.23 ^b |
| <i>A. barbadensis</i> gel 30mg/kg | 0.39 ^b | <i>A. barbadensis</i> leaf 30mg/kg | 0.24 ^b |
| <i>A. barbadensis</i> gel 70mg/kg | 0.14 ^b | <i>A. barbadensis</i> leaf 70mg/kg | 0.29 ^b |
| Control | 1.83 ^a | Control | 1.83 ^a |
| X ² | 27.846 | X ² | 29.560 |
| DF | 3 | DF | 3 |
| p – value | 0.000 | p – value | 0.000 |
| Significance | p<0.001 | Significance | p<0.001 |

Note: Similar letters (superscripts) indicate values that are not significantly different from each other (p<0.001)

Table 3: Test for significant difference in Luteinizing Hormone (LH) concentration at different doses of *A. barbadensis* gel and leaf extract

| Groups (Gel) | LH (mIU/ml) | Groups (Leaf) | LH (mIU/ml) |
|-----------------------------------|-------------|------------------------------------|-------------|
| <i>A. barbadensis</i> gel 10mg/kg | 8.87 | <i>A. barbadensis</i> 10mg/kg | 7.81 |
| <i>A. barbadensis</i> gel 30mg/kg | 8.32 | <i>A. barbadensis</i> 30mg/kg | 6.79 |
| <i>A. barbadensis</i> gel 70mg/kg | 9.09 | <i>A. barbadensis</i> leaf 70mg/kg | 10.44 |
| Control | 4.34 | Control | 4.34 |
| X ² | 2.267 | X ² | 2.586 |
| DF | 3 | DF | 3 |
| p – value | 0.519 | p – value | 0.460 |
| Significance | p>0.05 | Significance | p>0.05 |

There is no significant difference between control and other treatments for both the gel and leaf extract

Table 4: Test for significant difference in follicle-stimulating hormone (FSH) (mIU/ml) concentration at different doses of *A. barbadensis* gel and leaf extract

| Groups (Gel) | FSH (mIU/ml) | Groups (Leaf) | FSH (mIU/ml) |
|-----------------------------------|--------------|------------------------------------|--------------|
| <i>A. barbadensis</i> gel 10mg/kg | 4.32 | <i>A. barbadensis</i> leaf 10mg/kg | 3.07 |
| <i>A. barbadensis</i> gel 30mg/kg | 4.71 | <i>A. barbadensis</i> leaf 30mg/kg | 4.24 |
| <i>A. barbadensis</i> gel 70mg/kg | 3.93 | <i>A. barbadensis</i> leaf 70mg/kg | 4.87 |
| Control | 3.32 | Control | 3.32 |
| X ² | 0.500 | X ² | 0.733 |
| DF | 3 | DF | 3 |
| p – value | 0.919 | p – value | 0.865 |
| Significance | p>0.05 | Significance | p>0.05 |

There is no significant difference between control and other treatments for both the gel and leaf extract

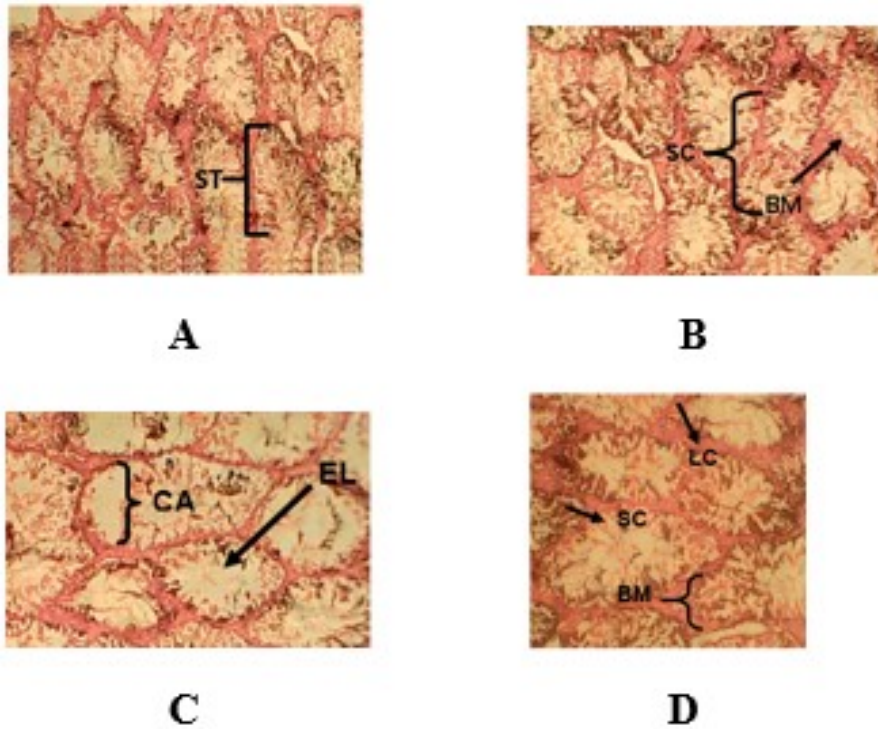


Plate 1: Seminiferous tubules of testes of control and experimental rats treated with 0, 10, 30, and 70mg/kg of *A. barbadensis* gel (A-D respectively) (H&E stain X400).

A - normal seminiferous tubules (ST); **B** - seminiferous tubules with disarrangement of the spermatogonia cells (SC) and basement membrane (BM); **C** - seminiferous tubules showing disrupted cytoarchitecture, (CA) and empty lumen (EL) and **D** - seminiferous tubules showing absence of Leydig cells (LC), distorted Sertoli cells (SC) and apoptosis of basal membrane (BM)

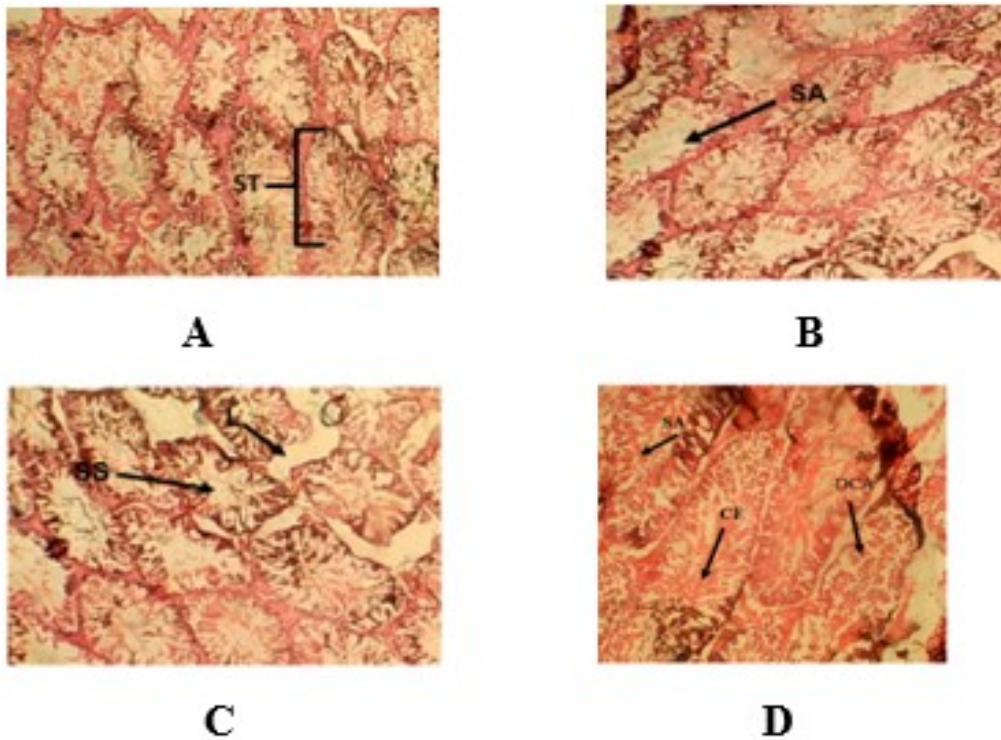


Plate 2: Seminiferous tubules of testes of control and experimental rats treated with 0, 10 30 and 70mg/kg of aqueous leaf extract (A-D respectively) (H&E stain X400).

A- normal seminiferous tubules (ST); **B** - seminiferous tubules with spermatogenic arrest (SA); **C** – lumen of seminiferous tubules showing scanty spermatozoa (SS) and empty site for Leydig cells (L); **D** - seminiferous tubules showing degenerated cytoarchitecture (DCA) of spermatogonia cells, Spermatogenic arrest of spermatid stage (SA) and clumps of flagella of spermatozoa (CF)

Albino rats treated with 30mg/kg of aqueous leaf extract had seminiferous tubules with disrupted spermatogonia cells as well as eroded Leydig cells with scanty spermatozoa in the lumen (C). Experimental rats treated with 70mg/kg of aqueous leaf extract of the plant showed seminiferous tubules with degenerated cytoarchitecture of the spermatogenic cells, arrest of spermatid stage, and clumps of flagella of spermatozoa were observed in the lumen as shown in D.

Discussion

The results of phytochemical screening showed that both the gel and aqueous leaf extract of *A. barbadensis* contained similar phytochemicals. Some of the constituents which include alkaloids, tannins, flavonoids, carbohydrates, and terpenoids were also reported in the findings of Ejoba (2012). Kumar *et al* (2010) also reported that *A. barbadensis* contained quinones, saponins, amino acids, and plant sterols in addition to salicylic acid, lignin, enzymes, and vitamins. The occurrence of these biologically active chemicals in *A. barbadensis* may justify its use in folk medicine.

Testosterone levels were significantly reduced. This could have been due to the degeneration of the Leydig cells which are receptors/binding sites for luteinizing hormone that stimulates the synthesis of testosterone. Testosterone reduction is indicative of the presence of a bioactive compound in the plant which caused the degeneration of Leydig cells. Lowered testosterone levels inhibit spermatogenesis and secretion from accessory sex glands, prostate, and seminal vesicles. The result is not in accord with that of Modaresi and Khodadadi (2014) who studied the effects of *Aloe vera* on reproductive parameters in mice, and Shahraki *et al* (2014), who examined the effects of hydroalcoholic extract of *Aloe vera* gel on spermatogenesis of adult male rats. Shariati *et al* (2009) studied the effect of the alcoholic extract of the *Aloe vera* leaves and had results similar to the present study.

Luteinizing Hormone (LH) is produced in the anterior pituitary which serves to regulate the function of the gonads, while Follicle Stimulating Hormone (FSH) acts on the Sertoli cells for the production of androgen binding protein (ABP) and fluids into the lumen of seminiferous tubules essential for normal maturation of sperm cells within the testes. LH stimulates the production and secretion of testosterone from the testes via stimulating Leydig cells. The increase in LH and FSH concentrations was not significant ($p>0.05$) in this study which is in accord with the findings of Shahraki *et al* (2014). Probably, bioactive compounds in the gel and aqueous leaf extract of *A. barbadensis* were the stimulating constituents in the plant that did not impair the response of the anterior pituitary to secrete increased levels of LH and FSH in response to reduced levels of testosterone.

The increase in LH is indicative of normal anterior pituitary response to androgen deprivation caused by lowered levels of testosterone (Emanuele and Emanuele 2001). An increase in FSH was indicative of germinal epithelial cell damage and it is associated with

azoospermia and severe oligozoospermia. Increased levels of FSH should have prevented the apoptosis of type A spermatogonia but degeneration of the testicular cells was observed. A bioactive compound in the plant may have interfered with the mechanism for the production of the testicular cells of the seminiferous tubules. Increased levels of LH and FSH are pointers to infertility (Babu *et al* 2004).

The histology of the testis of rats treated with gel and aqueous leaf extract of *A. barbadensis* showed disorganization, degeneration, and disruption of spermatogenic cells; distorted Sertoli cells; absence of Leydig cells; lumen of seminiferous tubules with scanty and some devoid of spermatozoa while others were seen with clumps of sperm cells. One important factor that may have disrupted spermatogenic cells is an apoptosis factor in the gel and aqueous leaf extract of *A. barbadensis*. An increase in apoptosis of reproductive cells destroys the balance between replication and death of these cells and causes impaired spermatogenesis. The gel and aqueous leaf extract may have also affected spermatogenesis directly by affecting germinal and Leydig cells and impairing their physiological activity and cell division. Androgen deprivation induces apoptosis and arrest of spermatogenesis (Gillsharma *et al* 2001). Androgen deprivation due to lowered levels of testosterone may have induced the observed apoptosis in the present study. The findings of this study are not consistent with that of Modaresi and Khodadadi (2014) who observed the effect of *Aloe vera* extract on spermatogenesis and reproductive hormones in mice and discovered a significant increase in stem cells and primary spermatocytes that resulted in undisrupted spermatogenesis directly via affecting germinal cells and stimulating cell division.

It has been reported that initiation of spermatogenesis in the germinal epithelium is vulnerable to heat, x-ray, dietary deficiencies, pesticides, and other poisoning. This suggests that the bioactive compounds inherent in the plant may have caused the distortions. Phytochemical analysis indicated the presence of phenols, glycosides, and alkaloids that may have been instrumental to the testicular cell damage which is consistent with the findings of Lu *et al* (1990).

Conclusion

In this study, phytochemical tests revealed that the plant contained tannins, saponins, flavonoids, alkaloids, quinines, glycosides, terpenoids, steroids, and amino acids. Some of these phytochemical constituents of the gel and aqueous leaf extract of *A. barbadensis* may have altered the cytoarchitecture of the seminiferous tubules. This resulted in the disruption of spermatogenesis and spermiogenesis as a result of observed altered levels of the reproductive hormones in the male rats administered orally with the gel and aqueous leaf extract of *A. barbadensis*. Hence the gel and aqueous leaf extract of *A. barbadensis* has the potential of a possible male fertility-regulating agent. The aqueous leaf extract was observed to be more potent in the effects observed than the gel.

Acknowledgments

The authors thank TETFUND for funding this research.

References

- Ahmadi, R., Tavakoli, P. and Mafi, M. 2012. The effect of immobilization stress and *Aloe vera* extract on serum levels of LH, FSH and testosterone in male rats. *Daneshvar Medicine* 19(1): 69-74.
- Babu, S.R., Sadhnani, M.D., Swarna, M., Padmavathi, P. and Reddy, P.P. 2004. Evaluation of FSH, LH and testosterone levels in different subgroups of infertile males. *Ind. J. Clin. Biochem IJCB* 19(1): 45-49. <https://doi.org/10.1007/BF02872388>
- Carson, F.L. 2007. Histotechnology. (2nd ed.) ASCP Press, Chicago.
- Cross, D.E., Acamovic, T., Deans, S.G. and Cdevitt, R.M. 2002. The effects of dietary inclusion of herbs and their volatile oils on the performance of growing chickens. *Brit. Poult. Sci.* 43:533-535.
- Daniyal, M. and Akram, M. 2015. Antifertility activity of medicinal plants. *J. Chin. Med. Assoc.* 78(7), 382-388. <https://doi.org/10.1016/j.jcma.2015.03.008>.
- Dixit, V.P. and Joshi, S. 1983. Effect of *Aloe barbadensis* and *Clofibrate* on serum lipids in triton-induced hyperlipidaemic presbytitis monkeys. *Ind. J. Med. Res.* 78:417-421.
- Ebana, R.U.B., Etok, C.A. and Edet, U.O. 2015. Phytochemical screening and antimicrobial activity of *Nypafruticans* harvested from Oporo River in the Niger Delta Region of Nigeria. *Int. J. Innov. Appl. Sci.* 10(4):1120-1124.
- Ejoba, R. 2012. Phytochemical constituents of some leaves extracts of *Aloe vera* and *Azadirachta indica* plant species. *Global Adv. Res. J. Environ. Sci. Toxicol.* 1(2):014-017.
- Emanuele, M.A. and Emanuele, N. 2001. Alcohol and the male reproductive system. *Alcohol Res. Health.* 25(4): 282-287.
- Erhabor, J.O. and Idu, M. 2017. Aphrodisiac potentials of the ethanol extract of *Aloe barbadensis* Mill. root in male wistar rats. *BMC Complement. Altern. Med.* 17(1): 360. <https://doi.org/10.1186/s12906-017-1866-1>.
- Gill-Sharma, M.K., D'Souza, S., Padwal, V. Balasinor, N., Aleem, M. and Parte, P. 2001. Antifertility effects of estradiol in adult male rats. *J. Endocrinol. Investig.* 24(8): 598-607. <https://doi.org/doi:10.1007/BF03343900>.
- Iwu, M.M. 2014. Handbook of African medicinal plants. CRC Press, London.
- Joshi, S.C., Sharma, A. and Chaturvedi, M. 2011. Antifertility potential of some medicinal plants in males: An overview. *Int. J. Phar. Pharm. Sci.* 3(5): 204-217.
- Kumar, P., Verma, S., Singh, S., Tiwari, S. and Khan, M.Y. 2010. Effect of *Aloe vera* (*Aloe barbadensis*) gel extract on repolarization state of myocardium in albino rat. *Afr. J. Pharm. Pharmacol.* 4(12):885-889.
- Lang, W. 1993. Pharmacokinetic-metabolic studies with ¹⁴C-aloe emodin after oral administration to male and female rats. *Pharmacol.* 47(1): 110-110.
- Lee, H.Z. 2009. Protein kinase C involvement in aloe-emodin- and emodin-induced apoptosis in lung carcinoma cells. *Brit. J. Pharmacol.* 134: 1093-1103. <https://doi.org/doi:10.1038/sj.bjp.0704342>.
- Lu, Q.X. 1990. Effect of glycosides of *Tripterygium wilfordii* Hook on the reproductive system and major organs of male rats. *Zhongguoyixuekexue Yuan xue bao. Acta Acad. Med. Sin.* 12(3): 203-207.
- Modaresi, M., and Khodadadi, A. 2014. The effects of aloe vera extract on spermatogenesis and reproductive hormones in mice. *Res. J. Biol. Sci.* 9(5): 165-168.
- Mohammad, J.G., Valid, K., Ramin, A., Mohsen, N. and Mohammad, A. 2004. Effect of *Achillea santolina* on mice spermatogenesis. *Daru J. Pharm. Sci.* 12(1): 36-39
- Oyewopo, A.O., Oremosu, A.A., Akang, E.N., Noronha, C.C. and Okanlawon, A.O. 2011. Effects of *Aloe Vera* (*Aloe barbadensis*) aqueous leaf extract on testicular weight, sperm count and motility of adult male Sprague-Dawley rats. *J. Amer. Sci.* 7(4): 31-34.
- Saritha, V., and Anilakumar, K.R. 2010. Toxicological evaluation of methanol extract of *Aloe vera* in rats. *Int. J. Pharm. Biol. Res.* 1(5): 142-149.
- Shahraki, A., Mojahed, A.S. and Afshar-Goli, J. 2014. The effects of hydroalcoholic extract of *Aloe vera* gel on spermatogenesis of adult male rats. *Int. J. Biosci.* 5(7): 158-165. <http://dx.doi.org/10.12692/ijb/5.7.158-165>.
- Shariati, M., Mokhtari, M. and Rastegar, S. 2009. Effect of *Aloe* extract on testosterone and gonadotropin hormone on rat. *J. Sabzevar Univ. Med. Sci.* 1(16): 12-17.
- Sofowara, A. 1993. Screening plants for bioactive agents in medicinal plants and traditional medicine in Africa (2nd ed.), Spectrum Books Ltd, Ibadan. 246pp.
- Statista Research Department 2022. Prevalence rate of any contraceptive method among women in Nigeria as of 2022, by civil status. Accessed 25 October, 2023.
- World Health Organization 2018. Family planning: a global handbook for providers. Baltimore and Geneva: CCP and WHO. Retrieved from <https://reliefweb.int/report/world/familyplanning-global-handbook-providers> updated-4th-edition-2022. Accessed 18 September, 2023