

## Original Research Article

# Assessment of Antidermatophytic Activities of *Urtica dioica* L against *Microsporum canis* in a Guinea Pig Model

Ali Mikaeili<sup>1</sup>, Isaac Karimi<sup>2\*</sup>, Masoud Modaresi<sup>3</sup> and Zahra Bagherinasab<sup>3</sup>

<sup>1</sup>Department of Medical Mycology, School of Medicine, Kermanshah University of Medical Sciences, Kermanshah,, <sup>2</sup>Division of Biochemistry, Physiology and Pharmacology, Department of Basic Veterinary Sciences, School of Veterinary Medicine, Razi University, Kermanshah, <sup>3</sup>Department of Pharmacognosy and Pharmaceutical Biotechnology, School of Pharmacy, Kermanshah University of Medical Sciences, Kermanshah, Iran.

\*For correspondence: **Email:** isaac\_karimi2000@yahoo.com; karimiisaac@razi.ac.ir; **Tel:** +98 831 8322599; **Fax:** +98 831 8320041.

Received: 18 October 2013

Revised accepted: 5 October 2013

### Abstract

**Purpose:** To investigate the antidermatophytic effects of *Urtica dioica* L. against *Microsporum canis* in vitro and in a guinea pig model.

**Methods:** The in vitro antifungal activity of the extracts was measured by disc diffusion method and assessment of minimum inhibitory concentration (MIC). The dorsum of the guinea pigs was infected with *M. canis* and topically treated as follows: negative control (NC) received no treatment; positive control (PC) received terbinafine 1 %; DMSO group (negative control) received 10 % DMSO (vehicle); while three other groups, viz, SN10%, SN20% and SN30% received 10, 20 and 30 % hydroalcohol extract dissolved in 10 % DMSO, respectively.

**Results:** Both extracts did not show considerable antifungal activity against *M. canis* compared with terbinafine. The MICs of aqueous and hydroalcoholic extracts were 30 and 20 mg.ml<sup>-1</sup>, respectively. PC and SN30% groups showed normal hair growth on day 15 while their skin looked healthy on day 30 post-inoculation. Lesion severity and clinical scores declined in SN30% and PC groups in comparison to NC group, on day 30 post-inoculation. Also, on day 30 post-inoculation, the clinical efficacy of the test formulations increased to 11.76, 23.52, 76.47, 5.88, and 94.11 % for SN10%, SN20%, SN30%, DMSO10%, and PC groups, respectively.

**Conclusions:** The hydroalcoholic extract of this plant could be further developed, with a view to its possible use as an adjunct remedy for topical treatment of tinea corporis.

**Keywords:** *Urtica dioica* L., *Microsporum canis*, Kurdish Ethnomedicine, Antifungal, Hair growth, Lesion, Dermatophytosis, Tinea corporis

Tropical Journal of Pharmaceutical Research is indexed by Science Citation Index (SciSearch), Scopus, International Pharmaceutical Abstract, Chemical Abstracts, Embase, Index Copernicus, EBSCO, African Index Medicus, JournalSeek, Journal Citation Reports/Science Edition, Directory of Open Access Journals (DOAJ), African Journal Online, Bioline International, Open-J-Gate and Pharmacy Abstracts

## INTRODUCTION

*Urtica dioica* L. (common or stinging nettle) belongs to family *Urticaceae* and is a dioecious herbaceous annual or perennial plant. In this family, more than 600 species in 45 genera are reported [1]. *Urtica* is one of the most important genera and contains 30 species [1]. Laxative,

diuretic and menorrhagic effects have been reported for decoction prepared from the leaves of the nettle [1]. In folk medicine, nettle has been used to treat iron deficiency anemia due to its high content of iron and also used to stop excessive menstrual bleeding, hematuria and nosebleeds. The root of nettle has been employed for treating asthma, rheumatism, sciatica, coughs, diabetes mellitus, diarrhea,

fever, gout, hemorrhoids, snake bites, uterine bleeding after childbirth, low milk production, worm parasitism, lower urinary tract disorders such as nocturia, frequent urination and urinary retention due to benign prostatic hyperplasia [2].

In modern era, antibiotic potential of nettle plant has been reported in several studies [3]. It is also known that nettle extract inhibits *in vitro* replication of viral agents such as HIV and hepatitis [4]. Other studies have shown antifungal activity of nettle plant against plant fungi [5]. The different parts of this centuries-old plant were also used for treatment of dermatological disorders like acne, dandruff, eczema, snake bite, wound, ulcer and various alopecias. Based on traditional applications of nettle in various dermatological problems and its approved antifungal activity in orthodox medicine, we were motivated to investigate its antidermatophytic activities against *Microsporum canis in vitro* and in guinea pig model of *tinea corporis*.

## EXPERIMENTAL

### Plant material

#### Preparation of plant extract

To prepare aqueous extract of stinging nettle (SN; Azarpajohan Sabz Co. www.Iranseed.com, Tabriz, Iran), the air-dried powder was added to distilled water (1/10 w/v, 95 °C) for 1 h. The resulting mixture was then filtered through filter paper and filtrate was dried with the aid of a rotary evaporator at 40 °C and stored at 4 °C. The hydroalcohol extract of SN was prepared by maceration method. The air-dried powder was dissolved or mixed in methanol 70 % (1/10 w/v) in a conical flask, plugged with cotton wool and then kept on a magnet stirrer for at least 12 h. The resulting mixture was then filtered, dried and stored as described above for the aqueous extract.

### Phytochemical screening

The phytochemical screening of the hydroalcohol extract filtrate was performed using standard procedures described elsewhere [6].

### *In vitro* antifungal assay

The isolates of *M. canis* were purchased from Iranian Research Organization for Science and Technology, Tehran, Iran and grown on Sabouraud dextrose agar (SDA; Merck, Germany) plates which contained chloramphenicol and cyclohexamide and DTM at  $37 \pm 2$  °C for 2 weeks. The conidia of fungi were

collected using sterile normal saline solution (NS) on the agar surface followed by gentle shaking. The suspensions were vortexed and heavy particles were allowed to settle for 3-5 min. The inocula were prepared spectrophotometrically to give a final concentration of  $1.0 \times 10^6$  CFU ml<sup>-1</sup> in NS as described in our previous study [7]. Briefly, the resulting inocula were swabbed in the amount of 1 ml.cm<sup>-2</sup> over the surface of SDA plates. Then three sterile paper discs (Whatman No. 4 paper, 5 mm diameter) uniformly loaded with 20 µl of given concentrations of the SN extracts, corresponding solvents of SN extract (distilled water and DMSO 10 % as negative controls for aqueous and hydroalcoholic extracts, respectively while terbinafine (8 µg ml<sup>-1</sup>) as positive control) were placed with sterile tweezers in three equidistances onto the prepared plates. The tests were carried out in triplicate. The diameters of the inhibition zones around the disks were measured daily for 4 weeks on the underside of the Petri dish using vernier calipers [7].

To determine minimal inhibitory concentration (MIC) of SN extracts, five doses of each extract (10, 15, 20, 25, 30 mg ml<sup>-1</sup>) were added to SDA (100 ml) at 45 °C, these being mixed rapidly and poured into four 9.5 cm<sup>2</sup> Petri dish. After the agar had cooled down to room temperature,  $1.0 \times 10^6$  CFU ml<sup>-1</sup> in NS were inoculated per each cm<sup>2</sup> of petridishes. The MIC was taken as the lowest concentration of plant extract to inhibit growth of the fungus after 2 weeks. Each experiment was repeated two times. Then, each extract that showed highest antifungal activity was used in a guinea pig model of *M. canis* induced dermatophytosis.

### *In vivo* anti-dermatophytic assay

The suspensions used for the inoculation were prepared from *M. canis* colonies initially cultivated on SDA slants at 30 °C for 1 week. The colonies were gently scraped from the surface of the culture medium in NS, centrifuged and washed twice in NS. Fungal cells were counted using a haemocytometer and their concentrations adjusted to  $1.0 \times 10^7$  conidia ml<sup>-1</sup>. Aliquots of 0.1 ml were removed from the *M. canis* suspensions were used to inoculate the guinea pigs. Thirty male albino guinea pigs, weighing approximately 600g were anaesthetised by intramuscular administration of ketamine and xylazine cocktail and the hair in the posterior dorsal region of the animals was removed and a skin area in this region of approximately 2.5 cm × 2.5 cm (6.25 cm<sup>2</sup>) area was submitted to gentle scarification with a sterile scalpel blade. A suspension (0.1 ml) containing  $1.0 \times 10^7$  cells *M.*

*canis* was inoculated at the site using a sterile pipette-tip and rubbed thoroughly. The formulations were applied topically to the infected area beginning 72 h post infection once a day and the treatments were continued for 1 week as shown in Table 1. The Medical Ethical Committee of the Medical University of Kermanshah, Iran reviewed and approved this study.

**Table 1:** The characteristics of *Urtica dioica* L. treated guinea pigs inoculated against *Microsporum canis*

| Group (n=5) | Treatment                                                         |
|-------------|-------------------------------------------------------------------|
| NC          | Negative control animals received no treatment                    |
| SN10        | Animals received 0.1ml of 10 percent hydroalcohol extract of SN   |
| SN20        | Animals received 0.1ml of 20 percent hydroalcohol extract of SN   |
| SN30        | Animals received 0.1ml of 30 percent hydroalcohol extract of SN   |
| DMSO        | Animal received 0.1 ml of DMSO10% as vehicle                      |
| PC          | Positive control animals received 0.1 ml of terbinafine 1 percent |

The lesions were clinically followed-up daily and compared with NC animals on days 15 and 30 postinoculation according to the methodology previously described [8]. To evaluate the clinical efficacy of different treatments, the infected area was divided into four equal quadrants. Each quadrant 1.25 cm × 1.25 cm (2.5 cm<sup>2</sup>) was scored as follows: 0 – no signs of infection, hair is fully re-grown; 1 – few slightly erythematous areas on the skin, no scaling; 2 – marked redness, swelling with bristling hairs, bald patches, little scaling; 3 – large areas of well-developed redness, incrustation, little scaling, hair started to re-grow, bald patches, ulcerated in places; 4 – extensive damage to the skin, redness, crusting, ulceration, loss of hair. These scores were summed for the four sites on each animal (maximum possible score per animal was 16) and were used to calculate the efficacy of different treatments according to the equation: Efficacy (%) = 100 - (T·100/C) hence, T = total score of treatment group and C = total score of untreated control. The total score for any group denotes the average clinical score from the different animals in the same group. The severity of dermatophytosis also was numerically scored according to our previous study [7] as follows: 0, none or cure of the lesion; 1, insignificant; 2, slight; 3, moderate and 4, severe.

### Statistical analysis

All statistical analyses were performed using SPSS, version 16.0, statistical software (SPSS

Inc., Chicago, IL, USA). Student's t-test was performed to determine any significant difference between different extracts and concentrations of each extract for *in vitro* antifungal assays. Comparison of means for *in vivo* antidermatophytic assessment was carried out using one-way analysis of variance (ANOVA) and Tukey HSD test.  $P < 0.05$  was considered statistically significant. The results are expressed as mean ± standard deviation (SD).

## RESULTS

### Phytochemical profile of hydroalcoholic extract

Phytochemical analysis of SN hydroalcoholic extract revealed the presence (semiquantitative amount) of the following secondary metabolites: flavonoids (trace), alkaloids (trace), condensed tannins (high), coumarins (high), saponins (high), tri-terpenes (moderate), steroids (moderate), and cardiac glycosides (moderate). Hydrolysable tannins, anthocyanines, cyanogenic glycosides and both free and glycosylated anthraquinones were not detected in this study.

### *In vitro* antifungal activity

The aqueous and hydroalcohol extracts of SN showed lower antifungal activity against *M. canis* than terbinafine ( $p < 0.05$ , Table 2). At a concentration of 100 mg.ml<sup>-1</sup>, both aqueous and hydroalcoholic extracts of SN did not possess any antifungal activities. The aqueous and hydroalcohol extracts showed MIC of 30 and 20 mg.ml<sup>-1</sup>, respectively, against *M. canis*.

**Table 2:** *In vitro* antifungal activity of *Urtica dioica* L. extract against *Microsporum canis* determined by diameter of inhibition zone

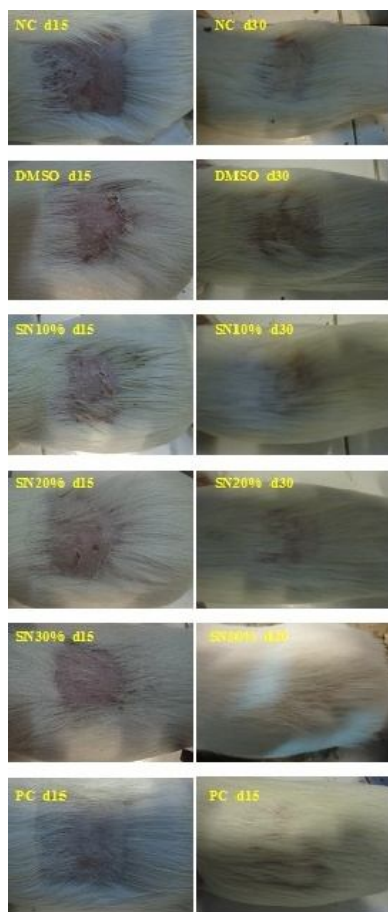
| Extract      | Extract dose (mg.ml <sup>-1</sup> ) |                        |                        | Terbinafine (8 µg.ml <sup>-1</sup> ) |
|--------------|-------------------------------------|------------------------|------------------------|--------------------------------------|
|              | 100                                 | 200                    | 300                    |                                      |
| Aqueous      | NI                                  | 1.0(0.00) <sup>a</sup> | 2.0(1.00) <sup>a</sup> | 14.7(1.30) <sup>b</sup>              |
| Hydroalcohol | NI                                  | 2.5(0.70) <sup>a</sup> | 3.7(1.52) <sup>a</sup> | 14.8(0.92) <sup>b</sup>              |

**Note:** Values are mean ± SD (mm, n = 3); NI = no inhibition zone; in rows, values with different lowercase letters are significantly different.

### *In vivo* antifungal assay

The photographs of guinea pig skin taken on the days 15 and 30 post-inoculation to present clinical signs of different groups of experiment (Fig 1). During the present experiment all animals showed clinical signs of infection day 3 post-inoculation manifested themselves in erythema, swelling, scaling and bristle hair. NC group showed patches of hair loss and readily visible ulcerated or scaly skin on day 30 while

SN20% and SN30% groups were approximately free of infected materials on day 30 (Fig. 1). In contrast, PC and SN30% groups showed normal hair growth, with no signs of infection on day 15 post-inoculation (Fig. 1). Animals in SN10% group showed small patches of hair loss and scaly skin on days 15 and 30 post-inoculation (Fig. 1). No signs of improvement of lesions were recorded during treatment (day 3 to day 10 post-infection or at the end of treatment (day 11 post-inoculation)), however skin of PC and SN30% groups looked clearer, moisturised, soft and elastic on day 30 post-inoculation.



**Figure 1:** Efficacy of hydroalcohol extract of *Urtica dioica* L. compared with untreated (NC), vehicle (DMSO10%) and terbinafine-treated (PC) controls in the treatment of dermatophytoses caused by extract on *Microsporum canis* in guinea pigs on the days 15 and 30 post-inoculation. SN10%, SN20%, SN30% groups received 0.1 ml of 10, 20 and 30 percent hydroalcoholic extract of *Urtica dioica* 72 h post-inoculation for one week.

Both lesion severity and clinical scores were similar among studied groups on day 15 post-inoculation ( $p > 0.05$ ; Table 3). However, the lesion severity scores in parallel to clinical scores significantly declined in SN30% and PC groups in comparison to NC group on day 30 post-inoculation ( $p < 0.05$ ; Table 3). On the day 15 postinoculation, the clinical efficacy of used

formulations resulted in 0, 5, 5, 0, and 10 % for SN10%, SN20%, SN30%, DMSO, and PC groups, respectively. However, on the day 30 postinoculation, the clinical efficacy of used formulations increased to 11.76, 23.52, 76.47, 5.88, and 94.11 % for SN10%, SN20%, SN30%, DMSO, and PC groups, respectively. The self-limiting level of dermatophytosis in NC group was 15 % compared to the clinical score of NC group on day 30 versus day 15 post-inoculation. The net clinical efficacy of used formulation was calculated by subtracting the respective clinical efficacy scores from the self-limiting level of dermatophytosis in NC group. In this regard, only SN30% and PC groups showed clinical effectiveness against dermatophytosis.

## DISCUSSION

*M. canis* is a zoophilic dermatophyte that harbors in the skin or appendages of domestic and feral carnivores and causes various forms of dermatophytosis in humans who live in the vicinity of these animals. Approximately, all dermatophytoses are self-limiting, however treatment speeds up the resolution of the diseases and minimizes the risk of spread of infected spores to the surroundings. Nowadays, synthetic antifungal agents show serious shortcomings in their spectrum of activity, pharmacokinetics, and unique predisposition for pharmacokinetic drug-drug interactions and unusual toxicities associated with long-term use beside their high price. Therefore researchers seek more effective and safe antifungal therapy that shortens the time of treatment and the exposure of the owners to the zoonotic disease. In this regard, searching antifungal phytomedicines in plants is an important step in the quest for safer drugs or formulations. Our laboratory is involved in studying antifungal herbal remedies that abound in the huge heritage of Kurdish ethnomedicine [7]. The present study was designed to find evidences about the traditional usage of SN in dermatological problems in Kurdish ethnomedicine.

Guinea pigs have been used as models to determine the mechanisms by which various zoophilic dermatophytes influence skin physiology and evaluate the efficacy of antifungal therapeutic agents [7,8]. In the present study, *M. canis* exhibited clinical signs of *tinea corporis* in untreated control guinea pigs on 3 or 4 days post-inoculation that manifested themselves in erythema, swelling, and scaling, that reached maximum infective appearance between 7th and 8th day post-inoculation.

**Table 3:** Effect of hydroalcohol extract of *Urtica dioica* on lesions of guinea pig model of dermatophytosis caused by *Microsporum canis*

| Lesion assessment                                    | Group                  |                        |                        |                        |                        |                        |
|------------------------------------------------------|------------------------|------------------------|------------------------|------------------------|------------------------|------------------------|
|                                                      | NC                     | SN10%                  | SN20%                  | SN30%                  | DMSO                   | PC                     |
| Clinical score (day 15)<br>P <sub>ANOVA</sub> =0.365 | 4.0(0.00)              | 4.0(0.00)              | 3.8(0.44)              | 3.8(0.44)              | 4.0(0.00)              | 3.6(0.54)              |
| Clinical score (day 30)<br>P <sub>ANOVA</sub> =0.00  | 3.4(0.54) <sup>a</sup> | 3.0(0.70) <sup>a</sup> | 2.6(0.54) <sup>a</sup> | 0.8(0.44) <sup>b</sup> | 3.4(0.44) <sup>a</sup> | 0.4(0.04) <sup>b</sup> |
| Severity score (day 15)<br>P <sub>ANOVA</sub> =0.365 | 4.0(0.00)              | 4.0(0.00)              | 3.8(0.44)              | 3.8(0.44)              | 4.0(0.00)              | 3.6(0.54)              |
| Severity score (day 30)<br>P <sub>ANOVA</sub> =0.00  | 3.6(0.54) <sup>a</sup> | 3.0(1.00) <sup>a</sup> | 2.2(0.44) <sup>a</sup> | 0.6(0.08) <sup>b</sup> | 3.2(0.89) <sup>a</sup> | 0.2(0.05) <sup>b</sup> |

**Note:** NC = animals received vehicle; PC = animals received reference drug (terbinafine, 1 %); SN10%, SN20% and SN30% received 10, 20 and 30 % aqueous extract of *Urtica dioica* L; evaluation of clinical efficacy was performed 15 or 30 days postinoculation; values represent mean  $\pm$  SD; in rows, values with different lowercase letters are significantly different

Ivaškienė et al [8] have shown that the first signs of experimental infection of *M. canis* in guinea pigs were observed on the  $10.2 \pm 2.7$  days after the inoculation. They also reported that untreated lesions were free of infected material on  $19.5 \pm 5.5$  days after the well defined signs of infection have developed. The lesions of normal control animals were self-limited between 25th and 30th day post-inoculation in the present study; however, complete healing process was not observed. The manifestation of clinical signs of infection, time courses of their appearance and self-limiting nature of induced infection confirmed that our translated model is reliable and explanatory for assaying efficacies of used formulations in guinea pigs. All treated animals showed an acceptable clinical score with healing of cutaneous lesions and partial or excellent regrowth of hair. The group treated with terbinafine showed an excellent healing of cutaneous lesion with no significant differences as compared with group treated with 30% SN.

Nettle has been used in hair shampoos to control dandruff and eczema and is reported to bring back the natural color of hair. It also helps to stimulate hair growth [9].

Since our *in vitro* results showed that both hydroalcoholic and aqueous extracts of SN have no direct antifungal activities, improvement of experimentally-induced dermatophytic lesions in SN-treated groups may have been mediated by mechanisms other than its antifungal activities. In contrast to our *in vitro* results, antimycotic activity of the ethanol extracts from nettle against some plant pathogenic fungi has been reported using agar dilution bioassay [5]. In another study, extracts of *Urtica dioica* leaves obtained following supercritical CO<sub>2</sub> extraction showed antibacterial activity [10]. The discrepancy between our results and the above-mentioned studies may be related to the methods of extract preparation, types of extracts, different parts of plant, types of tested organisms and

concentrations of used extracts. The development of cell-mediated immunity and inflammatory response is associated with clinical cure of dermatophytosis, otherwise the host will predispose to chronic or recurrent dermatophyte infection [11]. In the present study, topically administered NS did not prevent occurrence of symptoms, but improved skin lesion after development of symptoms which may be due to enhancing the inflammatory responses required for the cure of dermatophytosis. The immunomodulatory activity of different parts and isolated compounds of SN has been reported previously [12].

We did not find significant antifungal activity with SN in this study and, therefore could not relate improvement of dermatophytic symptoms to the components of SN extracts' antifungal activity. However, the antifungal activities of flavonoids [13], tannins [14], alkaloids [15], tri-terpenoids [16], steroids [17], anthocyanins [18], coumarins [19], and saponins [20] which are also found in SN have been reported. SN showed a conspicuous absence of cyanogenic glycosides, free or glycosylated anthraquinones and anthocyanines.

## CONCLUSION

Our findings indicate that the aqueous and hydroalcohol extracts of SN have weak *in vitro* antifungal activity; while the hydroalcohol extract improved symptoms and aesthetic problems of dermatophytosis in guinea pig model. The mechanisms of the healing action of the hydroalcohol extract remains unknown and hence further investigations will be required for the elucidation of the molecular basis of this action.

## ACKNOWLEDGEMENT

This manuscript is derived from a thesis entitled "Assessment of antifungal activities of aerial

parts of *Urtica dioica* L. against *Microsporum canis* in vitro and in guinea pig model of dermatophytosis", submitted to Kermanshah University of Medical Sciences, Kermanshah, Iran.

## REFERENCES

- Ghahreman A. *Flora of Iran / Flore de l' Iran en couleurs naturelles*. vol. 7 . Publie' par: institute des recherches des Forests et des paturage. Departement Botanique. Tehran; 1986 ; p 868.
- Barnes J, Anderson LA, Phillipson D. *Herbal medicine*. 2st ed, Pharmaceutical Press, London; 2002; p 360.
- Chrubasik JE, Boufogalis BO, Wagner H, Chrubasik S. A comprehensive review on the Stinging nettle, effect and efficacy profiles. *Phytomedicine* 2007; 14(7): 568-579.
- Uncini Manganelli RE, Zaccaro L, Tomei PE. Antiviral activity in vitro of *Urtica dioica* L., *Parietaria diffusa* M.et. *Kand Sambucus nigra*L. *J Ethnopharmacol* 2005; 98(3):323-327.
- Hadizadeh I, Peivastegan B, Kolahi M. Antifungal activity of nettle (*Urtica dioica* L.), colocynth (*Citrullus colocynthis* L. Schrad), oleander (*Nerium oleander* L.) and konar (*Ziziphus spina-christi* L.) extracts on plants pathogenic fungi. *Pak J Biol Sci* 2009;12(1):58-63.
- Harbone JB. *Phytochemical methods: A guide to modern techniques of plant analysis*. 2nd Edition. Chapman and Hall; 1984; 4-18, 288 p.
- Mikaeili A, Karimi I, Shamspur T, Gholamine B, Modaresi M, Khanlari A. Anti-candidal activity of *Astragalus verus* in the in vitro and in vivo guinea pig models of cutaneous and systemic candidiasis. *Rev. Bras. Farmacogn* 2012; 22(5).
- Ivaškiėnė M, Matusevičius A, Grigonis A, Zamokas G, Šiugzdaitė J. Establishing the efficacy of novel topical formulations in the treatment of experimental dermatophytosis in guinea pigs. *Veterinarija Ir Zootechnika* 2011; T. 54(76).
- Bisht S, Bhandari S, Bisht NS. *Urtica dioica* (L): an undervalued, economically important plant. *Agr Sci Res J* 2012; 2(5): 250-252.
- Rafajlovska VG, Doneva-Spaceska DK, Slaveska-Raick RB, Djarmati Z, Cvetkov LD. Antimicrobial activity of stinging nettle (*Urtica dioica* L.) obtained by supercritical CO<sub>2</sub>. *Herba Polonica* 2000; 46(3): 125-132.
- Jones HE. Immune response and host resistance of humans to dermatophyte infection. *J Am Acad Dermatol* 1993;28: S12-S18.
- Le Moal, MA, Truffa-Bach P. *Urtica dioica* agglutinin, a new mitogen for murine T lymphocytes: unaltered interleukin-1 production but late interleukin 2-mediated proliferation. *Cell Immunol* 1998; 115: 24-35.
- Tim Cushnie TP, Andrew JL. Antimicrobial activity of flavonoids. *Int J Antimicrob Ag* 2005; 26(5): 343–356.
- Burapedjo S, Bunchoo A. Antimicrobial activity of tannins from *Terminalia citrina*. *Plant Medica* 1995; 61:365-366.
- Morteza-Semnani K, Amin G, Shidfar MR, Hadizadeh H, Shafiee A. Antifungal activity of the methanolic extract and alkaloids of *Glaucium oxylobum*. *Fitoterapia* 2003 ;74(5):493-496.
- Becker H, Scher JM, Speakman JB, Zapp J. Bioactivity guided isolation of antimicrobial compounds from *Lythrum salicaria*. *Fitoterapia* 2005; 76: 580-584.
- Subhisha S, Subramoniam A. Antifungal activities of a steroid from *Pallavicinia lyellii*, a liverwort. *Indian J Pharmacol* 2005; 37(5): 304-308.
- Schaefer HM, Rentzsch M, Breuer M. Anthocyanins reduce fungal growth in fruits. *Nat Prod Commun* 2008; 3(8): 1267-1272.
- Navarro-García VM, Rojas G, Avilés M, Fuentes M, Zepeda G. In vitro antifungal activity of coumarin extracted from *Loeselia mexicana* Brand. *Mycoses* 2011;54(5):e569-71.
- Rahman MA, Haque A, Hasanuzzaman M , Shahid IZ. Antinociceptive, antiinflammatory and antibacterial properties of *Tamarix indica* roots. *Int J Pharmacol* 2011; 7(4): 527-531.