

## Original Research Article

# Comparison of two types of thrombolysis combined with percutaneous transluminal angioplasty for acute thrombosis in arteriovenous fistula and graft

Yuanyuan Wang\*, Jihong Deng, Shizhen Liu, Jinping Tan, Zhimin Chen

Department of Nephrology, Jiangmen Central Hospital, Jiangmen, Pengjiang District, Jiangmen, Guangdong 529030, China

\*For correspondence: **Email:** [racheal818@163.com](mailto:racheal818@163.com)

Sent for review: 24 October 2023

Revised accepted: 13 August 2024

### Abstract

**Purpose:** To investigate and compare the efficacy of two different types of thrombolysis combined with percutaneous transluminal angioplasty (PTA) for acute thrombosis in arteriovenous fistula (AVF) and graft (AVG).

**Methods:** A total of 128 patients on hemodialysis with acute AVF/AVG occlusion, from May 2021 to May 2023 at Jiangmen Central Hospital, Guangdong, were randomly assigned to study group (catheter-directed thrombolysis) (CDT) comprising of 62 patients and control group (scalp needle thrombolysis) comprising of 66 patients. Patients whose thrombolysis was unsuccessful on the first day, received PTA therapy the next day. Thrombolytic success rates, urokinase dosage, PTA therapy rates, mural thrombus occurrence, and post-thrombolytic complications were evaluated and compared.

**Result:** There was no significant difference in overall thrombolytic success rate, PTA combination rate and incidence of hemorrhage ( $p > 0.05$ ) between study and control groups. Recanalization rate after urokinase thrombolytic therapy on first day was significantly higher in the study group than in the control group ( $p < 0.05$ ). Urokinase dosage (first day) of patients whose thrombolytic therapy was successful was significantly lower in the study group than in the control group ( $p < 0.001$ ).

**Conclusion:** Mechanical fragmentation by angiography catheter combined with urokinase thrombolysis improves efficacy, but shows no advantage when combined with PTA. Additional studies using a larger patient population on anticoagulant therapy and longer investigation time are recommended to enhance the generalizability of this treatment approach.

**Keywords:** Arteriovenous fistula/arteriovenous graft, Thrombosis, Catheter-directed thrombolysis, Transluminal angioplasty, Stenosis

This is an Open Access article that uses a funding model which does not charge readers or their institutions for access and distributed under the terms of the Creative Commons Attribution License (<http://creativecommons.org/licenses/by/4.0>) and the Budapest Open Access Initiative (<http://www.budapestopenaccessinitiative.org/read>), which permit unrestricted use, distribution, and reproduction in any medium, provided the original work is properly credited.

Tropical Journal of Pharmaceutical Research is indexed by Science Citation Index (SciSearch), Scopus, Web of Science, Chemical Abstracts, Embase, Index Copernicus, EBSCO, African Index Medicus, JournalSeek, Journal Citation Reports/Science Edition, Directory of Open Access Journals (DOAJ), African Journal Online, Bioline International, Open-J-Gate and Pharmacy Abstracts

## INTRODUCTION

Arteriovenous fistula (AVF) and arteriovenous graft (AVG) are the main vascular access types in patients undergoing hemodialysis [1-3]. The main causes of fistula dysfunction are internal fistula stenosis, hemangioma and thrombosis caused by intimal hyperplasia and internal fistula

puncture [4]. Hypoproteinaemia [5], chronic inflammation [6], anticoagulant drugs [7], and platelet aggregation inhibitors [8] are also influencing factors of internal fistula dysfunction. At present, there are many methods to reverse and prevent internal fistula dysfunction [9]. Thrombolysis is considered the preferred choice for internal fistula thrombosis compared to

surgical thrombectomy [10]. Catheter-directed thrombolysis (CDT) combined with percutaneous transluminal angioplasty (PTA) is always recommended because it provides a high patency rate in the treatment of acute thrombosis of internal fistula [11]. Catheters for internal fistula thrombolysis have not been popularized in many basic hospitals. Since the traditional treatment of fistula thrombosis in Jiangmen Central hospital is by scalp needle, an angiography catheter was used to replace the internal fistula thrombolysis catheter, and efficacy of angiography catheter thrombolysis and scalp needle thrombolysis combined with PTA in patients with internal fistula occlusion was assessed.

## METHODS

### Subjects

A randomized non-blind prospective study was conducted at the blood purification center of Jiangmen Central Hospital between May 2021 and May 2023. Patients undergoing maintenance hemodialysis with confirmed internal fistula blockage with or without stenosis were randomized into study (CDT) ( $n = 62$ ) and control (scalp needle thrombolysis) groups ( $n = 66$ ). This study was approved by the ethics committee of Jiangmen Central Hospital (approval no. 202364) and complied with the guidelines of Declaration of Helsinki [12].

### Inclusion criteria

Patients undergoing maintenance hemodialysis who were over 18 years of age, AVF or AVG was used for vascular access, internal fistula was used for more than 1 month, ultrasound examination confirmed internal fistula occlusion and thrombosis with or without internal fistula stenosis, time of thrombosis < 72 h, and signed informed consent for thrombolytic therapy.

### Exclusion criteria

Patients with severe coagulopathy and active bleeding, cerebrovascular accident, severe trauma or major surgery in the last 2 months, severe mental disorder, AVG/AVF infection or serious infection at other sites, and other options, such as reconstructing pathways, if it was a better choice for the patients.

### Data collection

Data such as sex, age, smoking, age of dialysis, with or without diabetes, utility time of fistula, time of thrombosis, first fistula or not,

thrombolysis history, type of fistula, combined with PTA or not, dialysis frequency, drug combination (anticoagulant, antiplatelet aggregation drugs, lipid-lowering drugs), thrombus length, with stenosis or not, diameter of stenosis and blood test results (most recently within 3 months) such as hemoglobin, C reactive protein, serum albumin, total cholesterol, triglyceride and low density lipoprotein cholesterol were collected.

### Treatment

The patients were hypodermically injected with 50 IU/kg low molecular weight heparin (Hebei Changshan Biochemical Pharmaceutical Co., LTD., Shijiazhuang, China) after being diagnosed by color ultrasound and tested for activated coagulation time. The thrombolytic therapy comprised of 250,000 U urokinase (Ma'Anshan Fengyuan Pharmaceutical Co. Ltd, Ma'Anshan, China) in 50 mL normal saline.

### Study group

A 6F catheter sheath (Shanghai Condela Medical Device Co. Ltd, Shanghai, China) was placed more than 3 cm away from the proximal end of the AVG or AVF embolization guided by a guide wire (HG353AF, Shanghai Conderai Medical Device Co. Ltd, Shanghai, China), and the tip of the angiographic catheter (HNB5.0-38-40-P-NS-KMP, Cook) was sent to the thrombus site. After the guide wire was partly removed, the KMP tube body was rotated to repeatedly strike the thrombus (Figure 1 A). An infusion pump was used to deliver the thrombolytic drug through the tail end of the KMP tube (pump speed 500,000 U/h), and the catheter was removed step by step according to the thrombolysis effect under color ultrasound monitoring (Figure 1 B). If necessary, an appropriate site was selected to place another sheath in the opposite direction and the thrombolytic drug was injected by same KMP tube following same procedures.

### Control group

The scalp needle was punctured 1.5 – 2 cm (24 G) near the AVG or AVF embolism site, and the thrombolytic drug was injected (the configuration method and pump speed were same as the study group). Total amount of urokinase used on the first day was not more than 1 million U (Figure 1 A and B). Patients whose thrombolysis therapy failed on the first day had PTA therapy performed the following day by balloon catheter (5 – 7 × 40 mm, Boston Scientific Corporation) (Figure 1 C). If fistula flow was recovered,

colored ultrasound scan of the whole fistula vessel was done (Figure 1 D).

### Evaluation of parameters/indices

#### Efficacy

Efficacy indices evaluated include; the main indices (final treatment patency rate, recanalization rate after urokinase thrombolytic therapy on the first day), secondary indices (recanalization rate of those without fistula stenosis after urokinase thrombolytic therapy on first day, PTA combination rate, total urokinase dosage on first day, and the combined rate of mural thrombosis of patients with ultimately successful treatment in two days). Standard for successful urokinase thrombolysis include palpable tremor on the fistula, and continuous blood flow through the fistula scanned by color ultrasound. Successful PTA surgery was defined as a residual stenosis of < 30 %. Criteria for treatment of final fistula patency includes palpable tremor on the fistula, ultrasound examination shows continuous blood flow, and blood flow volume during hemodialysis not lower than 200 mL/min the next day without any other treatments.

#### Safety

Incidence of serious (bleeding resulting in an obvious decrease ( $\geq 20$  g/L) in hemoglobin and requiring infusion of suspended red blood cells, pulmonary embolism, and death complications) as well as mild complications (bleeding at puncture site, hematoma, bleeding from mucosa or gums, and related infection) were compared between study and control groups.

### Statistical analysis

Data analysis was performed using Statistic Package for Social Science (SPSS) 25.0 (IBM, Armonk, NY, USA). Normally distributed measurement data are presented in mean  $\pm$  Standard deviation (SD), and t-test was used for comparison. Non-normally distributed measurement data were presented in inter-quartile range (IQR) (P25, P75), and nonparametric test with rank transformation was used for comparison. Categorical variables were presented in frequency and percentages and compared using Chi-square test. Binary logistic regression was used to analyze the factors affecting the success of urokinase thrombolysis before PTA, and  $p < 0.05$  was considered statistically significant.

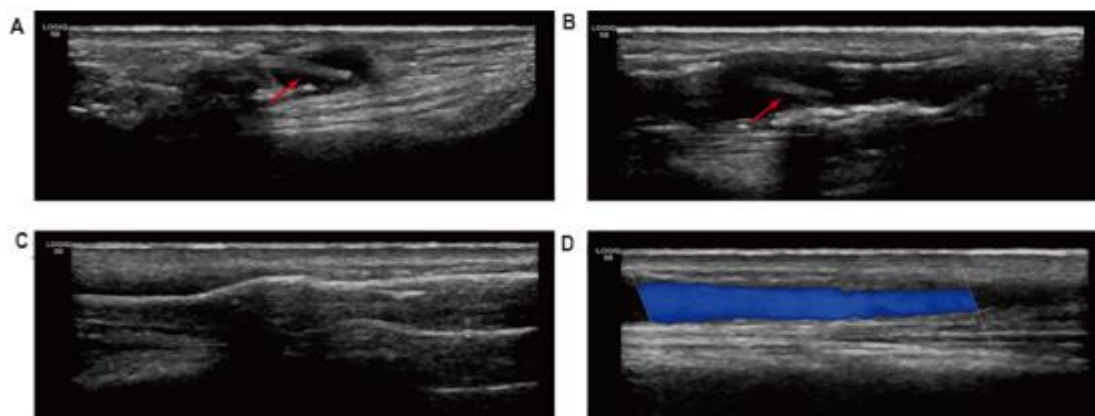
## RESULTS

### Baseline data

A total of 128 patients were included in the study, comprising 62 men and 66 women, with a mean age of  $51.47 \pm 9.99$  years. There was no significant difference in baseline data except C-reactive protein between the study and control groups (Table 1).

### Efficacy

There was no significant difference in final treatment patency rate or PTA treatment combination rate between study and control groups. The study group showed significantly higher recanalization rates of urokinase thrombolysis on the first day compared to control group ( $p < 0.05$ ).



**Figure 1:** Ultrasound images of KMP-directed thrombolysis combined with PTA. (A) Thrombus fragmentation by the tip of the KMP catheter. (B) After the process of urokinase thrombolysis by the KMP catheter (the red arrows show the tip of the KMP catheter in A and B). (C) Stenosis of the cephalic vein was dilated by a balloon catheter. (D) Blood flow of the AVF was restored after treatment

**Table 1:** Baseline data

Variable	Study (n = 62)	Control (n = 66)	P-value
Male n (%)	26(41.94)	36(54.55)	0.31
Age (y)	52.26±11.14	50.73±8.98	0.55
Smoking n (%)	6(9.68)	14(21.21)	0.36
Dialysis age (m)	43(22.72)	54(39.84)	0.18
Diabetes mellitus n (%)	22(35.48)	24(36.36)	0.94
Time of use of this internal fistula (m)	30(18.44)	33(22.5,54.5)	0.55
Time of thrombosis (h)	21(18.29)	22(17,31)	0.86
The first fistula n (%)	26(41.94)	29(43.94)	0.82
History of thrombolysis n (%)	34(54.84)	42(63.64)	0.47
AVF n (%)	24(38.71)	32(48.48)	0.43
Statins n (%)	40(64.52)	36(54.55)	0.42
Antiplatelet aggregation drug n (%)	26(41.94)	24(36.36)	0.65
Anticoagulant drug n (%)	8(12.90)	6(9.09)	0.93
Hemoglobin (g/L)	95.23±15.27	95.03±14.48	0.96
Serum albumin (g/L)	34.78±3.48	35.58±4.16	0.24
C-reactive protein (mg/L)	23.34(8.99,45.03)	41.0(16.72,61.99)	0.03
Total cholesterol (mmol/L)	3.89(3.54,4.27)	4.03(3.61,4.83)	0.34
Triglyceride (mmol L)	2.41±0.69	2.53±0.87	0.56
LDL cholesterol (mmol L)	2.44(2.10,3.50)	2.43(1.95,3.50)	0.80
The thrombus length was < 5 cm	14(22.58)	16(24.24)	0.72
The 5-cm thrombus length was < 10 cm	34(54.84)	38(57.58)	
The thrombus length was 10 cm	14(22.58)	12(18.18)	
With stenosis n (%)	46(74.19)	44 (66.67)	0.35
The narrowest diameter of stenosis (mm)	1.95±0.37	1.93±0.33	0.89

**Note:** Some values are mean ± SD, h: hour; y: year; m: month; n: number

**Table 2:** Efficacy and complications (N, %)

Variable	Study (n = 62)	Control (n = 66)	P-value
The final treatment patency rate	60(96.77)	52(78.79)	0.07
The recanalization rates of urokinase thrombolysis on the first day	42(67.74)	24(36.36)	0.01
The recanalization rates of urokinase thrombolysis on the first day for patients without stenosis	12(75.00)	9(40.91)	0.04
The PTA treatment combination rate	50 (80.65)	57 (86.36)	0.38
The dosage of urokinase used in the first-day for patients with successful thrombolysis (10000 IU)	50(47.50,56.25)	75(60.00,77.50)	<0.001
The combined rate of mural thrombosis for patients with ultimately successful treatment	8(13.33)	18(34.62)	0.05
Mild bleeding during thrombolysis	4(6.45)	12(18.18)	0.30

Dosage of urokinase used on the first day for patients with successful thrombolysis, and combine rate of mural thrombosis was significantly lower in study group compared to control group ( $p < 0.05$ ). There was no significant difference in the incidence of complications between study and control group ( $p > 0.05$ ) (Table 2).

### Logistic regression analysis

Using the first-day urokinase thrombolysis outcome as the dependent variable (thrombolysis success = 1), univariate logistic regression analysis was used to screen out 4 indices with  $p < 0.05$  as the boundary, including study group treatment, internal fistula type, thrombus length, and C-reactive protein. A multivariate logistic

regression equation was constructed using 4 indices as independent variables. Results showed that the different effects of the study group treatment (OR = 4.03, 95 % CI,  $p = 0.01$ , 13.73) and length of thrombus > 10 cm (OR = 0.07, 95 % CI 0.01-0.50,  $p = 0.01$ ) on the urokinase thrombolysis outcome of the first day in patients with acute arteriovenous fistula occlusion were significant (Table 3).

### DISCUSSION

Urokinase is a commonly used thrombolytic agent [13]. Studies have shown better effect with topical administration of urokinase compared to peripheral intravenous thrombolysis in patients with endovenous thrombosis [14].

**Table 3:** Logistic regression model of the effect of one-day urokinase thrombolytic therapy on 128 cases with acute arteriovenous fistula occlusion

Influencing factor	Univariate analysis		Multiplicity	
	OR (95%CI)	P-value	OR (95%CI)	P-value
KMP catheter thrombolysis (%)	3.68(1.31-10.34)	0.01	4.03 (1.18~13.71)	0.03
Male (%)	1.00(0.38-2.68)	0.99		
Age (y)	1.01(0.96-1.06)	0.61		
Smoking (%)	0.34(0.08-1.47)	0.15		
Dialysis age (m)	0.999(0.99-1.01)	0.86		
Dialysis 3 times/week vs 2 times/week (%)	2.4(0.54-10.59)	0.25		
Utility time of internal fistula (m)	1(0.98-1.02)	0.99		
Time of thrombosis (h)	0.97(0.92-1.01)	0.12		
The first fistula (h)	0.79(0.29-2.13)	0.64		
History of thrombolysis (%)	1.11(0.41-3.02)	0.84		
Diabetes mellitus (%)	0.79(0.29-2.20)	0.65		
AVF (vs AVG) (%)	0.41(0.15-1.13)	0.09	0.53 (0.16-1.75)	0.30
5 cm < thrombus length ≤ 10 cm (vs 5 cm) (%)	0.41(0.11-1.52)	0.18		
Thrombus length > 10 cm (vs 5 cm) (without stenosis) (%)	0.11(0.02-0.61)	0.01	0.07 (0.01-0.50)	0.01
With stenosis (%)	0.83(0.30-2.35)	0.73		
Diameter of the narrowest point of the stenosis (mm)	2.49(0.57-10.86)	0.23		
Statins (%)	1.44(0.53-3.92)	0.48		
Antiplatelet aggregation drug (%)	2.3(0.82-6.47)	0.11		
Hemoglobin (g/L)	1(0.97-1.03)	0.99		
Serum albumin (g/L)	0.99(0.87-1.13)	0.91		
C-reactive protein (mg/L)	0.98(0.959-1.00)	0.03	0.98 (0.96-1.01)	0.16
Total cholesterol (mmol/L)	0.94(0.58-1.52)	0.81		
Triglyceride (mmol/L)	1.37(0.72-2.60)	0.34		
LDL cholesterol (mmol/L)	1.04(0.64-1.69)	0.87		

Clinical scalp needles, internal fistula needles, indwelling needles and other internal fistula thrombi are often used for local urokinase infusion. Some researchers infused urokinase through a lumbar anesthesia puncture needle for local thrombolysis of internal fistula. The technical success rate reached 82.4 % for patients without fistula stenosis. For patients with fistula stenosis, technical success rate was as high as 97.5 % when combined with PTA [15]. Some investigators even directly used a balloon catheter for AVF/AVG local thrombolysis followed by balloon expansion [16].

Catheter-directed thrombolysis (CDT) has been used to treat deep vein thrombosis (DVT) for more than 30 years and is a widely recommended method for thrombus clearance [17]. It reduces symptoms of early DVT, severity of post-thrombotic syndrome, and improves the quality of life of patients with DVT [17,18]. In the past, CDT was used in patients with DVT, pulmonary embolism and lower extremity artery occlusion [19]. At present, CDT has also been used in internal fistula thrombolysis [20]. At present, there is no internal fistula thrombolysis catheter in the hemodialysis center of the hospital. For patients with internal fistula blockage, the traditional treatment process of

urokinase thrombolysis in the center is performed through scalp needles, but the potency of thrombolysis on the first day is low.

To improve the treatment process, a KMP tube was used to replace the scalp needle for thrombolysis in this study. For safety reasons, no side holes were punched on the KMP catheter. The elbow design of the KMP tube was used to tactfully increase operation of the mechanical thrombus fragmentation, and the tube may be directly extended to the thrombus site to achieve contact thrombolysis, which is more advantageous for thrombi far from the puncture site. Compared with thrombolysis through balloon catheters directly [19], thrombolysis by KMP tubes alleviate the urgency of surgical procedure execution, and allow the initial screening of patients who do not need balloon dilation. In addition, thrombolysis by a KMP catheter is conducted directly via vein access.

This study investigated the efficacy of thrombolysis by a KMP catheter (study group) and thrombolysis by a traditional scalp needle (control group) both combined with PTA. The results showed that although there was no significant difference in final treatment patency outcome (the relevance of the heterogeneity of

PTA treatment was not excluded), KMP catheter was more advantageous in terms of the recanalization rates of urokinase thrombolysis on the first day and the dosage of urokinase compared with scalp vein. Furthermore, efficacy of thrombolytic therapy was significantly improved in the study group. There is a close relationship between length of thrombosis and the effect of urokinase thrombolysis therapy. In this study, logistic regression analysis also showed that thrombolysis by a KMP catheter and length of thrombosis > 10 cm were independent influencing factors of the efficacy of thrombolysis on the first day in patients with acute arteriovenous fistula occlusion. Studies have shown that the time of thrombosis is an influencing factor of the effect of AVF urokinase thrombolysis and was positively correlated with the thrombus length [21]. However, in this study; neither longer thrombosis time nor longer fistula stenosis showed a higher risk of thrombolysis failure.

### Limitations of this study

The sample size of this study was relatively small, and the results may not be generalized. Some patients could not define the time of internal fistula blockage accurately, and the record protocol for this situation was to add 24 h to the provided blockage time of internal fistula if the dialysis schedule of the patient was 2 times per week and adding 12 h if the schedule was 3 times per week. As a result, the actual effect of the variable on the outcome may be reduced by this protocol. Also, the narrow typing criteria for AVG and AVF are inconsistent, and the influence of variables such as the type of stenosis, number and length of the narrow sections on the thrombolysis effect was not analyzed. There was no significant difference in the PTA combination rate between the two groups, which was considered to be related to the lower proportion of patients without fistula stenosis. In addition, using anticoagulants was not included in the logistic regression analysis due to the small number of patients taking anticoagulants in the two groups.

### CONCLUSION

Urokinase thrombolysis via a KMP catheter combined with PTA improves recanalization rate, lowers urokinase dosage, improves efficacy and minimizes postoperative complications following urokinase thrombolytic therapy. In further studies, there is a need for increased number of patients on anticoagulant therapy and increased investigation time to improve the generalizability of this treatment approach.

### DECLARATIONS

#### Acknowledgement

This work was supported by the Jiangmen City Science and Technology Program Project (no. 2021YL01077).

#### Funding

None provided.

#### Ethical approval

This study was approved by the ethics committee of Jiangmen Central Hospital, China (202364).

#### Availability of data and materials

The datasets used and/or analyzed during the current study are available from the corresponding author on reasonable request.

#### Conflict of Interest

No conflict of interest associated with this work.

#### Contribution of Authors

We declare that this work was done by the authors named in this article and all liabilities pertaining to claims relating to the content of this article will be borne by the authors. Yuanyuan Wang designed the study, and wrote and revised the article. Jihong Deng and Jinping Tan analyzed the data. Shizhen Liu and Zhimin Chen performed the experiments. All the authors read and approved the final manuscript for publication.

#### Open Access

This is an Open Access article that uses a funding model which does not charge readers or their institutions for access and distributed under the terms of the Creative Commons Attribution License (<http://creativecommons.org/licenses/by/4.0>) and the Budapest Open Access Initiative (<http://www.budapestopenaccessinitiative.org/read>), which permit unrestricted use, distribution, and reproduction in any medium, provided the original work is properly credited.

### REFERENCES

1. Ravani P, Palmer SC, Oliver MJ, Quinn RR, MacRae JM, Tai DJ, Pannu NI, Thomas C, Hemmelgarn BR, Craig JC, et al. Associations between hemodialysis access

- type and clinical outcomes: a systematic review. *J Am Soc Nephrol* 2013; 24(3): 465-473.
2. Li L, Bian L, Chen H, Li X, Hu R. Effectiveness of hydropathic compress of dandelion in ameliorating complications of arteriovenous fistula. *Trop J Pharm Res* 2022; 21(5): 1067-1072 doi: 10.4314/tjpr.v21i5.22
  3. Huber TS, Berceli SA, Scali ST, Neal D, Anderson EM, Allon M, Cheung AK, Dember LM, Himmelfarb J, Roy-Chaudhury P, et al. Arteriovenous fistula maturation, functional patency, and intervention rates. *JAMA Surg* 2021; 156(12): 1111-1118.
  4. Viecelli AK, Mori TA, Roy-Chaudhury P, Polkinghorne KR, Hawley CM, Johnson DW, Pascoe EM, Irish AB. The pathogenesis of hemodialysis vascular access failure and systemic therapies for its prevention: Optimism unfulfilled. *Semin Dialysis* 2018; 31(3): 244-257.
  5. Premuzic V, Hudolin T, Pasini J, Zimak Z, Hauptman D, Jelakovic B, Kastelan Z. Hypoproteinemia as a prognostic risk factor for arteriovenous fistula failure. *Hemodial Int* 2018; 22(1): 37-44.
  6. Rai V, Radwan MM, Nooti S, Thankam FG, Singh H, Agrawal DK. TLR-4 inhibition attenuates inflammation, thrombosis, and stenosis in arteriovenous fistula in yucatan miniswine. *Cardiol Cardiovasc Med* 2022; 6(5): 432-450.
  7. Irvinn J, Oldman N, Sedgwick P, Chemla E. Do blood pressure levels and other patient characteristics influence native fistula patency? *Semin Dialysis* 2014; 27(3): E27-E31.
  8. See YP, Cho Y, Pascoe EM, Cass A, Irish A, Voss D, Polkinghorne KR, Hooi LS, Ong LM, Paul-Brent PA, et al. Predictors of arteriovenous fistula failure: A post hoc analysis of the Favoured Study. *Kidney360* 2020; 1(11): 1259-1269.
  9. Thomas M, Nesbitt C, Ghouri M, Hansrani M. Maintenance of hemodialysis vascular access and prevention of access dysfunction: A review. *Ann Vasc Surg* 2017; 43: 318-327.
  10. Koraen-Smith L, Krasun M, Bottai M, Hedin U, Wahlgren CM, Gillgren P. Haemodialysis access thrombosis: Outcomes after surgical thrombectomy versus catheter-directed thrombolytic infusion. *J Vasc Access* 2018; 19(6): 535-541.
  11. Wang T, Wang S, Gu J, Lou W, He X, Chen L, Chen G, Zee C, Chen BT. Transcatheter thrombolysis with percutaneous transluminal angioplasty using a trans-brachial approach to treat thrombosed arteriovenous fistulas. *Med Sci Monitor* 2019; 25: 2727-2734.
  12. World Medical Association. World Medical Association Declaration of Helsinki: ethical principles for medical research involving human subjects. *JAMA* 2013; 310: 2191-2194.
  13. Song Z, Gan Y, Huang X, Huang X, Liu G, Kong B, et al. Combination of lateral ventricular puncture and catheterization with different doses of urokinase in the treatment of ventricular hemorrhage under CT multimodal imaging. *Trop J Pharm Res* 2021; 20(12): 2645-2651 doi: 10.4314/tjpr.v20i12.27
  14. Wan Z, Xiang R, Wang H, Zhong Q, Tu B. Comparative efficacy and safety of local and peripheral venous thrombolytic therapy with urokinase for thrombosed hemodialysis arteriovenous fistulas. *Exp Ther Med* 2019; 17(5): 4279-4284.
  15. Prasad R, Vignesh S, Yadav RR, Sharma S, Hasani P, Yadav T, Israhmed A, Lal H. Direct percutaneous thrombolysis (DPT): A novel method of salvaging thrombosed native arteriovenous fistula. *J Vasc Access* 2023: 939348524.
  16. Zhang S, Zhu C, Ye Y, Li H. Percutaneous transluminal angioplasty combined with thrombolysis for acute thrombosis in arterio-venous fistula and graft. *Zhejiang Da Xue Xue Bao Yi Xue Ban* 2019; 48(5): 533-539.
  17. Goldhaber SZ, Magnuson EA, Chinnakondepalli KM, Cohen DJ, Vedantham S. Catheter-directed thrombolysis for deep vein thrombosis: 2021 update. *Vasc Med* 2021; 26(6): 662-669.
  18. Khalid MU, Singh M, Lakhter V, Bashir R. Catheter directed thrombolysis for deep vein thrombosis in 2022: Rationale, evidence base and future directions. *Int J Cardiol* 2022; 362: 168-173.
  19. Cueto-Robledo G, Roldan-Valadez E, Graniel-Palafox LE, Garcia-Cesar M, Torres-Rojas MB, Enriquez-Garcia R, Cueto-Romero HD, Perez-Calatayud AA. A review of the usefulness of catheter-directed thrombolysis for pulmonary embolism. *Curr Prob Cardiology* 2023; 48(8): 101197.
  20. Yeo CB, Yong E, Hong Q, Kwan J, Quek L, Pua U, Punamiya S, Chandrasekar S, Tan G, Lo ZJ. Outcomes of catheter-directed thrombolysis for arteriovenous fistula thrombosis in Singapore: Is it still relevant today? *Ann Vasc Dis* 2021; 14(1): 5-10.
  21. Di X, Ying Z, Zhen W, Zhi-jun G. Clinical effect and related factors of urokinase thrombolysis combined with balloon dilatation for the treatment of arteriovenous fistula occlusion due to thromboembolism. *Chin J Blood Purification* 22(6): 463-466.