

## Original Research Article

# Effect of pycnogenol on ischemia/reperfusion-induced oxidative and inflammatory damage in the ovaries of rats

Kemal Dinc<sup>1</sup>, Sevil Kiremitli<sup>2</sup>, Bahadir Suleyman<sup>3</sup>, Renad Mammadov<sup>3</sup>, Bulent Yavuzer<sup>3</sup>, Seval Bulut<sup>3</sup>, Gulce N Yazici<sup>4</sup>, Taha A Coban<sup>5</sup>, Durdu Altuner<sup>3</sup>, Halis Suleyman<sup>3\*</sup>

<sup>1</sup>Clinic of Obstetrics and Gynecology, Mersin City Training and Research Hospital, Mersin, <sup>2</sup>Department of Obstetrics and Gynecology, <sup>3</sup>Department of Pharmacology, <sup>4</sup>Department of Histology, <sup>5</sup>Department of Biochemistry, Faculty of Medicine, Erzincan Binali Yildirim University, Erzincan, Turkey

\*For correspondence: **Email:** [halis.suleyman@gmail.com](mailto:halis.suleyman@gmail.com); **Tel:** +90 530 9211909, **Fax:** +90 446 2261819

Sent for review: 25 May 2023

Revised accepted: 3 November 2023

### Abstract

**Purpose:** To investigate the protective effect of pycnogenol (PYC) against ischemia/reperfusion (I/R) ovarian damage induced by experimental ovarian torsion in rats using biochemical and histopathological methods.

**Methods:** Four groups of rats ( $n = 6$ ) were randomly assigned and designated as follows – SG: sham group, PCG: pycnogenol (40 mg/kg) group, IRG: ovarian ischemia-reperfusion group, and PIR: pycnogenol (40 mg/kg) + ovarian ischemia-reperfusion group. In IRG and PYC treatment groups, ischemia was induced in the right ovary for two hours with vascular clips. The ovary was reperused for two hours after ischemia was induced. Then, the levels of malondialdehyde (MDA), total glutathione (tGSH), nuclear factor-kappa B (NF- $\kappa$ B), tumor necrosis factor-alpha (TNF- $\alpha$ ) and interleukin-1 $\beta$  (IL-1 $\beta$ ) in the ovarian tissues of rats were examined. Ovarian tissues were also examined histopathologically and follicle counts were performed.

**Results:** Histopathological examination revealed that the developing follicles in ovary of I/R-induced group showed both morphological and cellular degeneration and vascular pathology. The PYC treatment group showed less ovarian damage, edema and vascular pathology than I/R-induced group ( $p < 0.05$ ). The MDA, NF- $\kappa$ B, TNF- $\alpha$  and IL-1 $\beta$  levels in I/R-induced group were significantly higher than in SG and tGSH levels were significantly reduced by I/R damage ( $p < 0.05$ ). Pycnogenol treatment reversed these biochemical indices as well as I/R-induced histopathological changes.

**Conclusion:** Pycnogenol has a protective effect in rat ovaries by alleviating I/R-induced changes in biochemical parameters and histological disruptions. Further studies, including those in humans, to determine the effect of PYC on ovarian injuries would be required.

**Keywords:** Ischemia-reperfusion, Ovarian damage, Pycnogenol, MDA, NF- $\kappa$ B, TNF- $\alpha$ , IL-1 $\beta$

This is an Open Access article that uses a funding model which does not charge readers or their institutions for access and distributed under the terms of the Creative Commons Attribution License (<http://creativecommons.org/licenses/by/4.0>) and the Budapest Open Access Initiative (<http://www.budapestopenaccessinitiative.org/read>), which permit unrestricted use, distribution, and reproduction in any medium, provided the original work is properly credited.

Tropical Journal of Pharmaceutical Research is indexed by Science Citation Index (SciSearch), Scopus, Web of Science, Chemical Abstracts, Embase, Index Copernicus, EBSCO, African Index Medicus, JournalSeek, Journal Citation Reports/Science Edition, Directory of Open Access Journals (DOAJ), African Journal Online, Bioline International, Open-J-Gate and Pharmacy Abstracts

## INTRODUCTION

Ovarian torsion occurs when the ovary rotates around its ligaments from which it receives

support [1]. It is a gynecological emergency and affect women of all ages [2]. The most important risk factors are: being of reproductive age, presence of a mass in the ovaries exceeding 5

cm, pregnancy, ovulation induction and previous ovarian torsion [3]. However, ovarian torsion is seen even in normal ovaries [4]. Ovarian torsion is one of the causes of ovarian ischemia [2].

Ischemia is a condition in which the amount of oxygen in the tissue is reduced as a result of impaired blood flow in the vessels associated with the tissue, for whatever reason. On the other hand, reperfusion is the restoration of blood supply to the ischemic tissues [5]. Continuous reperfusion, after an ischemic attack, leads to a new physio-pathological process called "reperfusion injury", which results in more severe tissue damage [6]. A delay in diagnosing and treating ovarian torsion result in severe ovarian damage and infertility [7]. Therefore, in the clinical setting, reperfusion of the ovaries by detorsion of the torsioned ovaries and preservation of their functions should be prioritized.

Xanthine oxidase, the levels of which increase in tissue during ischemia, converts hypoxanthine to xanthine, using the abundant oxygen available as the tissue reperfuses [5]. As a result, a large proportion of the oxygen that reaches the tissue during reperfusion is converted into reactive oxygen species (ROS). Products with toxic properties, such as malondialdehyde (MDA), are formed due to the attack of cell membrane lipids by ROS [5]. In a study conducted by Ali and co-workers, it was reported that the ischemia/reperfusion (I/R) procedure also increased the levels of pro-inflammatory cytokines along with oxidants in ovarian tissue [8].

Pycnogenol (PYC), investigated for its protective effect against possible damage caused by the ovarian I/R procedure, is a standardized extract of *Pinus maritime* [9]. In many countries, PYC is used as a dietary supplement and as a phytochemical treatment for various diseases, from chronic inflammation to circulatory disorders. A large number of studies have determined the antioxidant and anti-inflammatory properties of PYC. It has been reported that the strong antioxidant activity of PYC is due to the synergistic interaction of its components [10]. Ozoner *et al* reported that PYC protects brain tissues by reversing the increase in MDA and pro-inflammatory cytokines and the decrease of total glutathione (tGSH) [13].

Turkler *et al* also showed that PYC had mitigating effects against cisplatin-induced uterine and ovarian tissue damage in rats [14]. Based on this information, it was thought that PYC might protect the ovaries from I/R injury.

However, studies investigating the effect of PYC on I/R-induced ovarian injury were not found in the literature. In this study, the preventive effect of PYC treatment on ovarian injury induced by I/R procedure in rats was investigated using biochemical analysis and histopathological examination.

## EXPERIMENTAL

### Animals

Eighteen female albino Wistar rats (245 – 258 g) were used in the study. Animals were provided from the Atatürk University Medical Experimental Application and Research Centre. The rats were housed in laboratory rooms at a temperature of  $22 \pm 2$  °C. The rooms were equipped with 12-hour automatic light–dark cycles. The rats were provided with food and water without restriction before and during the experiment. The study was approved by Erzurum Ataturk University Laboratory Animal Research Local Ethics Committee (Dated: 04.30.2020, Meeting no. 4, Decision no. 60), and followed international guidelines for animal studies.

### Chemicals

Thiopental sodium was purchased from I.E ULAGAY (Istanbul, Turkey) and PYC was purchased from Solgar (Leonia, America).

### Groups

The rats used in this study were divided into three groups of six rats each and designated as follows – SG: sham operation group, PCG: pycnogenol (40 mg/kg) group, IRG: ovarian ischemia-reperfusion group and PIR: pycnogenol (40 mg/kg) + ovarian ischemia-reperfusion group.

### Procedure

Sterile conditions were provided for surgical procedures in the experimental design. One hour before anesthesia, PYC (40 mg/kg) was administered orally in the PCG and PIR groups [13]. SG and IRGs were also given normal saline orally. Thiopental sodium (25 mg/kg) was injected intraperitoneally (IP) one hour after administration of pycnogenol or saline. A vertical incision (2 – 3 cm) was made in the appropriate anatomical region of the rats to access the right ovaries in SG, PIR and IRGs (no application was made to the ovaries of SG animals). Two hours later, the clips were excised and the tissues reperfused for another two hours. The rats were sacrificed using sodium thiopental (50 mg/kg)

and the right ovaries were excised. The ovarian tissues were subjected to biochemical and histopathological examination.

## Biochemical analyses

### Preparation of samples

Excised rat ovaries (0.2 g) were weighed, washed with NaCl (0.9 %) to remove blood and subsequently homogenized in liquid nitrogen. For MDA determination, 2 mL of the homogenate was transferred to a 1.15 % potassium chloride solution. To determine total glutathione (tGSH), phosphate buffer (pH = 7.4, 2 mL) was added to homogenate. The solution was subsequently centrifuged and filtrate was used for analysis.

### Determination of MDA levels

For the determination of MDA, the pink-colored compound formed the reaction of thiobarbituric acid and MDA ( $\mu\text{mol/g}$  protein) at 100 °C was measured spectrophotometrically [13]. Homogenates were centrifuged (5000 rpm, 20 min) and 250  $\mu\text{L}$  of the clear filtrate was added to 750  $\mu\text{L}$  (0.08 %) thiobarbituric acid, 100  $\mu\text{L}$  (8 %) sodium dodecyl sulphate, 750  $\mu\text{L}$  (20 %) acetic acid and 150  $\mu\text{L}$  purified water and allowed to mix. Then, this mixture was incubated at 100 °C for one hour. N-butanol (2.5 mL) was added and the pink color produced was read at a wavelength of 532 nm. The standard calibration curve was prepared using an appropriate concentration range of 1,1,3,3,3-tetra-methoxypropane [13].

### Evaluation of tGSH levels

GSH (nmol/g protein) is a compound containing a sulphhydryl group in its structure. Sulphydryl groups reduce 5,5'-dithiobis (2-nitrobenzoic acid) (DTNB), and a yellow color is formed [14]. Homogenates were centrifuged (12,000 rpm, 10 min) and 500  $\mu\text{L}$  of the supernatant was added into test tubes containing 1500  $\mu\text{L}$  of measuring buffer, 100  $\mu\text{L}$  DTNB and 7,900  $\mu\text{L}$  of methanol and the solution was allowed to mix. This mixture was incubated at 37 °C for 30 minutes. The absorbance of the yellow compound was read at 412 nm and the sample concentrations were calculated using a standard curve prepared according to GSH standard [14].

### Assessment of NF- $\kappa$ B, TNF- $\alpha$ and IL-1 $\beta$ levels

Rat-specific enzyme-linked immunosorbent assay (ELISA) kits were used to determine NF- $\kappa$ B ( $\mu\text{g/g}$  protein), TNF- $\alpha$  (pg/mL) and IL-1 $\beta$  (pg/mL) concentrations in ovarian tissue

homogenates. Kits for rat NF- $\kappa$ B (Catalog no. 201-11-0288) were procured from SunRed (China) while those for TNF- $\alpha$  (Catalog no. YHB1098Ra) and IL-1 $\beta$  (Catalog no. YHB0616Ra) were purchased from Shanghai (China). Analyses were carried out following the manufacturer's manual.

### Histopathological analysis

For light microscopy evaluation, the samples were placed in a 10 % formaldehyde solution to prevent any deterioration in the histological structures of the tissues. The tissues were then washed and gradually treated with (70 – 100 %) alcohol for dehydration. They were made transparent with xylol and blocks were obtained using paraffin wax. Sections (4 – 5  $\mu\text{m}$ ) obtained from these blocks were stained with hematoxylin-eosin. Tissues were examined and photographed (Olympus DP2-SAL, Olympus® Inc. Tokyo, Japan). The histopathologist who performed the evaluation was not aware of the groups. Tissue damage was graded between 0 and 3 (0: absent, 1: mild, 2: moderate, 3: severe). Follicle classification and counting were performed at 100x magnification.

### Statistical analysis

The IBM SPSS 22 software was used for all statistical analyses. The biochemical and follicle count data were presented as mean  $\pm$  standard deviation (SD). The data were subjected to the Shapiro-Wilk test, and the results showed that they were normally distributed. A one-way ANOVA was used for analysis. Post-hoc test selection was made based on Levene's test. The Games-Howell test was used in cases where variance homogeneity was not provided (MDA), and Tukey's HSD test was used when it was provided (tGSH, NF- $\kappa$ B, TNF- $\alpha$ , IL-1 $\beta$  and follicle count). For histopathological statistics, the Kruskal Wallis test - Mann Whitney U test was used.  $P < 0.05$  was considered statistically significant.

## RESULTS

### MDA and tGSH levels

Malondialdehyde (MDA) levels were significantly elevated in ovarian tissues obtained from the IRG ( $5.37 \pm 0.23$ ) compared to the sham operation ( $2.23 \pm 0.05$ ) and PYC alone ( $1.47 \pm 0.23$ ) groups ( $p < 0.001$ ). MDA levels in rats treated with PYC ( $2.92 \pm 0.37$ ) prior to I/R were significantly lower than in the IRG ( $p < 0.001$ , Figure 1). On the other hand, tGSH levels were found to be decreased in the IRG ( $1.71 \pm 0.76$ )

compared to the sham operation ( $4.60 \pm 0.17$ ) and PYC alone ( $5.86 \pm 0.07$ ) groups ( $p < 0.001$ ). This decrease in tGSH levels was reversed by PYC ( $3.73 \pm 0.20$ ) administration prior to I/R ( $p < 0.001$ , Figure 1).

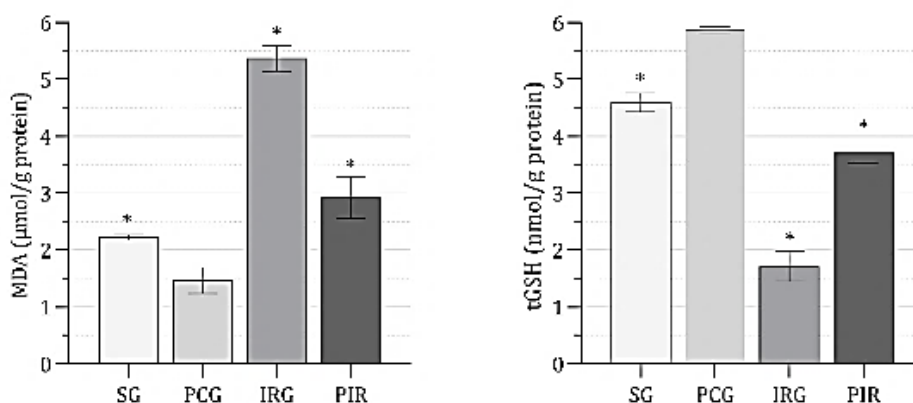
### NF- $\kappa$ B, TNF- $\alpha$ and IL-1 $\beta$ production

As shown in Figure 2, NF- $\kappa$ B production in ovarian tissues subjected to I/R (IRG) was higher ( $5.70 \pm 0.33$ ) than in the sham operation ( $2.39 \pm 0.36$ ) and PYC alone ( $1.65 \pm 0.15$ ) groups ( $p < 0.001$ ). The PYC significantly reversed I/R-induced increase in NF- $\kappa$ B levels ( $p < 0.001$ ). There was no significant difference in the NF- $\kappa$ B levels between PIR group and SG ( $p = 0.220$ ). Furthermore, TNF- $\alpha$  levels were higher in the IRG ( $4.62 \pm 0.19$ ) than in the sham operation ( $1.72 \pm 0.16$ ) and PYC alone ( $1.21 \pm 0.09$ ) groups ( $p < 0.001$ ). PYC significantly reduced the increase in TNF- $\alpha$  amounts in ovaries subjected

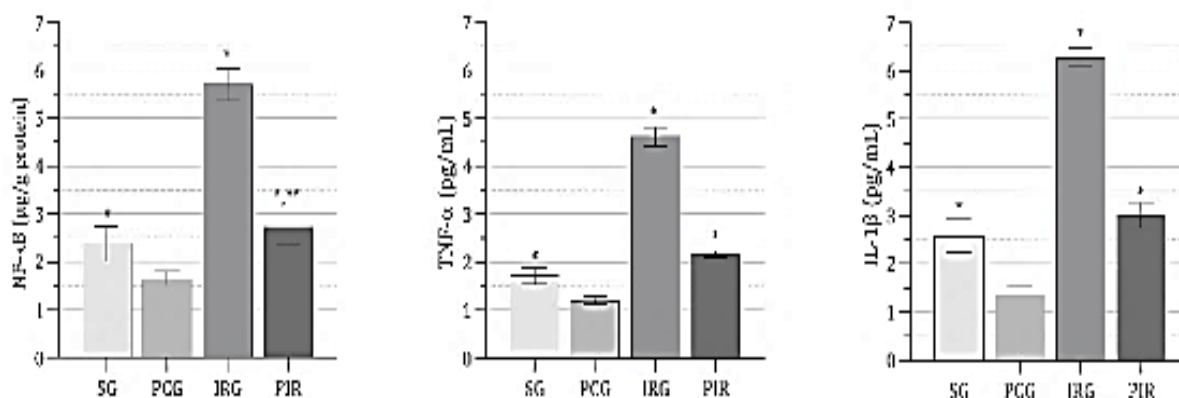
to I/R ( $p < 0.001$ ; Figure 2). In addition, the IRG exhibited a significantly higher IL-1 $\beta$  ( $6.28 \pm 0.20$ ) than those of the sham operation ( $2.58 \pm 0.34$ ) and PYC alone ( $1.35 \pm 0.21$ ) groups ( $p < 0.001$ ). Pretreatment with PYC significantly reversed the increase in IL-1 $\beta$  levels in ovaries subjected to I/R ( $p < 0.001$ , Figure 2).

### Histopathological findings

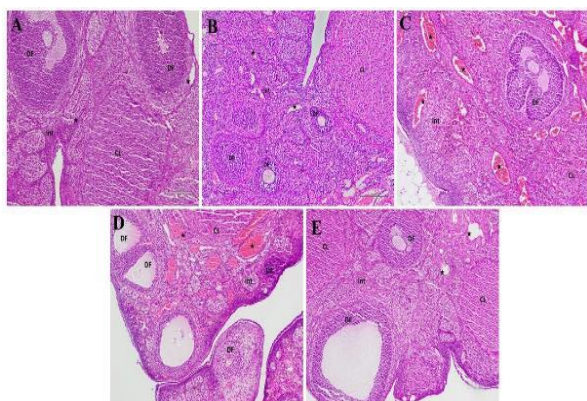
As shown in Figure 3 A and B and Table 1, microscopic analyses of the ovarian sections of the sham operation and PYC groups show normal histological structure with developing follicle structures, corpus luteum, interstitial area and vessels. In the ovarian sections of I/R group (IRG) however, there was pronounced morphological and cellular degeneration of the developing follicles, abnormal bleeding foci in the corpus luteum and edema in the interstitial region were observed.



**Figure 1:** MDA and tGSH levels in ovarian tissues of experimental groups. **Note:** \* $P < 0.001$  vs. IRG. MDA: malondialdehyde; tGSH: total glutathione; SG: sham operation; PCG: pycnogenol (40 mg/kg); IRG: ovarian ischemia-reperfusion; PIR: pycnogenol (40 mg/kg) + ovarian ischemia-reperfusion



**Figure 2:** NF- $\kappa$ B, TNF- $\alpha$  and IL-1 $\beta$  levels in ovarian tissues of experimental groups. **Note:** \* $P < 0.001$  vs. IRG. NF- $\kappa$ B: nuclear factor kappa B; TNF- $\alpha$ : tumor necrosis factor-alpha; IL-1 $\beta$ : interleukin one beta. SG: sham operation; PCG: pycnogenol (40 mg/kg); IRG: ovarian ischemia-reperfusion; PIR: pycnogenol (40 mg/kg) + ovarian ischemia-reperfusion



**Figure 3 (A – E):** Hematoxylin-eosin staining of the ovary section of the experimental groups; **A.** Healthy control group. DF: developing follicle. Int: interstitial area. CL: corpus luteum. ★: blood vessel, x100. **B.** PYC group. DF: developing follicle. Int: interstitial area. CL: corpus luteum. ★: blood vessel, x100. **C.** Ischemia/reperfusion group. DF: degeneration in developing follicles, Int: edematous interstitial area, CL: degenerated corpus luteum, ★: dilated and congested blood vessel, x100. **D.** Ischemia/reperfusion group. DF: degeneration in developing follicles, Int: dense edematous interstitial area, CL: degenerated corpus luteum, ★: dilated and congested blood vessel, x100. **E.** I/R + PYC group. DF: developing follicle with normal morphology, Int: interstitial area with normal appearance, CL: corpus luteum, ★: normal blood vessel, x100

Severe dilatation and congestion were also noted in the blood vessels (Figure 3 C and Table 1). Furthermore, degeneration was also observed in the oocytes of the developing follicles, and areas of intense edema containing vacuolized cells were found in some places in large interstitial

areas (Figure 3 D and Table 1). In contrast, histopathological examination of the treatment group (PIR) detected a normal appearance of the developing follicles and corpus luteum, elimination of edema in the interstitial field and absence of dilatation and congestion of the blood vessels (Figure 3 E and Table 1).

As shown in Table 2, I/R procedure decreased the number of developing and primordial follicles compared to rats in the sham operation and PYC-only groups ( $p < 0.05$ ). The number of developing and primordial follicles counted in PYC + I/R-treated rats was higher than in I/R group ( $p < 0.05$ ). Atretic follicle and corpus luteum counts were the same in all groups ( $p > 0.05$ ).

## DISCUSSION

Ovarian ischemia may occur for various reasons, including surgical interventions, ovarian masses or ovarian torsion. It is an emergency gynecological situation that cause serious complications like infertility [15]. Reperfusion of ischemic ovaries after the detorsion procedure causes reperfusion damage. Therefore, it is increasingly recommended to add a conservative treatment to detorsion therapy [1]. The lipid peroxidation process that occurs in the cell due to oxidative stress leads to the formation of free radicals [9]. Malondialdehyde (MDA), the end product of lipid peroxidation, rises in I/R state, indicating the development of oxidative stress [9].

**Table 1:** Median and range values histopathological score of the groups

Parameter	Group			
	SG	PCG	IRG	PIR
FD	0 (0-0)*	0 (0-0)*	3 (2-3)	0.5 (0-1)*
IE	0 (0-0)*	0 (0-0)*	3 (3-3)	0.0 (0-1)*
CLD	0 (0-0)*	0 (0-0)*	3 (2-3)	0.5 (0-1)*
DCV	0 (0-0)*	0 (0-0)*	3 (3-3)	0.0 (0-0)*

**Note:** \* $P < 0.05$  vs. IRG. FD: degeneration in follicles; IE: edema in the interstitial area; CLD: corpus luteum degeneration; DCV: dilated and congested blood vessel; SG: sham operation; PCG: pycnogenol (40 mg/kg); IRG: ovarian ischemia-reperfusion; PIR: pycnogenol (40 mg/kg) + ovarian ischemia-reperfusion

**Table 2:** Comparison of follicle counts in the groups

Parameter	Group			
	SG	PCG	IRG	PIR
AF	3.33±1.03*	3.34±1.01*	3.00±0.63	3.33±1.03*
CL	13.50±1.05*	13.45±1.12*	14.50±0.83	13.50±1.04*
DF	23.33±1.21**	23.36±1.05	19.66±1.63**	23.16±0.75**
PF	13.83±1.17**	13.80±1.09	11.66±0.81**	13.50±0.83**

**Note:** \* $P > 0.05$  vs. IRG, \*\* $p < 0.05$  vs. IRG. AF: atretic follicle; CL: corpus luteum; DF: developing follicle; PF: primordial follicle; SG: sham operation; PCG: pycnogenol (40 mg/kg); IRG: ovarian ischemia-reperfusion; PIR: pycnogenol (40 mg/kg) + ovarian ischemia-reperfusion

Agents like GSH, which interact with free radicals and are reduced to more stable molecules, also have the ability to repair lipid peroxides [11]. In a study where I/R was performed in rat ovaries, there was an increase in MDA amounts and a depletion in total antioxidant capacity in ovarian tissues [8]. Oxidative damage was detected in I/R group rats' ovaries, with an increase in MDA levels and a decrease in tGSH levels compared to the sham group rats. Furthermore, in the PYC + I/R group, PYC protected the ovaries against I/R injury by limiting MDA increase and tGSH decrease. This result is in agreement with Ozoner *et al* who showed that PYC protects brain tissues against I/R injury by inhibiting the rise of MDA and pro-inflammatory cytokines while increasing tGSH levels as well [11]. Also, Ozer Sehirli *et al* established a model of renal I/R damage and found that MDA levels were significantly reduced in rats receiving a single dose of 10 mg/kg PYC intraperitoneally [9].

NF- $\kappa$ B serves as a transcription factor for the production of several pro-inflammatory cytokines that play important roles in regulating inflammation and immune responses [16]. Previous studies established that ROS increases NF- $\kappa$ B production [17]. In addition, Kocaturk *et al* found an increase in NF- $\kappa$ B levels in kidney tissues following I/R application [16]. In the current study, I/R application led to an elevation of tissue NF- $\kappa$ B concentrations. The fact that NF- $\kappa$ B levels in I/R + PYC group did not increase as in I/R group but were close to those in the sham group suggests that PYC inhibits NF- $\kappa$ B. NF- $\kappa$ B specifically triggers the production of TNF- $\alpha$ , IL-1, IL-6, lymphotoxin, and IFN- $\gamma$  [17]. The results from this study showed that TNF- $\alpha$  and IL-1 $\beta$  levels increased at the tissue level in I/R group. According to the biochemical results, PYC given before I/R significantly suppressed the increase of TNF- $\alpha$  and IL-1 $\beta$ . Ali *et al* also demonstrated that ovarian I/R increased tissue TNF- $\alpha$  expression in their study [9]. Pycnogenol had a similar effect in kidney tissues exposed to I/R and reversed the increase in tissue TNF- $\alpha$  and IL-1 $\beta$  [16]. The data indicate that PYC suppresses inflammation by reducing I/R-induced oxidative stress and pro-inflammatory cytokine increase in the ovary.

In this study, the protective effect of PYC on ovarian reserve was also evaluated by determining the number of follicle loss. Previously, Turkler *et al* showed that PYC ameliorated cisplatin-induced histopathological changes in the uterus and ovaries [14]. Additionally, another study showed that pycnogenol reduced liver damage in an I/R rat model [6]. In this study, it was observed that the

amount of primordial and developing follicles was lower in the PYC-treated group. Congestion, bleeding, edema and follicular degeneration, which are changes that occur due to I/R damage in ovarian tissue, were also observed histopathologically. Conversely, PYC pre-treatment significantly ameliorated I/R-induced ovarian damage.

## CONCLUSION

The results of this study confirm that I/R procedure causes serious damage to ovarian tissues. Pycnogenol protects the ovaries against I/R damage and possesses antioxidant activities, including the stabilization of intracellular antioxidant defense systems as well as reduction of ROS and lipid peroxidation products. This study has shown that PYC is beneficial in the treatment of I/R-induced ovarian injury. Further *in vivo* studies on the effect of PYC on ovarian injuries, including in humans, would be required.

## DECLARATIONS

### Acknowledgements

None provided.

### Funding

None provided.

### Ethical Approval

The study was approved by Erzurum Ataturk University Laboratory Animal Research Local Ethics Committee.

### Availability of data and materials

The datasets used and/or analyzed during the current study are available from the corresponding author on reasonable request.

### Conflict of Interest

No conflict of interest associated with this work.

### Contribution of Authors

We declare that this work was done by the authors named in this article and all liabilities pertaining to claims relating to the content of this article will be borne by the authors. The study was conceived and designed by: Kemal Dinc, Halis Suleyman, Taha A Coban, and Gulce N Yazici. Data collection and analyses by: Bahadir Suleyman, Renad Mammadov, Bulent Yavuzer,

Seval Bulut, and Durdu Altuner. This manuscript was written and edited by Kemal Dinc, Halis Suleyman, Seval Bulut, and Sevil Kiremitli.

### Open Access

This is an Open Access article that uses a funding model which does not charge readers or their institutions for access and distributed under the terms of the Creative Commons Attribution License (<http://creativecommons.org/licenses/by/4.0>) and the Budapest Open Access Initiative (<http://www.budapestopenaccessinitiative.org/read>), which permit unrestricted use, distribution, and reproduction in any medium, provided the original work is properly credited.

### REFERENCES

1. Yapca OE, Borekci B, Turan MI, Gulapoglu M. The effect of agomelatine on oxidative stress induced with ischemia/reperfusion in rat ovaries. *Adv Clin Exp Med* 2014; 23(5): 715-721.
2. Huang C, Hong MK, Ding DC. A review of ovary torsion. *Ci Ji Yi Xue Za Zhi* 2017; 29(3): 143-147.
3. Huchon C, Fauconnier A. Adnexal torsion: a literature review. *Eur J Obstet Gynecol Reprod Biol* 2010; 150(1): 8-12.
4. Naiditch JA, Barsness KA. The positive and negative predictive value of transabdominal color Doppler ultrasound for diagnosing ovarian torsion in pediatric patients. *J Pediatr Surg* 2013; 48(6): 1283-1287.
5. Yapca OE, Borekci B, Suleyman H. Ischemia-reperfusion damage. *Eurasian J Med* 2013; 45(2): 126-127.
6. Tokac M, Bacanli M, Dumlu EG, Aydin S, Engin M, Bozkurt B, Yalcin A, Erel O, Kilic M, Basaran N. The ameliorative effects of pycnogenol® on liver Ischemia-Reperfusion Injury in Rats. *Turk J Pharm Sci* 2017; 14(3): 257-263.
7. Bayer AI, Wiskind AK. Adnexal torsion: can the adnexa be saved? *Am J Obstet Gynecol* 1994; 171(6): 1506-1510.
8. Ali FF, Ahmed AF, Elroby ADM. Underlying mechanisms behind the protective effect of angiotensin (1-7) in an experimental rat model of ovarian ischemia-reperfusion injury. *Life Sci* 2019; 235: 116840.
9. Ozer Sehirli A, Sener G, Ercan F. Protective effects of pycnogenol against ischemia reperfusion-induced oxidative renal injury in rats. *Ren Fail* 2009; 31(8): 690-697.
10. D'andrea G. Pycnogenol: a blend of procyanidins with multifaceted therapeutic applications? *Fitoterapia* 2010; 81(7): 724-736.
11. Ozoner B, Yuceli S, Aydin S, Yazici GN, Sunar M, Arslan YK, Coban TA, Suleyman H. Effects of pycnogenol on ischemia/reperfusion-induced inflammatory and oxidative brain injury in rats. *Neurosci Lett* 2019; 704: 169-175.
12. Turkler C, Kiremitli T, Onat T, Yildirim E, Yazici GN, Mammadov R, Sunar M. Can pycnogenol prevent cisplatin-induced damage in uterus and ovaries? *Arch Med Sci* 2022; 18(5): 1364-1371.
13. Ohkawa H, Ohishi N, Yagi K. Assay for lipid peroxides in animal tissues by thiobarbituric acid reaction. *Anal Biochem* 1979; 95(2): 351-358.
14. Sedlak J, Lindsay RH. Estimation of total, protein-bound and nonprotein sulfhydryl groups in tissue with Ellman's reagent. *Anal Biochem* 1968; 25(1): 192-205.
15. Hibbard LT. Adnexal torsion. *Am J Obstet Gynecol* 1985; 152(4): 456-461.
16. Kocaturk H, Bedir F, Altay MS, Bakan E, Suleyman B, Yazici GN, Sunar M, Suleyman Z, Suleyman H. The effect of desloratadine on ischemia reperfusion-induced oxidative and inflammatory renal injury in rats. *Ren Fail* 2020; 42(1): 531-538.
17. Park YC, Rimbach G, Saliou C, Valacchi G, Packer L. Activity of monomeric, dimeric and trimeric flavonoids on NO production, TNF-alpha secretion and NF-kappaB-dependent gene expression in RAW 264.7 macrophages. *FEBS Lett* 2000; 465(2-3): 93-97.