

## Original Research Article

# Therapeutic effect of percutaneous pedicle screw fixation, combined with Tongdu Huoxue decoction on thoracolumbar spine fracture

Pengfei Liu, Jianbin Nie\*

Department of General Trauma Surgery, The Second People's Hospital of Dongying, Dongying, Shandong 257335, China

\*For correspondence: **Email:** [niejianbin1987@163.com](mailto:niejianbin1987@163.com); **Tel:** +86-0546-6625638

Sent for review: 4 April 2022

Revised accepted: 12 July 2022

## Abstract

**Purpose:** To study the therapeutic effect of percutaneous pedicle screw fixation (PPSF) combined with Tongdu Huoxue decoction on thoracolumbar spine fractures.

**Methods:** Ninety-eight patients with thoracolumbar spine fractures treated with PPSF were retrospectively enrolled and grouped into a study group (SG, n = 51, PPSF combined with THD), and a control group (CG, n = 47, PPSF). General surgical indices, postoperative pain, postoperative Oswestry dysfunction index (ODI index), preoperative and postoperative imaging indices, and postoperative hemodynamic indices were determined and recorded.

**Results:** Patients in SG exhibited significantly lower visual analog scale (VAS) scores higher than those of CG at 3, 7 and 15 days after surgery ( $p < 0.05$ ). At 15 and 30 days after surgery, patients in SG exhibited significantly lower ODI index than those in CG ( $p < 0.05$ ). At day 60 after surgery, Cobb angle was lower in SG than in CG, while the injured vertebral body showed higher anterior height in SG than in CG. Furthermore, FIB and D-D were lower in SG than in CG at day 7, but exhibited higher PT than CG ( $p < 0.05$ ).

**Conclusion:** The combined application of PPSF and THD in patients with thoracolumbar fractures ameliorates postoperative pain levels, improves short-term spinal function, and significantly alters the postoperative coagulation index of patients, presumably by reducing the incidence of postoperative thrombosis. However, there is a need for further clinical trials prior to the introduction of this therapy into clinical practice.

**Keywords:** Percutaneous pedicle screw fixation, Tongduhuoxue decoction, Pain level, Spinal function, Coagulation index

This is an Open Access article that uses a funding model which does not charge readers or their institutions for access and distributed under the terms of the Creative Commons Attribution License (<http://creativecommons.org/licenses/by/4.0>) and the Budapest Open Access Initiative (<http://www.budapestopenaccessinitiative.org/read>), which permit unrestricted use, distribution, and reproduction in any medium, provided the original work is properly credited.

Tropical Journal of Pharmaceutical Research is indexed by Science Citation Index (SciSearch), Scopus, Web of Science, Chemical Abstracts, Embase, Index Copernicus, EBSCO, African Index Medicus, JournalSeek, Journal Citation Reports/Science Edition, Directory of Open Access Journals (DOAJ), African Journal Online, Bioline International, Open-J-Gate and Pharmacy Abstracts

## INTRODUCTION

Spinal fracture is one of the frequent injuries in orthopaedics nowadays, with its incidence related to the rapid economic development in China, traffic accidents, sports injuries, and

construction site injuries; thoracolumbar fracture ranks first in the incidence of spinal fracture [1,2]. Thoracolumbar fracture has become one of the hotspots of clinical research due to its complex pathological mechanism [3].

The percutaneous pedicle screw fixation (PPSF) provides effective three-column fixation to the damaged spine, corrects the spinal deformity, maintains the three-dimensional position of the spine, and rebuilds its mechanical stability. So it has been widely used in clinical practice [4,5]. With the wide use of PPSF in clinical practice, the shortcomings of this procedure have been gradually exposed, such as postoperative pain in some patients due to nerve injury and high incidence of venous thrombosis in the lower extremities due to long-term bedrest [6,7]. The occurrence of the above adverse reactions affects compliance of patients with the procedure to some extent, and the follow-up treatment is not convenient with regard to the effective use of medical resources. Therefore, there is an urgent need to find a comprehensive treatment modality to improve the postoperative experience of such patients.

*Tongdu Huoxue* Decoction is a traditional famous formula in Chinese traditional medicine [8]. It was confirmed that *Tongdu Huoxue* Decoction can invigorate the liver and kidney, promote blood circulation and reduce swelling, strengthen muscles and bones, and is especially suitable for patients recovering from a fracture surgery [9,10]. However, there are few research on the combination of PPSF and *Tongdu Huoxue* decoction in patients with thoracolumbar fractures. This study intends to study the therapeutic effect of PPSF combined with *Tongdu Huoxue* Decoction in patients with thoracolumbar fractures by establishing a control group, thereby providing clinical reference for improving the prognosis of such patients.

## METHODS

### General patient profile

Ninety-eight patients who were diagnosed as thoracolumbar fractures and underwent PPSF in The Second People's Hospital of Dongying from May 2018 to March 2021 were retrospectively selected, and were grouped into a study group (SG, n = 51) who received PPSF combined with *Tongdu Huoxue* decoction, (THD) and a control group (CG, n = 47) who received PPSF alone, according to the postoperative intervention they received.

### Inclusion criteria

Patients diagnosed with thoracolumbar fracture by imaging and received PPSF at the age of  $\leq 55$  years were included. The study was approved by the Ethics Committee of The Second People's

Hospital of Dongying, and conducted in line with the principles of the Declaration of Helsinki [11].

### Exclusion criteria

Patients with combined psychiatric disorders were excluded. Patients who had  $\geq 50\%$  spinal canal occupancy and neurological impairment, severe injury to the posterior longitudinal ligament complex, and intraoperative bone grafting or spinal fusion were excluded. Patients with combined systemic diseases or acute and chronic infections were also excluded. Patients with previous history of thoracolumbar fractures or paravertebral lesion, old fractures, osteoporotic fractures or pathological fractures were not included.

### Elimination criteria

Patients who were lost to follow-up, who voluntarily dropped out, who died, and who had to receive secondary surgery during the study were eliminated.

### Procedures and treatments

Both groups of patients underwent PPSF with pedicle screws. The surgeons were from the excellent spine surgery team of the hospital. Patients were notified of the surgery planning and risks, and signed a written informed consent form prior to the surgery. After entering the operating room, the patient was intubated under general anesthesia and kept in a prone position, and a median incision was made with the patient's fracture cone as the center. The pedicle screws were placed on the upper and lower adjacent cones of the fracture cone respectively to reduce the fracture site, and then the pedicle screws are fixed on the connecting rod.

After the operation, the drainage tube was drained, the wound surface was washed, and the incision was sutured. The patient was closely observed for 24 h after the operation, and was treated with routine antibiotics to prevent infection. The urine volume and drainage volume of the patients were recorded. Internal fixation was removed 12 months after surgery. Patients in CG routinely received postoperative oxygen, intravenous rehydration, cardiac monitoring, etc. In addition to the treatment given in the CG, patients in the SG were also administered with *Tongdu Huoxue* Decoction. The prescription was composed of 30 g of *Cervi Cornu Degelatinatum*, 30 g of *Cibotium barometz*, 18 g of *Salvia miltiorrhiza*, 18 g of *Astragalus*, 18 g of *Cortex eucommiae*, 18 g of *Angelica sinensis*, 18 g of *Lignum Sappan*, 18 g of *Eupatorium japonicum*

Thunb, 18 g of *Paeoniae Radix Rubra*, and 18 g of earthworm. One dose of the above drugs was decocted in water and divided into two, half in the morning and half in the evening, for 30 days.

## Evaluation of indices/parameters

### Postoperative pain level

Visual analog scale (VAS) was applied to evaluate the postoperative pain level [12]. The scale quantifies the pain level into 10 levels corresponding to 1-10 points, and patients were asked to mark a level corresponding to their own feelings, and the evaluation timing are 3, 7, 15, 30 and 60 days after surgery.

### Postoperative ODI index

Postoperative ODI index [13] consists of 10 questions including self-care, lifting, walking, standing, and sleep disturbance, ranging 0 to 50 scores, and the higher score represented the more severely affected function.

### Preoperative and postoperative imaging indicators

On a lateral x-ray of the thoracolumbar spine, a straight line was made between the upper edge of the injured vertebra and the lower edge of the inferior vertebra, and the angle between the straight line and the vertical line is the Cobb angle. The Cobb angle [14] and height of anterior edge of the injured vertebra were determined before and 60 days after surgery, respectively.

### Preoperative and postoperative coagulation function indicators

The coagulation function indicators fibrinogen (FIB), D-2 polymer (DD) and prothrombin time (PT) of the two groups of patients were analyzed before and 7 days after the operation, and FIB and DD were measured using enzyme-linked immunosorbent assay; The PT value was measured by scattered light coagulation method.

### Statistical methods

IBM Statistical Package for Social Sciences (SPSS) Statistics for Windows, Version 22.0 (IBM Corp, Armonk, USA) was chosen for statistical analysis. The measurement data were described as mean  $\pm$  standard deviation (SD). Data were tested for normal distribution and homogeneity of variance. The t-test was used for differences between groups that met normal distribution or homogeneity of variance, while Mann-Whitney U-test was performed for data

with uneven variance. Chi-square test was conducted for differences of counting data between groups. A value of  $p < 0.05$  was regarded as statistical difference. Graphpad Prism 8.3 was used for graphical analysis [15].

## RESULTS

### General patient data

The intergroup differences showed no statistical significance ( $p > 0.05$ ) in the two groups with respect to the gender, age, cause of injury, fracture segment, and underlying disease (Table 1).

### General surgical indices

The two groups showed no significant differences with respect to operative time, blood loss, volume of postoperative drainage fluid and hospital stay ( $p > 0.05$ ) (Table 2, Figure 1).

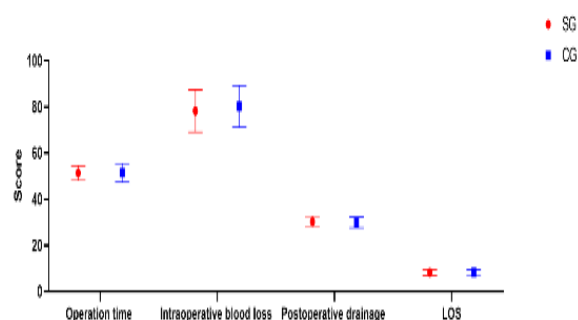


Figure 1: Comparison of surgical indicators

### Postoperative pain level

At 3, 7 and 15 days after surgery, SG showed remarkably lower pain level than CG ( $p < 0.05$ ). At 30 and 60 days after surgery, the postoperative pain level showed no differences between the two groups ( $p > 0.05$ ) (Table 3, Figure 2).

### Changes in ODI index after surgery

No statistically significant differences were found in the ODI indices between the two groups at 3 and 7 days after surgery ( $p > 0.05$ ). The ODI indices in SG at 15 and 30 days after surgery were remarkably lower than those in CG ( $p < 0.05$ ). At 60 day after surgery the difference between groups in the ODI index of patients was not statistically significant ( $p > 0.05$ , Table 4, Figure 3).

**Table 1:** Comparison of general profile {(mean  $\pm$  SD); n (%)}

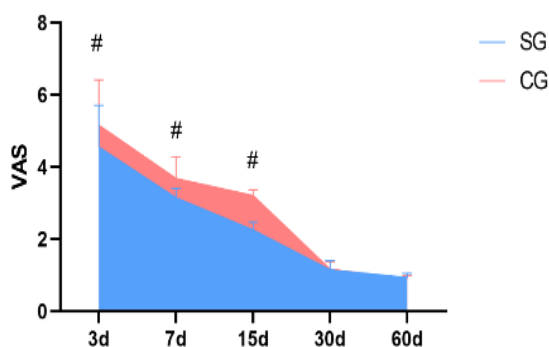
Variable		Study group (n=51)	Control group (n=47)	t/ $\chi^2$	P-value
Gender	Male	30	24	0.005	0.945
	Female	21	23		
Mean age (years)		41.11 $\pm$ 3.28	41.21 $\pm$ 3.34	0.106	0.781
Mean weight (kg)		65.18 $\pm$ 3.91	65.31 $\pm$ 3.77	0.119	0.780
Mean BMI (kg/m <sup>2</sup> )		20.19 $\pm$ 2.19	19.98 $\pm$ 2.28	0.331	0.724
Cause of injury	Traffic accident	27	20	0.889	0.231
	Falling Injuries	13	15		
	Heavy object injuries	6	7		
	Fall injuries	5	5		
Fractured segment	T11	8	6	0.891	0.221
	T12	10	10		
	L1	12	8		
	L2	14	12		
	L3	7	11		

**Table 2:** Comparison of general surgical indicators (mean ± SD)

Group	Number of cases	Operating time (min)	Intraoperative blood loss (mL)	Postoperative drainage (mL)	Length of hospitalization (days)
Study	51	51.29±3.20	78.19±9.11	30.19±2.39	8.19±1.29
Control	47	51.44±3.99	80.18±8.98	29.98±2.33	8.31±1.11
T	-	0.206	1.088	0.44	0.492
P-value	-	0.837	0.279	0.661	0.624

**Table 3:** Comparison of postoperative pain level ( $\bar{x}\pm s$ )

Group	No. of cases	Postoperative Day 3	Postoperative Day 7	Postoperative Day 15	Postoperative Day 30	Postoperative Day 60
Study	51	4.56±1.15	3.15±0.26	2.26±0.21	1.15±0.26	0.94±0.11
Control	47	5.16±1.26	3.68±0.61	3.21±0.19	1.17±0.21	0.90±0.09
T	-	2.465	5.673	23.414	0.417	1.960
P-value	-	0.015	<0.001	<0.001	0.678	0.053



**Figure 2:** Comparison of postoperative pain level. # $p < 0.05$  versus control group

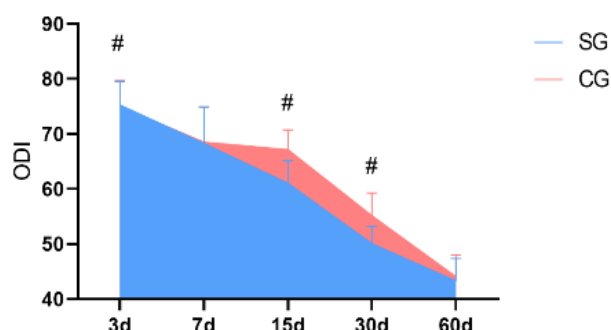
**Differences in preoperative and postoperative imaging indices**

No statistically significant differences were found in the Cobb angle and the anterior height of the injured vertebra between the two groups before

**Table 4:** Postoperative ODI index (mean ± SD)

Group	No. of cases	Postoperative Day 3	Postoperative Day 7	Postoperative Day 15	Postoperative Day 30	Postoperative Day 60
Study	51	75.26±4.26	68.25±6.69	61.01±4.15	50.05±3.16	43.26±4.11
Control	47	74.98±4.69	68.54±6.33	67.15±3.59	55.14±4.15	44.05±3.98
T	-	0.310	0.22	7.803	6.863	0.947
P-value	-	0.757	0.826	<0.001	<0.001	0.346

surgery ( $p > 0.05$ ). At 60 days after operation, SG showed lower Cobb angle and higher height of the anterior edge of the injured vertebra than CG ( $p < 0.05$ ) (Table 5, Figure 4).



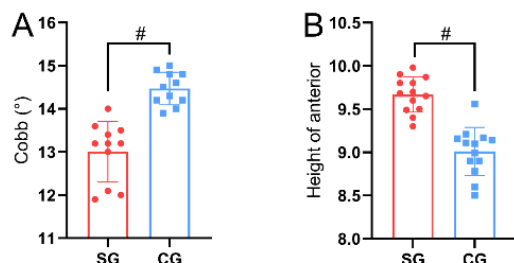
**Figure 3:** Changes in postoperative ODI index. # $p < 0.05$  versus CG

**Table 5:** Differences in preoperative and postoperative imaging indices (mean ± SD)

Group	No. of patients	Cobb angle (°)		Height of anterior margin of injured spine (cm)	
		Pre-operative	Postoperative (60 days)	Pre-operative	Postoperative (60 days)
Study	51	22.54±4.20	13.26±2.15	6.51±1.22	9.69±1.26
Control	47	23.16±3.59	14.98±1.98	6.68±1.36	9.04±1.68
T	-	0.782	4.109	0.652	2.178
P-value	-	0.436	<0.001	0.516	0.032

**Table 6:** Preoperative and postoperative coagulation indices

Group	No. of cases	FIB (g/L)		D-D (mg/L)		PT(s)	
		Pre-operative	Postoperative Day 7	Pre-operative	Postoperative Day 7	Pre-operative	Postoperative Day 7
Study	51	10.02±1.65	2.65±0.62	20.16±3.26	2.98±0.41	4.59±1.15	17.12±3.21
Control	47	9.98±1.75	4.11±0.51	19.98±3.54	5.98±1.01	4.69±1.18	12.01±2.68
T	-	0.116	12.669	0.262	19.543	0.425	8.515
P-value	-	0.908	<0.001	0.794	<0.001	0.672	<0.001



**Figure 4:** Differences in preoperative and postoperative imaging indices between the two groups. (A) The Cobb angle; (B) The anterior edge height of the injured vertebra. # $P < 0.05$  versus CG

#### Preoperative and postoperative coagulation function indices

No statistically significant differences were found in fibrinogen (FIB), D-2 aggregates (D-D), and prothrombin time (PT) between the two groups before surgery ( $p > 0.05$ ). On the 7th day after operation, the FIB and D-D of SG were lower and PT was higher than that of CG ( $p < 0.05$ , Table 6).

#### DISCUSSION

Since the application of pedicle screws in thoracolumbar fractures in 1963, PPFS has become the standard of care for thoracolumbar fractures; and some studies have demonstrated that this procedure can shorten postoperative time, reduce the incidence of venous and pressure sores in the lower extremities, and maximize preservation of motion segments [16,17]. However, long-term follow-up revealed that patients undergoing pedicle screw fixation had postoperative symptoms such as stiffness and pain in the lower back, which led to the development of PPFS.

Compared with traditional open surgery, PPFS is less invasive and less damaging to the patient, thereby facilitating postoperative recovery. However, even though the intraoperative damage to the patient's tissues is reduced, most patients undergoing PPFS also suffer from postoperative complications such as pain and difficulty in mobility, which may be due to

extensive stripping of the muscle stops and prolonged stretching and compression, postoperative muscle fiber scarring and muscle fiber edema [18].

In this study, the feasibility of *Tongdu Huoxue* Decoction in improving the prognosis of patients with thoracolumbar fractures undergoing PPFS was experimented by setting up a control group. The patients in the study group treated with *Tongdu Huoxue* Decoction showed significant improvement with reference to postoperative pain in the short term. Previous studies have pointed out that during PPFS for thoracolumbar fractures, the soft tissues and muscles around the injured vertebrae inevitably get damaged, and postoperative patients will often experience hematoma and pain symptoms [19].

The causes of postoperative pain in patients are mostly related to hematoma compression of nerves and muscle tissue damage. In modern Chinese medicine, it is believed that Du meridian dominates the *yang* of the whole body, and the meridians run *qi* and blood. Therefore, when Du meridian is damaged, the *Qi* stagnation and blood stasis occur. The *Cervi Cornu Degelatinatum* in *Tongdu Huoxue* decoction (THD) can nourish the liver and kidney, as well as promote blood and reduce swelling.

*Cibotium barometz* warms the kidneys, enhances the *yang*, nourishes the essence and replenish the marrow. *Paeoniae Radix Rubra* can remove blood stasis and relieve pain. All of these herbs play roles in improving postoperative pain [20,21]. This is also reflected in the fact that the postoperative coagulation indexes in the SG were superior to those in the CG. The comparison showed that patients in the SG had lower FIB and DD than those in the CG 7 days after the operation, and had higher PT than the CG, suggesting that the patients in the group had improved microcirculation and smoother blood flow after operation. Existing studies have pointed out that patients with thoracolumbar fractures have long-term immobilization after surgery, and slow blood flow in the individual, especially the lower extremities.

Combined with the impact of intraoperative trauma, some patients will be in a state of hypercoagulability after surgery, and be prone to deep vein thrombosis of the lower extremity as well as pulmonary diseases [22]. It was shown that the postoperative coagulation indexes of the SG were better than those of the CG, owing to the efficacy of *Tongdu Huoxue* Decoction in promoting blood circulation, eliminating blood stasis and generating new blood. Modern pharmacology has confirmed that *Cibotium barometz* inhibits platelet aggregation and has anti-inflammatory and antibacterial effects, and *Paeoniae Radix Rubra* reduces blood coagulation and improves blood viscosity. All these herbs can help improve the postoperative hemodynamics and have great significance in improving the prognosis of patients.

In the present study, it was also found that the ODI index and imaging indices of patients in the SG were superior to those in the CG in the short postoperative period. A controlled study conducted in 98 thoracolumbar fracture cases found that the combination of antiplatelet aggregation drugs in the postoperative period reduced the rate of postoperative thrombosis, and also improved the function of the vertebral body [23]. This shall be attributed to the fact that these herbs could regulate the body's hemodynamics. The combination of the above herbs in THD may improve local microcirculation and perfusion in the fracture site. In addition, it increases the blood and oxygen supply to the fracture site, and finally relieves local pain and accelerates the recovery of the fracture site.

### Limitations of the study

The shortcomings of this study are that the overall sample size was small, and the source was relatively simple. Therefore, the conclusions may be subjective or biased. Thus, the persuasiveness is not comparable to that of multicenter large sample studies, and this is intended to be improved on at a later stage.

### CONCLUSION

The findings of this study indicate that *Tongdu Huoxue* decoction, when combined with FFPS, mitigates postoperative pain as well as improves short-term spinal function, thus affecting postoperative coagulation. It is speculated to help reduce the incidence of postoperative thrombosis. The findings of this study may facilitate the investigation of the effect of Chinese medicine on pain control and other functions in thoracolumbar fractures.

### DECLARATIONS

#### Acknowledgements

None provided.

#### Funding

None provided.

#### Ethical approval

None provided.

#### Availability of data and materials

The datasets used and/or analyzed during the current study are available from the corresponding author on reasonable request.

#### Conflict of Interest

No conflict of interest associated with this work.

#### Contribution of Authors

The authors declare that this work was done by the authors named in this article and all liabilities pertaining to claims relating to the content of this article will be borne by them.

#### Open Access

This is an Open Access article that uses a funding model which does not charge readers or their institutions for access and distributed under the terms of the Creative Commons Attribution License (<http://creativecommons.org/licenses/by/4.0>) and the Budapest Open Access Initiative (<http://www.budapestopenaccessinitiative.org/read>), which permit unrestricted use, distribution, and reproduction in any medium, provided the original work is properly credited.

### REFERENCES

1. Qi Y, Wang W, Sun W, Pan Q. Comparative efficacy and safety of alendronate and teriparatide in bone loss reduction and prevention of vertebral fracture in osteoporotic Chinese patients. *Trop J Pharm Res* 2021; 20(10): 2199-2204 doi: 10.4314/tjpr.v20i10.26
2. Prajapati HP, Kumar R. Thoracolumbar fracture classification: evolution, merits, demerits, updates, and concept of stability. *Br J Neurosurg* 2021; 35(1): 92-97.
3. Hou C, Li J, Wang X, Zhu L, Li M. Comparison of efficacy and safety of teriparatide and hyaluronic acid - calcitonin combination treatments in Chinese osteoporotic patients with risk of bone fracture: A preliminary investigation.

- Trop J Pharm Res* 2020; 19(1): 183-188 doi: 10.4314/tjpr.v19i1.26
4. Chen Y, Yin P, Hai Y, Su Q, Yang J. Is Osteoporotic Thoracolumbar Burst Fracture a Contraindication to Percutaneous Kyphoplasty? A Systematic Review. *Pain Physician* 2021; 24(6): E685-E692.
  5. Filgueira EG, Imoto AM, Da SH, Meves R. Thoracolumbar Burst Fracture: McCormack Load-sharing Classification: Systematic Review and Single-arm Meta-analysis. *Spine (Phila Pa 1976)* 2021; 46(9): E542-E550.
  6. Rajasekaran S, Kanna RM, Schnake KJ, Vaccaro AR, Schroeder GD, Sadiqi S, Oner C. Osteoporotic Thoracolumbar Fractures-How Are They Different? - Classification and Treatment Algorithm. *J Orthop Trauma* 2017; 31 Suppl 4: S49-S56.
  7. Kapoen C, Liu Y, Bloemers FW, Deunk J. Pedicle screw fixation of thoracolumbar fractures: conventional short segment versus short segment with intermediate screws at the fracture level-a systematic review and meta-analysis. *Eur Spine J* 2020; 29(10): 2491-2504.
  8. Mazel C, Ajavon L. Malunion of post-traumatic thoracolumbar fractures. *Orthop Traumatol Surg Res* 2018; 104(1S): S55-S62.
  9. Rosenthal BD, Boody BS, Jenkins TJ, Hsu WK, Patel AA, Savage JW. Thoracolumbar Burst Fractures. *Clin Spine Surg* 2018; 31(4): 143-151.
  10. Cook E, Scantlebury A, Booth A, Turner E, Ranganathan A, Khan A, Ahuja S, May P, Rangan A, Roche J, et al. Surgery versus conservative management of stable thoracolumbar fracture: the PRESTO feasibility RCT. *Health Technol Assess* 2021; 25(62): 1-126.
  11. The World Medical Association Declaration of Helsinki. *World Med J* 2008;54: 122-125.
  12. Zhang C, Liu Y. Combined pedicle screw fixation at the fracture vertebrae versus conventional method for thoracolumbar fractures: A meta-analysis. *Int J Surg* 2018; 53: 38-47.
  13. Aly MM, Al-Shoaibi AM, Al-Aithan A, AlJuzair AH, Almasoudi T, AlFattani A, Eldawoody H. Can Vertical Lamina Fracture Further Discriminate Fracture Severity Between Thoracolumbar AO Type A3 and A4 Fractures? *World Neurosurg* 2021; 155: e177-e187.
  14. Chen Z, Song C, Chen M, Li H, Ye Y, Liu W. What are risk factors for subsequent fracture after vertebral augmentation in patients with thoracolumbar osteoporotic vertebral fractures. *BMC Musculoskelet Disord* 2021; 22(1): 1040.
  15. Lan T, Chen Y, Hu SY, Li AL, Yang XJ. Is fusion superior to non-fusion for the treatment of thoracolumbar burst fracture? A systematic review and meta-analysis. *J Orthop Sci* 2017; 22(5): 828-833.
  16. Choudhury AM, Alam MS, Saha MK, Jonayed SA, Rasel MH, Akter K. Short Segment Pedicle Screw Fixation Including Fracture Vertebrae for the Management of Unstable Thoracolumbar Burst Fracture. *Mymensingh Med J* 2021; 30(2): 485-492.
  17. Dong H, Hu L, Ruan B, Yu H, Xu X, Sun H, Feng X, Yang J, Wang Y, Tao Y. Clinical Outcomes of Thoracolumbar Burst Fracture Treated by Trans-Kambin triangle versus Transpedicular Bone Grafting Combined with Posterior Internal Fixation. *World Neurosurg* 2021; 156: e130-e138.
  18. Chung WH, Eu WC, Chiu CK, Chan C, Kwan MK. Minimally invasive reduction of thoracolumbar burst fracture using monoaxial percutaneous pedicle screws: Surgical technique and report of radiological outcome. *J Orthop Surg (Hong Kong)* 2020; 28(1): 615549265.
  19. Meyblum J, Portella T, Coudert P, Prost S, Mazas S, Barut N, Khalife M, Marie-Hardy L. Management of thoracolumbar fracture in France. Analysis of practices and radiologic results of a cohort of 407 thoracolumbar fractures. *Orthop Traumatol Surg Res* 2020; 106(6): 1203-1207.
  20. Chen JL, Xu Y, Wan L, Yao GX. Surgical choice of posterior osteotomy way for senile osteoporotic thoracolumbar fracture with kyphosis. *Zhongguo Gu Shang* 2020; 33(2): 121-126.
  21. Laghmouche N, Prost S, Farah K, Graillon T, Blondel B, Fuentes S. Minimally invasive treatment of thoracolumbar flexion-distraction fracture. *Orthop Traumatol Surg Res* 2019; 105(2): 347-350.
  22. Zhang X, Li S, Zhao X, Christiansen BA, Chen J, Fan S, Zhao F. The mechanism of thoracolumbar burst fracture may be related to the basivertebral foramen. *Spine J* 2018; 18(3): 472-481.
  23. Habibi H, Takahashi S, Hoshino M, Takayama K, Sasaoka R, Tsujio T, Yasuda H, Kanematsu F, Kono H, Toyoda H, et al. Impact of paravertebral muscle in thoracolumbar and lower lumbar regions on outcomes following osteoporotic vertebral fracture: a multicenter cohort study. *Arch Osteoporos* 2021; 16(1): 2.