

## Original Research Article

# Short-term and long-term outcomes of zirconium dioxide-based dental restorations, and its effects on masticatory function

Guodong Peng<sup>1</sup>, Hui Yan<sup>2\*</sup>

<sup>1</sup>Department of Stomatology, Jingzhou No. 1 People's Hospital and First Affiliated Hospital of Yangtze University, Jingzhou,

<sup>2</sup>The First People's Hospital of Yichang, The People's Hospital of China Three Gorges University, Yichang 443000, China

\*For correspondence: **Email:** yanhui\_20161103@163.com; **Tel:** +86-13545857736

Sent for review: 18 January 2022

Revised accepted: 26 May 2022

### Abstract

**Purpose:** To investigate the short- and long-term outcomes of zirconium dioxide-based restorations (ZDBR), and changes in masticatory function (MF).

**Methods:** One hundred and two (102) patients who received restorative dentistry procedures were divided into two groups using random number method: control group (CG, n = 52, alloy-based restorations) and study group (SG, n = 50, zirconium dioxide restorations). Treatment efficacy, quality, levels of IL-8 and IL-6 in gingival sulcus fluid, and satisfaction scores were compared.

**Results:** The SG showed better outcomes and restoration quality than CG. After restoration, SG showed greater decrease in IL-8 and IL-6 levels than CG ( $p < 0.05$ ), while IL-8 and IL-6 levels were higher in SG and CG than those before restoration ( $p < 0.05$ ). After 1 and 6 months of restoration, SG showed increased dental appearance satisfaction and a higher success rate than CG ( $p < 0.05$ ). Occlusal force and MF were significantly improved in both groups ( $p < 0.05$ ). Gingival index, bleeding index, plaque index, and tooth looseness after restoration significantly improved in both groups, but were lower in SG than in CG ( $p < 0.05$ ).

**Conclusion:** In oral restorations, ZDBR is more effective in terms of short-term and long-term outcomes. Patients' occlusal force and MF are better restored, and patients' quality of life is also significantly improved. Therefore, ZDBR in oral restorations is feasible but further clinical trials are required.

**Keywords:** Restorative dentistry, Zirconia restorations, Short- and long-term, Masticatory function, Occlusal force

This is an Open Access article that uses a funding model which does not charge readers or their institutions for access and distributed under the terms of the Creative Commons Attribution License (<http://creativecommons.org/licenses/by/4.0>) and the Budapest Open Access Initiative (<http://www.budapestopenaccessinitiative.org/read>), which permit unrestricted use, distribution, and reproduction in any medium, provided the original work is properly credited.

Tropical Journal of Pharmaceutical Research is indexed by Science Citation Index (SciSearch), Scopus, International Pharmaceutical Abstract, Chemical Abstracts, Embase, Index Copernicus, EBSCO, African Index Medicus, JournalSeek, Journal Citation Reports/Science Edition, Directory of Open Access Journals (DOAJ), African Journal Online, Bioline International, Open-J-Gate and Pharmacy Abstracts

## INTRODUCTION

Restorative dentistry is a very crucial part of clinical dentistry, which mainly refers to artificial restoration of dental and oral tissue defects [1]. The number of oral diseases has been on the

increase, and this is closely related to poor living environments and unhealthy dietary habits. Meanwhile, with continuous improvement in people's living standards and their aesthetic requirements, more and more people prefer to go to hospitals to improve their aesthetics through

oral prosthetics [2]. In oral prosthetics, the popular metal-ceramic restorations have the advantages of wear resistance, corrosion resistance, and high biocompatibility. However, it has been observed in clinical practice that the strength of the restorations is low, with low gloss and translucency values. They are prone to stain in daily life and have low aesthetics, which limited its clinical applications [3].

Zirconium dioxide is an inorganic nonmetallic material with the advantages of anti-corrosion, anti-high temperature, and abrasion resistance [4]. It has been clinically found to be more biocompatible, less susceptible to saliva and gingival sulcus corrosion, more malleable, and can be adjusted in color, which has a higher value for treatment in oral prosthetics [5].

In this study, 102 patients in the Department of Restorative Dentistry admitted to the People's Hospital and First Affiliated Hospital of Yangtze University, Jingzhou, were enrolled, while the efficacy and changes in masticatory function were investigated for near and future purposes.

## METHODS

### General patient profile

A total of 102 patients admitted for treatment with oral prosthesis were divided into two groups using a random number method. These are: control group (CG, n = 52) and study group (SG, n = 50). In the CG, there were 52 cases comprising 29 males and 23 females, with an average age of  $45.5 \pm 2.3$  years and an average disease duration of  $1.3 \pm 0.2$  months. Among them, there were 13 cases with missing dentition, 18 cases of dentition defect and 21 cases of tooth defect. In the SG, there were 50 cases, 28 males and 22 females, with an average age of  $45.6 \pm 2.3$  years and an average disease duration of  $1.4 \pm 0.2$  months. Among them, 13 cases had missing dentition, 18 cases had dentition defect, and 19 cases had tooth defect. The study subjects agreed to participate in the study, and the data of the two groups were comparable ( $p > 0.05$ ). The Ethical Committee of Jingzhou No. 1 People's Hospital approved the study (approval no. JZ-16-302-02), and was conducted following the guidelines stated in the Declaration of Helsinki [6].

### Inclusion criteria

(1) All met the diagnostic criteria of oral diseases; (2) aged over 18 years old; (3) no other infectious diseases; and (4) all were informed about the study procedures.

### Exclusion criteria

(1) Abnormal masticatory function existed before treatment; (2) incomplete data; and (3) unwillingness to participate in the study [7].

### Preparation and fixing of the crown

Alloy dental restorations were prepared for the patients, and impressions were taken in terms of size and accuracy, and the color selected for each patient was one that was similar to the color of the patient's teeth. The alloy metal-ceramic crowns were made based on the results of the impressions and the chosen tooth color. After completion, the patient was allowed to wear the crown for 6 - 7 days, and if there was no discomfort, it was fixed using glass ionomer cement.

For zirconium dioxide-based restoration, the patient was then given an inner crown, molded and colored according to the size of the tooth, and the all-porcelain crown was processed. After completion, the patient was allowed to wear the crown for 6 - 7 days, and if there was no discomfort, it was fixed using glass ionomer cement.

### Evaluation of parameters/indicators

#### Restoration

*Poor:* The pulp vitality of the patient appeared to be insufficient after treatment, and there were obvious differences in the luster and color compared with the surrounding dentition.

*Good:* The prosthesis of the patient remained intact after treatment, and there were no big differences in the luster and color compared with the surrounding dentition; *Excellent:* The pulp vitality of the patient returned to normal after treatment, and the luster and color of the surrounding dentition were exactly the same as the restoration [8].

#### Restoration quality

The prosthesis was evaluated for cracks, fracture, and marginal closeness [9].

#### IL-8 and IL-6 in gingival sulcus fluid

Gingival sulcus fluid was collected from all patients before and after restoration, and ELISA was performed to detect IL-8 and IL-6 levels (Shanghai Enzyme Linkage Biotechnology Company) according to the kit instructions [10].

### **Dental appearance satisfaction and success rate after 1 month and 6 months of restoration [11]**

*Satisfactory:* The appearance and color of the restorations were consistent with the adjacent healthy teeth, and there was no discomfort and foreign body sensation.

*Unsatisfactory:* There were obvious differences between the appearance and color of the restorations and the adjacent healthy teeth, and there was serious discomfort and foreign body sensation.

*Very successful:* The appearance and color of the restoration is consistent with the healthy teeth and gums, no complications, wear, discoloration, and loss.

*Failure:* the appearance and color of the restoration is significantly different from the healthy teeth and gums, and serious complications have occurred.

### **Occlusal force and masticatory function**

The occlusal force of the patient's mandibular first molars was measured using bite force measuring (BFM) device, and the patient's masticatory function was evaluated using the weighing method before, 2 weeks, 1 month, and 6 months after the restoration [12]. Gingival index, bleeding index, plaque index, and tooth looseness [13]. *Gingival index:* the gingiva of each tooth was examined to assess the gingival index, with a score between 0 and 3, the higher the score the worse condition; *Bleeding index:* the shape and color of the patient's gingiva were observed, and a blunt-tipped periodontal probe lightly detect the gingival sulcus, with a score between 0 and 5, the higher the score the worse the condition; *Plaque index: 0 points:* no gingival margin plaque was found upon visual diagnosis; 1: thin gingival margin plaque existed on the tooth surface, but could not be seen by visual diagnosis. The existence of plaque could be determined using the probe tip to scrape the tooth surface; 2: a moderate amount of plaque

existed in the gingival margin area or adjacent area; 3: a large amount of plaque existed in the gingival sulcus area or gingival margin area or adjacent area, the higher the score, the worse the condition; *Tooth looseness:* Grade 1 is 1 - 2 mm tooth mobility; Grade 2 is tooth mobility greater than 2 mm, without vertical movement of tooth; Grade 3 is tooth mobility greater than 3 mm. Tooth is mobile in all planes and move vertically in its socket. Quality of life was assessed using the SF-36 scale, with 8 items, ranging 0 - 100 points. The lower the score, the worse the condition [14]. *Periodontal probing depth (PD):* The smaller the value, the better the patient's periodontal health.

### **Statistical analysis**

The data were analyzed using Statistical Package for the Social Sciences (SPSS) 24.0 software (IBM, Armonk, NY, USA). Measurement data are expressed as mean  $\pm$  standard deviation (SD). Student's t-test was performed for comparison between two groups, while  $\chi^2$  test was used to test the count data (%).  $P < 0.05$  was considered statistically significant; GraphPad Prism 8 software (La Jolla, CA, USA) was used for plotting graphs.

## **RESULTS**

### **Efficacy**

The good + excellent rate in the SG and CG was 94.0 % (47/50) and 76.9 % (40/52), respectively, which was higher in the SG than that in CG ( $p < 0.05$ , Table 1).

### **Restoration quality**

The SG had 0 and 0 cracks and fractured restorations, respectively, with good marginal fit of 96.0 % (48/50), while the CG had 9.6 % (5/52) cracks and 11.5 % (6/52) fractured restorations, respectively, with good marginal fit of 65.4 % (34/52). The SG had higher restoration quality than the CG ( $p < 0.05$ , Table 2).

**Table 1:** Comparison of restoration outcomes (cases, %)

Group	Number of cases	Poor	Good	Excellent	Excellent (%)
Control group	52	8	27	17	84.6
Study group	50	2	21	27	96.0
$\chi^2$					5.213
P-value					<0.05

**Table 2:** Comparison of restoration quality (cases, %)

Group	Number of cases	Cracks	Fracture	Good edge fit
Control	52	5 (9.6)	6 (11.5)	34 (65.4)
Study	50	0 (0)	0 (0)	48 (96.0)
$\chi^2$		5.025	4.458	5.111
<i>P</i> -value		<0.05	<0.05	<0.05

**Table 3:** Comparison of IL-8 and IL-6 levels in gingival sulcus fluid (mean  $\pm$  SD)

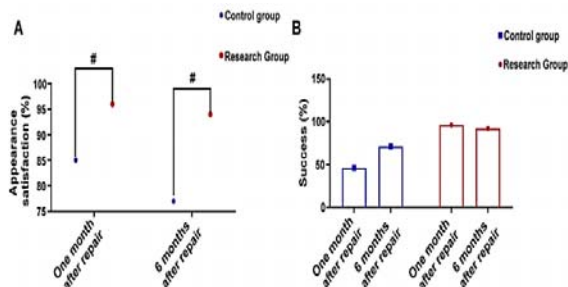
Group	No. of cases	IL-8 (ng/L)		IL-6 (ng/L)	
		Before repair	After repair	Before repair	After repair
Control	52	50.1 $\pm$ 11.2	84.2 $\pm$ 17.2	16.3 $\pm$ 4.2	31.1 $\pm$ 9.1
Study	50	50.2 $\pm$ 11.3	72.1 $\pm$ 15.3	16.2 $\pm$ 4.1	24.0 $\pm$ 7.6
T		1.328	16.634	1.217	13.540
<i>P</i> -value		>0.05	<0.05	>0.05	<0.05

**Levels IL-8 and IL-6 in gingival sulcus fluid**

Before restoration, there was no significant difference in IL-8 and IL-6 levels between the two groups ( $p > 0.05$ ); After restoration, IL-8 and IL-6 levels of SG were lower than those of CG ( $p < 0.05$ ); IL-8 and IL-6 levels of the SG and CG were higher than those before restoration ( $p < 0.05$ ), but the elevation was smaller in SG (Table 3).

**Cosmetic satisfaction and success**

Cosmetic satisfaction and success after 1 month and 6 months of restoration were higher in SG than in CG ( $p < 0.05$ , Figure 1).

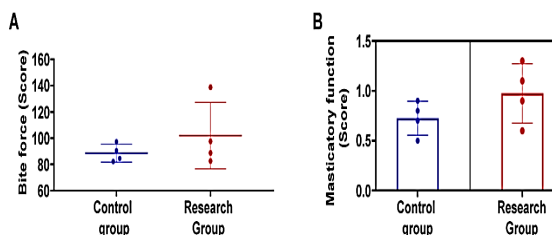


**Figure 1:** Comparison of (A) appearance satisfaction and (B) success after 1 month and 6 months of restoration between the two groups ( $p < 0.05$ )

**Occlusal force and masticatory function**

Before the restoration, there were no significant differences in occlusal force and masticatory function between two groups ( $p > 0.05$ ). After restoration, occlusal force and masticatory function in the SG were greater than those in the CG ( $p < 0.05$ ). After the restoration, occlusal force and masticatory function in the SG and the CG were greater than those before the

restoration ( $p < 0.05$ ). However, the increase was greater in the SG (Figure 2).



**Figure 2:** Comparison of (A) occlusal force and (B) masticatory function between the two groups before restoration, ( $p > 0.05$ ) and after restoration, ( $p < 0.05$ )

**Gingival index, bleeding index, plaque index, and tooth loosening**

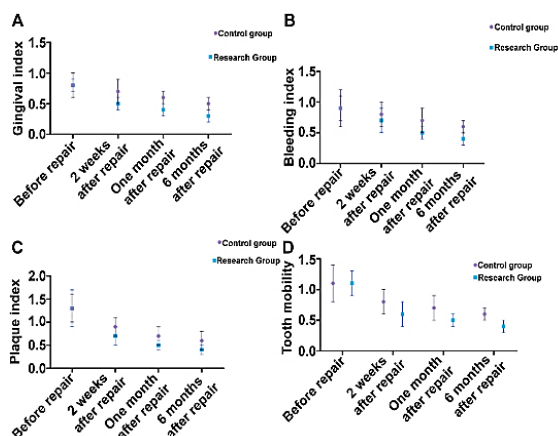
Before restoration, there was no significant difference in gingival index, bleeding index, plaque index, and tooth loosening between two groups ( $p > 0.05$ ). After restoration, the gingival index, bleeding index, plaque index, and tooth loosening in the SG were smaller than those in the CG ( $p < 0.05$ ). These indexes decreased in both groups ( $p < 0.05$ ), but the decrease was greater in the SG (Figure 3).

**Quality of life**

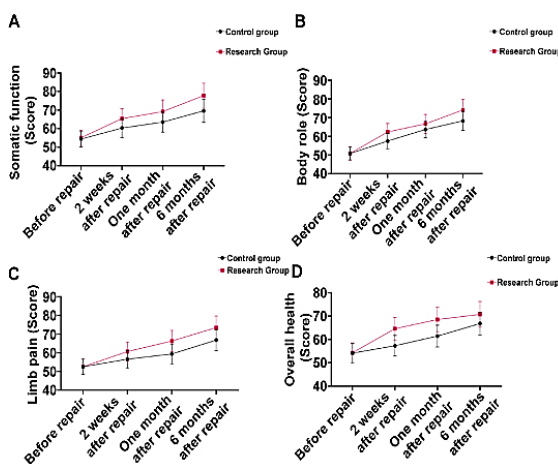
Before restoration, there was no significant difference in the quality of life between two groups ( $p > 0.05$ ). After restoration, the quality of life in the SG was higher than that in the CG ( $p < 0.05$ ) (Figure 4).

**Comparison of PD**

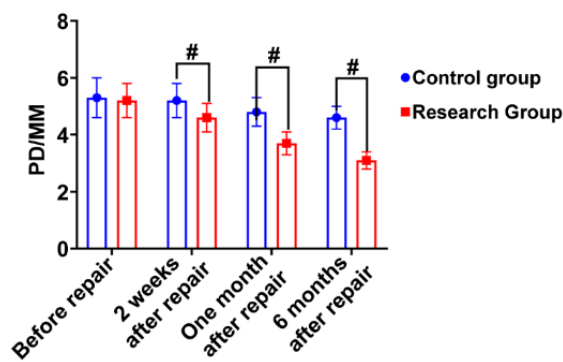
Before restoration, there was no significant difference in PD between two groups ( $P > 0.05$ ). After restoration, PD decreased significantly in both groups ( $p < 0.05$ , Figure 5).



**Figure 3:** Comparison of (A) gingival index, (B) bleeding index, (C) plaque index, and (D) tooth loosening before restoration, ( $p > 0.05$ ) and after restoration, ( $p < 0.05$ ) between the study group the control group



**Figure 4:** Comparison of quality of life (A) somatic function, (B) body role, (C) limb pain, (D) overall health, before repair, ( $p > 0.05$ ), two weeks, one month and six months after repair, ( $p < 0.05$ )



**Figure 5:** Comparison of PD between the two groups. Before restoration, ( $p > 0.05$ ). After restoration, ( $p < 0.05$ )

## DISCUSSION

In the treatment of oral diseases, it is necessary to restore dental defects and dentition in order to maximize the improvement of the patient's masticatory function, and the selection of suitable restorative materials is a key to the outcomes [15]. The most commonly used restorative material is nickel-chromium alloy due to its high wear resistance, fracture resistance, and good texture and realistic color [16]. However, it has been found that the edges of their inner crowns are susceptible to erosion by food, saliva, and gingival sulcus, and over time, the restorations may have root fracture, material discoloration, and a dull appearance, which reduced the patient's masticatory function and have an impact on the restorative outcome [17].

The results of this study showed that the restorative process in SG was greater than that in CG ( $p < 0.05$ ), and the satisfaction with appearance and success after 1 month and 6 months of restoration in the SG was higher than that of the CG ( $p < 0.05$ ). These results correlated with advantages of zirconia restorations. The performance of the material is enhanced with higher fracture strength, which lays the foundation for improving the patient's masticatory function [18]. The material and aesthetics of the restorations are improved, with a color that is more similar to periodontal tissue, resulting in a higher degree of aesthetics [19]. It is compatibility with periodontal tissues, can resist decay and reduce complications [20].

The results of this study showed that before restoration, there was no significant difference between the two groups in terms of occlusal force and masticatory function ( $p > 0.05$ ). After restoration, the occlusal force and masticatory function of SG were greater than those of CG ( $p < 0.05$ ). After restoration, the occlusal force and masticatory function of SG and CG were greater than those before restoration ( $p < 0.05$ ). However, the elevation was greater in SG, therefore, zirconium dioxide based restorations were more effective and more beneficial to improve the occlusal force and masticatory function [21]. The results of the study showed that before restoration, there was no significant difference in PD between two groups ( $p > 0.05$ ). After restoration, PD decreased significantly in both groups, but the decrease was more pronounced in the CG ( $p < 0.05$ ). The results confirmed that PD changed significantly after the restoration when compared with that before the restoration, which was beneficial to the improvement of the patient's masticatory function. Although the performance of metal

restorations is better and can ensure the patient's masticatory function, the masticatory function decreases as the material is corroded, which can have an impact on the restorative effect [22]. In contrast, zirconium dioxide is a new material that could resist corrosion by gingival sulcus and saliva, therefore, the patient's masticatory function is ensured, while reducing plaque, bleeding, and tooth loosening [23,24].

The results showed that before restoration, there was no significant difference in IL-8 and IL-6 levels between the two groups ( $p > 0.05$ ). After restoration, IL-8 and IL-6 levels in the SG were lower than those in the CG ( $p < 0.05$ ). After restoration, IL-8 and IL-6 levels in SG and CG were higher than those before restoration ( $p < 0.05$ ), suggesting that zirconia restorations are more effective, and the absence of metallic materials in zirconia restorations can better reduce the impact on gingival tissues, thereby minimizing inflammation and ultimately improving the quality of life [25,26].

## CONCLUSION

Zirconium dioxide-based restoration produces good efficacy in terms of short- and long- term outcomes, with better recovery of occlusal force and masticatory function, and significant improvement in the quality of life. Therefore, zirconium dioxide restoration is feasible, but further clinical trials are required.

## DECLARATIONS

### Conflict of Interest

No conflict of interest associated with this work.

### Contribution of Authors

The authors declare that this work was done by the authors named in this article and all liabilities pertaining to claims relating to the content of this article will be borne by them.

### Open Access

This is an Open Access article that uses a funding model which does not charge readers or their institutions for access and distributed under the terms of the Creative Commons Attribution License (<http://creativecommons.org/licenses/by/4.0>) and the Budapest Open Access Initiative (<http://www.budapestopenaccessinitiative.org/read>), which permit unrestricted use, distribution, and reproduction in any medium, provided the original work is properly credited.

## REFERENCES

1. Shahmiri R, Standard OC, Hart JN, Sorrell CC. Optical properties of zirconia ceramics for esthetic dental restorations: A systematic review. *J Prosthet Dent* 2018; 119(1): 36-46.
2. Wu Z, Yang X, Li N. Effects of different immunosuppressive drugs on the periodontal status and changes in periodontal pathogenic bacterial flora in rheumatoid arthritis patients. *Trop J Pharm Res* 2021; 20(10): 2219-2226.
3. Oyar P, Durkan R. Effect of cavity design on the fracture resistance of zirconia onlay ceramics. *Niger J Clin Pract* 2018; 21(6): 687-691.
4. Maroulakos G, Thompson GA, Kontogiorgos ED. Effect of cement type on the clinical performance and complications of zirconia and lithium disilicate tooth-supported crowns: A systematic review. Report of the Committee on Research in Fixed Prosthodontics of the American Academy of Fixed Prosthodontics. *J Prosthet Dent* 2019; 121(5): 754-765.
5. Poggio CE, Ercoli C, Rispoli L, Maiorana C, Esposito M. Metal-free materials for fixed prosthodontic restorations. *Cochrane Database Syst Rev* 2017; 12: D9606.
6. Stockhausen K. The Declaration of Helsinki: revising ethical research guidelines for the 21st century. *Med J Aust* 2000; 172(6): 252-253.
7. Tabesh M, Nejatidanesh F, Savabi G, Davoudi A, Savabi O, Mirmohammadi H. Marginal adaptation of zirconia complete-coverage fixed dental restorations made from digital scans or conventional impressions: A systematic review and meta-analysis. *J Prosthet Dent* 2021; 125(4): 603-610.
8. Ghodsi S, Jafarian Z. A review on translucent zirconia. *Eur J Prosthodont Restor Dent* 2018; 26(2): 62-74.
9. Solderer A, Al-Jazrawi A, Sahrman P, Jung R, Attin T, Schmidlin PR. Removal of failed dental implants revisited: Questions and answers. *Clin Exp Dent Res* 2019; 5(6): 712-724.
10. Tang Z, Zhao X, Wang H, Liu B. Clinical evaluation of monolithic zirconia crowns for posterior teeth restorations. *Medicine (Baltimore)* 2019; 98(40): e17385.
11. Tabatabaian F, Bakhshaei D, Namdari M. Effect of resin cement brand on the color of zirconia-based restorations. *J Prosthodont* 2020; 29(4): 350-355.
12. Afrashtehfar KI, Del FM. Clinical performance of zirconia implants: A meta-review. *J Prosthet Dent* 2020; 123(3): 419-426.
13. Pieralli S, Kohal RJ, Jung RE, Vach K, Spies BC. Clinical outcomes of zirconia dental implants: A systematic review. *J Dent Res* 2017; 96(1): 38-46.
14. Schmoeckel J, Gorseta K, Splieth CH, Juric H. How to intervene in the caries process: Early childhood caries - A systematic review. *Caries Res* 2020; 54(2): 102-112.
15. Soult MD, Lien W, Savett DA, Gallardo FF, Vandewalle KS. Effect of high-speed sintering on the properties of a zirconia material. *Gen Dent* 2019; 67(5): 30-34.

16. Al HK, Obaidat II, Baba NZ. The effect of ceramic type and background color on shade reproducibility of all-ceramic restorations. *J Prosthodont* 2020; 29(6): 511-517.
17. Papadiochou S, Pissiotis AL. Marginal adaptation and CAD-CAM technology: A systematic review of restorative material and fabrication techniques. *J Prosthet Dent* 2018; 119(4): 545-551.
18. Lawson NC, Jurado CA, Huang CT, Morris GP, Burgess JO, Liu PR, Kinderknecht KE, Lin CP, Givan DA. Effect of surface treatment and cement on fracture load of traditional zirconia (3Y), translucent zirconia (5Y), and lithium disilicate crowns. *J Prosthodont* 2019; 28(6): 659-665.
19. Buchanan A, Orta A, Kalathingal S. Postprocessing of all-zirconia restorations in digital dental radiographs: a quality assurance predicament. *Oral Surg Oral Med Oral Pathol Oral Radiol* 2019; 127(4): 330-338.
20. AlAmar M, Alqahtani F. Effect of different implant-abutment connection materials on the fracture resistance of zirconia abutments. *J Oral Implantol* 2020; 46(2): 88-92.
21. Skjold A, Schriwer C, Gjerdet NR, Oilo M. Effect of artificial aging on high translucent dental zirconia: simulation of early failure. *Eur J Oral Sci* 2020; 128(6): 526-534.
22. Sadid-Zadeh R, Strazzella A, Li R, Makwoka S. Effect of zirconia etching solution on the shear bond strength between zirconia and resin cement. *J Prosthet Dent* 2021; 126(5): 693-697.
23. Campos T, Ramos NC, Matos J, Thim GP, Souza R, Bottino MA, Valandro LF, Melo RM. Silica infiltration in partially stabilized zirconia: Effect of hydrothermal aging on mechanical properties. *J Mech Behav Biomed Mater* 2020; 109: 103774.
24. Yilmaz ST, Aykent F. Effect of fabrication techniques on the optical properties of zirconia-based systems. *J Prosthet Dent* 2021; 125(3): 521-528.
25. Iwaguro S, Shimoe S, Hirata I, Murayama T, Satoda T. Effect of microslit retention on the bond strength of zirconia to dental materials. *Dent Mater J* 2019; 38(6): 1043-1052.
26. Franz A, Winkler O, Lettner S, Oppinger S, Hauser A, Haidar M, Moritz A, Watts DC, Schedle A. Optimizing the fitting-surface preparation of zirconia restorations for bonding to dentin. *Dent Mater* 2021; 37(3): 464-476.