

Original Research Article

Diagnostic efficacy of two-dimensional echocardiography combined with coronary angiogram in patients with acute myocardial infarction, and the effectiveness of atorvastatin

Lijuan Liao¹, Wenwu Huang², Chun Xiong^{3*}

¹B Ultrasound Room, ²Department of Anorectal Surgery, ³Imaging Department, Affiliated Hospital of Jinggangshan University, Ji'an 343000, China

*For correspondence: **Email:** xiong3547920991@126.com

Sent for review: 19 February 2022

Revised accepted: 19 May 2022

Abstract

Purpose: To investigate the diagnostic significance of two-dimensional echocardiography (2DE) combined with coronary angiogram in patients with acute myocardial infarction, and to determine the effectiveness of atorvastatin.

Methods: Patients ($n = 100$) with acute myocardial infarction admitted in Affiliated Hospital of Jinggangshan University, Ji'an, China, were divided into control group (CG) treated with conventional therapy, and study group (EG) treated with atorvastatin, in addition to conventional therapy. The diseased vessels examined by echocardiography and coronary angiogram were recorded and compared. The effectiveness of atorvastatin treatment was assessed by evaluating myocardial injury, oxidative stress, vascular injury and cardiac function indices, viz, left ventricular ejection fraction (LVEF), left ventricular end-diastolic internal diameter (LVEDD), left ventricular end-systolic internal diameter (LVESD), left ventricular end-diastolic volume (LVEDV), left ventricular end-systolic volume (LVESV).

Results: The number of double and multiple lesions shown on coronary angiogram were significantly higher than those shown in echocardiography. Phosphocreatine kinase (CK), creatine kinase isoenzyme (CK-MB) and cardiac troponin T (cTnT) improved significantly in both groups after surgery, with CK-MB significantly lower in EG than those in CG at 1 and 3 days post-operation. Interleukin-6 (IL-6) was significantly lower in EG than in CG at 1 and 7 days after the surgery ($p < 0.05$). N-terminal B-type natriuretic peptide (NT-proBNP) was lower in EG than in CG on the 3rd day after surgery ($p < 0.05$). Superoxide dismutase (SOD) was significantly higher in EG than in the CG at 1, 3 and 7 days after surgery. The QRS scores significantly improved in both groups after surgery ($p < 0.05$).

Conclusion: Echocardiography, when used in combination with coronary angiogram, accurately assesses the coronary lesions in acute myocardial infarction, and atorvastatin treatment after PCI reduces myocardial injury, relieves inflammation, and promotes the recovery of cardiac function in patients.

Keywords: Acute myocardial infarction, Coronary coronary angiogram, Echocardiography, Atorvastatin

This is an Open Access article that uses a funding model which does not charge readers or their institutions for access and distributed under the terms of the Creative Commons Attribution License (<http://creativecommons.org/licenses/by/4.0>) and the Budapest Open Access Initiative (<http://www.budapestopenaccessinitiative.org/read>), which permit unrestricted use, distribution, and reproduction in any medium, provided the original work is properly credited.

Tropical Journal of Pharmaceutical Research is indexed by Science Citation Index (SciSearch), Scopus, International Pharmaceutical Abstract, Chemical Abstracts, Embase, Index Copernicus, EBSCO, African Index Medicus, JournalSeek, Journal Citation Reports/Science Edition, Directory of Open Access Journals (DOAJ), African Journal Online, Bioline International, Open-J-Gate and Pharmacy Abstracts

INTRODUCTION

Acute myocardial infarction is mainly caused by unstable coronary atherosclerotic plaque, which results in the obstruction of coronary blood flow and necrosis of myocardial tissue due to ischemia and hypoxia, leading to a series of clinical symptoms and even death of the patient [1]. Early diagnosis of acute myocardial infarction is crucial for treatment, and coronary angiogram is the gold standard for the diagnosis of acute myocardial infarction, and its diagnostic results tend to be similar to those obtained after surgery. Some patients however are intolerant of coronary angiogram [2]. Echocardiography can accurately assess myocardial injury and the ejection capacity of the heart, is simple to perform, non-invasive, and has a high frequency of application in clinical practice [3]. Percutaneous coronary intervention (PCI) is the primary treatment for acute myocardial infarction. There is however still a high risk of lethality during postoperative recovery. Atorvastatin has lipid-modulating effects [4], and oral atorvastatin has been reported to be effective in stabilizing atheromatous plaques, improving vascular endothelial function, inhibiting organismal inflammation, and reducing the risk of re-admission [5].

Current studies on atorvastatin have focused on oxidative stress and inflammatory response, and relatively few studies have been conducted on myocardial injury and cardiac function [6]. In this study, patients with acute myocardial infarction were enrolled as the study subjects, and the therapeutic effect of atorvastatin was evaluated using echocardiography in combination with coronary angiogram.

METHODS

Baseline data

One hundred patients with acute myocardial infarction who were admitted to Affiliated Hospital of Jinggangshan University, Ji'an, China from August 2019 to August 2021, were enrolled and divided into two groups based on random number table. Fifty cases in the control group (CG) were treated with conventional treatment, while 50 cases in study group (EG) were treated with atorvastatin.

The age range of patients in the CG was 49 - 76 years old, with a mean age of (64.45 ± 3.53) years), including 32 males and 18 females, 32 cases of hypertension, 20 cases of type 2 diabetes, 11 cases of hyperlipidemia with an onset time of 1 - 17 h and mean onset time of

(7.54 ± 1.92) h. The EG h patients were aged 52 - 75 years old, had a mean age of (65.34 ± 5.98) , including 33 males and 17 females, 33 cases of hypertension, 22 cases of type 2 diabetes, 10 cases of hyperlipidemia with an onset time of 1 - 19 h and mean onset time (7.64 ± 1.54) h). There was no difference between the two groups ($p > 0.05$), and the data could be compared. This study was approved by the Ethics Committee of the Affiliated Hospital of Jinggangshan University (no. 18-JGS-0051), and was conducted according to guidelines of the Declaration of Helsinki [7]. Signed written informed consent was obtained from all participants prior to commencement of the study.

Inclusion criteria

(1) Patients who met the diagnostic criteria of acute myocardial infarction through clinical diagnosis [8]; (2) aged between 50 - 80 years; (3) patients signed and agreed to participate in this study; (4) patients were required to undergo PCI procedure; (5) patients who could tolerate iodography.

Exclusion criteria

(1) Large myocardial infarction or combined with cardiogenic shock; (2) associated with severe infectious disease or malignancy; (3) associated with liver and kidney insufficiency; (4) intolerance to the study medication; (5) previous history of myocardial infarction; (6) presence of mental disorders or communication disorders; (7) associated with inflammatory or hematologic diseases.

Treatments and diagnostic examination

The CG received conventional thrombolytic therapy: before thrombolytic therapy, patients were orally given clopidogrel (H20123115, Lep Pharmaceutical Co. Ltd, lot No. 20190712, 300 mg) and aspirin (J20130078, Bayer Healthcare Ltd, lot No. 20200214, 300 mg). After completing thrombolytic therapy 150 mg of aspirin and 75 mg of clopidogrel were given orally daily, once a day, and after discharge, small doses of aspirin were given orally (75 - 100 mg daily), while patients were also given conventional nitrate preparations, β -blockers and angiotensin inhibition therapy.

The EG was treated with atorvastatin on the basis of the CG: The conventional treatment regimen was the same as those of the CG. Besides, patients were given q.d. 20 mg atorvastatin (J20130172, Sandoz Pharmaceutical Co. Ltd, Lot no. 20291204).

Echocardiographic examination was performed before and after the intervention in both groups respectively, with the patient in the left lateral recumbent position. The patient was diagnosed with a color Doppler ultrasound diagnostic instrument (Jinan Hao Lai Bao Medical Equipment Co. Ltd, Dawei DW-T6), with probe S5-1, frequency 2.0 - 15 HZ, to make a comprehensive observation of the ventricular wall motion. The patient's left ventricular long-axis section A sweep of the ventricular long-axis view was performed to obtain the maximum end-diastolic internal diameter and end-systolic internal diameter of the left ventricle. Thereafter, a sweep of the patient's apical four-chamber view was performed to obtain other relevant parameters such as left ventricular ejection fraction [9].

The coronary angiogram examination was performed with a digital subtraction angiography machine (Philips, Allura Xper FD10) in the conventional position. The catheter was extended from the lateral femoral artery into the aortic sinus, and a pantethine contrast agent was used to perform coronary angiography and to observe the condition of stenosis of the lesion. An electrocardiographic monitor was connected during the examination to record the changes in the patient's electrocardiogram. Three or more consecutive imaging figures in different positions were taken for observation [10].

Analysis of patients' echocardiography and coronary angiography

The number of coronary lesions detected by echocardiography and coronary angiography were recorded. Patients with three and more lesions were grouped into a multiple lesion group. The imaging diagnostic results were compared with patients' PCI procedure results.

Analysis of patients' CK, CK-MB and cTnT

The blood plasma (5 ml) was collected and then centrifuged at 3600 rpm for 14 min. The levels of phosphocreatine kinase (CK), creatine kinase isoenzyme (CK-MB) and cardiac troponin T (cTnT) were determined by enzyme-linked immunosorbent assay, which was performed in strict compliance with kit manufacturer's instructions.

Determination of endothelin, NT-proBNP, and IL-6 assay

Serum samples were taken and assayed for endothelin. N-terminal B-type natriuretic peptide (NT-proBNP), and interleukin-6 (IL-6)

by enzyme-linked immunosorbent assay, following the kit manufacturer's instructions.

Patients' oxidative stress indicators SOD and NO

The prepared serum samples were taken for human superoxide dismutase (SOD) detection by double-antibody sandwich enzyme-linked immunosorbent assay (ELISA) and nitric oxide (NO) by fluorescence immunoassay, following the kit manufacturer's instructions.

LVEDD, LVESD, LVEDV, LVESV, LVEF analyses

The patient's left ventricular ejection fraction (LVEF), left ventricular end-diastolic internal diameter (LVEDD), left ventricular end-systolic internal diameter (LVESD), left ventricular end-diastolic volume (LVEDV), left ventricular end-systolic volume (LVESV) were determined using ultrasound cardiogram.

QRS scores analysis

Twelve-lead ECG examination was performed, and the myocardial infarction area was evaluated using the Selvester QRS wave scores with 54 items scoring 32 in total.

Statistical analysis

Data analysis was performed using SPSS statistical analysis software (version 26.0). If the data conformed to normal distribution, count data were expressed as %, while chi-square test was used for the analysis of intergroup variability. Measurement data were expressed as mean \pm standard deviation (SD). $P < 0.05$ was considered statistically significant.

RESULTS

Echocardiographic and coronary angiographic results

The double-branch lesions and multi-branch lesions on the coronary angiogram were significantly higher than those on the echocardiography ($p < 0.05$), but the degree of coronary lesions in the EG was not significantly different from that in the CG ($p > 0.05$, Table 1).

CK, CK-MB and cTnT

Post-operation, CK, CK-MB and cTnT were significantly improved in both groups. CK-MB was significantly lower in the EG than in the CG at 1 and 3 days postoperatively ($p < 0.05$), while

nTnT was significantly lower in the EG than in the CG at 3 d postoperatively ($p < 0.05$), (Table 2).

Endothelin, NT-proBNP and IL-6

Post-operation, endothelin and IL-6 were significantly improved in both groups ($p < 0.05$), and IL-6 was significantly lower in the EG than that in CG at 1 d and 7 d postoperatively ($p < 0.05$), and NT-proBNP was lower in the EG than those in CG at 3 d postoperatively ($p < 0.05$, Table 3).

NO and SOD

NO and SOD improved significantly in both groups post-operation, and SOD was significantly higher in the EG than in the CG at 1, 3 and 7 days postoperatively ($p < 0.05$), (Figure 1).

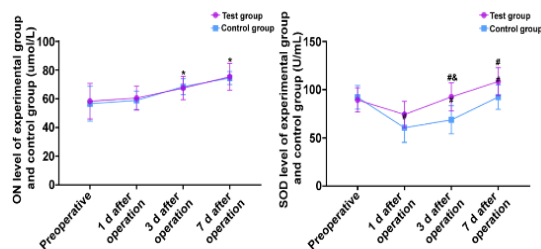


Figure 1: Comparison of ON and SOD levels in patients (Note: compared with experimental group before PCI, * $p < 0.05$; compared with the control group before PCI, # $p < 0.05$; compared with control group after PCI, & $p < 0.05$)

Patients' LVEDD, LVESD, LVEDV, LVESV, LVEF

LVEDD, LVESD, LVEDV, LVESV, LVEF improved significantly in both groups ($p < 0.05$), and there was no significant difference in the levels of LVEDD, LVESD, LVEDV, LVESV, LVEF between the EG and the CG after surgery ($p > 0.05$), (Figure 2 and Figure 3).

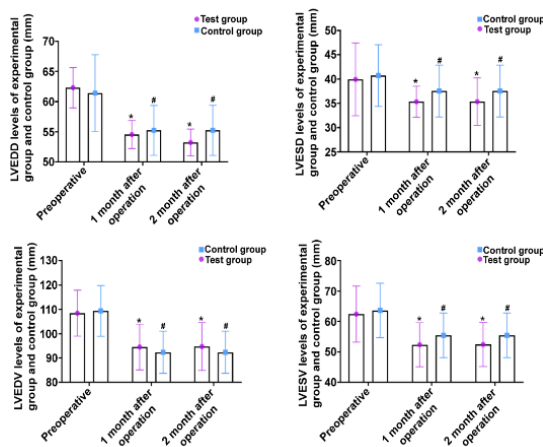


Figure 2: Comparison of LVEDD, LVESD, LVEDV, and LVESV in patients (Note: compared with experimental group before PCI, * $p < 0.005$. Compared with control group before PCI, # $p < 0.05$; compared with control group after PCI, & $p < 0.05$)

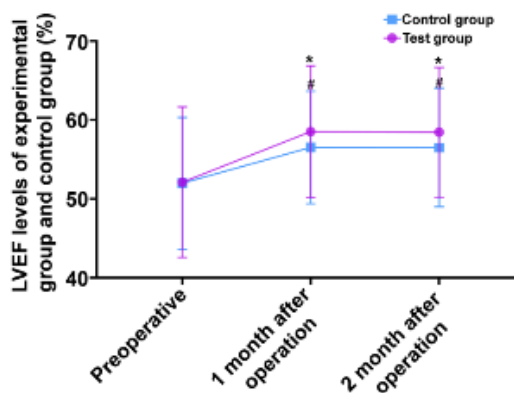


Figure 3: Comparison of patients' LVEF (Note: compared with compared with experimental group before PCI, * $p < 0.05$; compared with control group before PCI, # $p < 0.05$; compared with control group after PCI, & $p < 0.05$)

Table 1: Echocardiographic and coronary angiographic findings (cases, %)

Group	Parameter	Single branch lesion	Double-branch lesions	Multi-branch lesions
Study	Echocardiography	23	18	9
	coronary angiogram	12	27	11
	Joint testing	11	27	12
	Surgical outcomes	11	27	12
Control	Echocardiography	24	17	9
	coronary angiogram	14	26	10
	Joint testing	11	26	13
	Surgery outcomes	12	27	11

Table 2: Comparison of CK, CK-MB, and cTnT in patients (mean \pm SD)

Group	Parameter	Preoperative	Day 1 postoperative	Day 7 postoperative	Day 7 postoperative
Study	CK (U/L)	878.56 \pm 35.54	329.65 \pm 45.68*	198.65 \pm 34.25*	101.54 \pm 26.32*
	CK-MB (U/L)	124.35 \pm 26.65	20.15 \pm 8.32*&	14.45 \pm 3.88*&	8.51 \pm 2.12*
	cTnT (ng/ml)	3.52 \pm 1.25	2.91 \pm 1.42	2.11 \pm 0.98*&	0.73 \pm 0.25*
Control	CK (U/L)	862.19 \pm 45.69	425.98 \pm 43.21#	221.36 \pm 24.25#	153.62 \pm 25.21#
	CK-MB (U/L)	123.65 \pm 12.98	28.62 \pm 2.78#	20.82 \pm 6.35#	11.71 \pm 2.74#
	cTnT (ng/ml)	3.65 \pm 1.98	3.05 \pm 1.78	2.81 \pm 1.24#	0.91 \pm 0.27#

Note: Compared with experimental group before PCI, * $p < 0.05$; compared with control group before PCI, # $p < 0.05$; compared with control group after PCI, & $p < 0.05$

Table 3: Comparison of patients' endothelin, NT-proBNP, and IL-6 (mean \pm SD)

Group	Parameter	Preoperative	Day 1 postoperative	Day 3 postoperative	Day 7 postoperative
Study	Endothelin (ng/L)	107.35 \pm 10.43	157.82 \pm 21.14*	90.54 \pm 23.52	88.56 \pm 11.24*
	IL-6 (pg/ml)	19.64 \pm 3.65	22.64 \pm 4.69&	17.43 \pm 4.38	10.24 \pm 3.74&*
	NT-proBNP (ng/ml)	1169.71 \pm 124.42	987.34 \pm 103.23*	448.23 \pm 98.24*&	202.43 \pm 78.44*
Control	Endothelin (ng/L)	109.43 \pm 8.92	158.83 \pm 14.25#	91.02 \pm 15.32	89.83 \pm 12.43#
	IL-6 (pg/ml)	19.19 \pm 5.63	30.24 \pm 6.37#	22.84 \pm 5.37	5.87 \pm 1.41
	NT-proBNP (ng/ml)	1130.42 \pm 142.44	987.34 \pm 92.44#	684.23 \pm 48.98#	230.42 \pm 25.34#

Note: Compared with the study group before PCI, * $p < 0.05$; compared with the control group before PCI, # $p < 0.05$; compared with control group after PCI, & $p < 0.05$

QRS scores of patients

The QRS scores of both groups improved significantly ($p < 0.05$), and the QRS scores of the EG were significantly lower in EG than those of the CG at 1 month, 2 months and 6 months after surgery ($p > 0.05$, Figure 4).

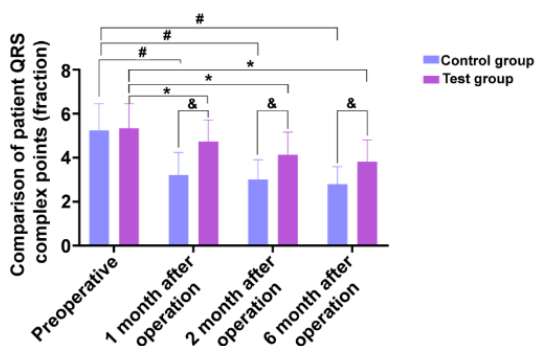


Figure 4: Comparison of QRS wave scores (Note: compared with experimental group before PCI, * $p < 0.05$; compared with control group before PCI, # $p < 0.05$; compared with the control group after PCI, & $p < 0.05$)

DISCUSSION

Percutaneous coronary intervention (PCI) is a clinical treatment option for acute myocardial infarction, which aims to restore coronary blood supply and ensure myocardial blood circulation through interventional operations [11,12]. Atorvastatin is a commonly used drug after PCI, which improves the patient's condition and avoids readmission by regulating oxidative stress as well as controlling the development of inflammation [13]. It has been found that the progression of acute myocardial infarction is influenced by lipid levels [14]. The current studies fully confirm that atorvastatin inhibits vascular obstruction and improves arterial plaque stability through lipid modulation [15,16]. However, few studies have been conducted on the effects of atorvastatin in improving cardiac function and on cardiomyocytes [17]. In this study, echocardiography combined with coronary angiogram was performed on patients with acute myocardial infarction and admitted to the hospital to determine the vascular lesions of the patients before the procedure, and atorvastatin was administered to the patients after PCI to observe the therapeutic effect.

Patients with acute myocardial infarction and treated with PCI may be subjected to balloon compression during PCI that may cause re-injury

to the vascular endothelium, thereby promoting the inflammatory response [18,19].

Postoperative plaque compression may also lead to the occurrence of microvascular occlusion, promoting myocardial cell necrosis at the site of the lesion [20]. CK, CK-MB, and cTnT, as characteristic indicators of myocardial injury, have a high sensitivity and specificity [21]. In this study, results showed that the changes in CK, CK-MB and cTnT levels in the two groups of patients, and the results showed that CK, CK-MB and cTnT decreased significantly in both groups after surgery, and CK-MB was significantly lower in the EG than in the CG at 1 d and 3 d after surgery, and nTnT was significantly lower in the EG than in the CG at 3 d after surgery, suggesting that postoperative atorvastatin treatment after surgery can effectively promote recovery from myocardial injury. It has been reported that the inflammatory response plays a key role in the pathogenesis and progression of acute myocardial infarction, and treatment with atorvastatin can effectively alleviate the compliance of diseased vascular endothelial cells, adjust the lipid levels, and promote the recovery of myocardial function [22]. In this study, the level of inflammatory indexes was also analyzed, and the results showed that endothelin and IL-6 were significantly decreased in both groups after surgery, and IL-6 was significantly lower in the EG than that in the CG at 1 d and 7 d after surgery ($p < 0.05$), suggesting that atorvastatin treatment can effectively control the inflammation in patients after PCI and promote their recovery.

Nitric oxide (NO) is an important vasodilator factor for the production of vascular endothelial cells, and it has been found in a study that vasodilatory dysfunction is disrupted when the level of ON is decreased, which causes endothelial cell injury [23]. SOD is a common clinical index for the evaluation of oxidative stress [24,25]. In this study, ON and SOD improved significantly in both groups after surgery, and SOD was significantly higher in the EG than in the CG at days 1, 3 and 7 after surgery, suggesting that atorvastatin treatment can improve the oxidative stress response and alleviate stress injury.

In the present study, LVEDD, LVESD, LVEDV, LVESV significantly reduced and LVEF significantly increased in the two groups after surgery, but the postoperative levels of the indices in the two groups did not differ significantly, suggesting that PCI can effectively restore patients' cardiac function. However, the effect of postoperative atorvastatin treatment on

the improvement of cardiac function was not significant.

CONCLUSION

Echocardiography combined with coronary angiogram more accurately assesses coronary lesions in acute myocardial infarction. Furthermore, atorvastatin treatment after PCI reduces myocardial injury, relieves inflammation, and promotes the recovery of cardiac function in patients.

DECLARATIONS

Conflict of Interest

No conflict of interest associated with this work.

Contribution of Authors

We declare that this work was done by the authors named in this article and all liabilities pertaining to claims relating to the content of this article will be borne by the authors. Lijuan Liao and Chun Xiong designed the study and performed the experiments, Lijuan Liao and Wenwu Huang collected the data, Chun Xiong and Wenwu Huang analyzed the data, Lijuan Liao and Chun Xiong prepared the manuscript. All authors read and approved the final manuscript.

Open Access

This is an Open Access article that uses a funding model which does not charge readers or their institutions for access and distributed under the terms of the Creative Commons Attribution License (<http://creativecommons.org/licenses/by/4.0>) and the Budapest Open Access Initiative (<http://www.budapestopenaccessinitiative.org/read>), which permit unrestricted use, distribution, and reproduction in any medium, provided the original work is properly credited.

REFERENCES

- Gulati R, Behfar A, Narula J, Kanwar A, Lerman A, Cooper L, Singh M. Acute myocardial infarction in young individuals. *Mayo Clin Proc* 2020; 95(1): 136-156.
- Jiang H, Liu L, Sui H, Liang B, Jin L. Efficacy and safety of combination of ulinastatin and meglumine cyclic adenosine monophosphate in the treatment of acute myocardial infarction, and its effect on serum levels of hs-CRP, cTnI and CK. *Trop J Pharm Res* 2022; 21(2):359-365
- Kapur NK, Thayer KL, Zweck E. Cardiogenic shock in the setting of acute myocardial infarction. *Methodist Debaquey Cardiovasc J* 2020; 16(1): 16-21.
- Abdelaziz TA, Mohamed RH, Balata GF, El-Azzazy OY. Effect of angiotensin converting enzyme gene polymorphism on patients with in-stent restenosis after percutaneous coronary intervention. *Trop J Pharm Res* 2021; 20(2):403-409
- DeFilippis AP, Chapman AR, Mills NL, de Lemos JA, Arbab-Zadeh A, Newby LK, Morrow DA. Assessment and treatment of patients with type 2 myocardial infarction and acute nonischemic myocardial injury. *Circulation* 2019; 140(20): 1661-1678.
- Barnett R. Acute myocardial infarction. *Lancet* 2019; 393(10191): 2580.
- Stockhausen K. The Declaration of Helsinki: revising ethical research guidelines for the 21st century. *Med J Aust* 2000; 172(6): 252-253.
- Thiele H, Zahn R. Acute myocardial infarction-actual issues. *Herz* 2020; 45(6): 507-508.
- Edupuganti MM, Ganga V. Acute myocardial infarction in pregnancy: Current diagnosis and management approaches. *Indian Heart J* 2019; 71(5): 367-374.
- Kim Y, Ahn Y, Cho MC, Kim CJ, Kim YJ, Jeong MH. Current status of acute myocardial infarction in Korea. *Korean J Intern Med* 2019; 34(1): 1-10.
- Zeymer U, Bueno H, Granger CB, Hochman J, Huber K, Lettino M, Price S, Schiele F, Tubaro M, Vranckx P, et al. Acute Cardiovascular Care Association position statement for the diagnosis and treatment of patients with acute myocardial infarction complicated by cardiogenic shock: A document of the Acute Cardiovascular Care Association of the European Society of Cardiology. *Eur Heart J Acute Cardiovasc Care* 2020; 9(2): 183-197.
- Capaccione KM, Leb JS, D'Souza B, Utukuri P, Salvatore MM. Acute myocardial infarction secondary to COVID-19 infection: A case report and review of the literature. *Clin Imaging* 2021; 72: 178-182.
- Berezin AE, Berezin AA. Adverse Cardiac Remodelling after acute myocardial infarction: old and new biomarkers. *Dis Markers* 2020; 2020: 1215802.
- Dzibur A, Gacic E, Mekic M. Comparison of Patients with Acute Myocardial Infarction According to Age. *Med Arch* 2019; 73(1): 23-27.
- Khodayari S, Khodayari H, Amiri AZ, Eslami M, Farhud D, Hescheler J, Nayernia K. Inflammatory Microenvironment of Acute Myocardial Infarction Prevents Regeneration of Heart with Stem Cells Therapy. *Cell Physiol Biochem* 2019; 53(5): 887-909.
- Goedemans L, Bax JJ, Delgado V. COPD and acute myocardial infarction. *Eur Respir Rev* 2020; 29(156).
- Sandoval Y, Jaffe AS. Type 2 Myocardial Infarction: JACC Review Topic of the Week. *J Am Coll Cardiol* 2019; 73(14): 1846-1860.
- Smit M, Coetzee AR, Lochner A. The Pathophysiology of Myocardial Ischemia and Perioperative Myocardial

- Infarction. J Cardiothorac Vasc Anesth* 2020; 34(9): 2501-2512.
19. Hudec S, Hutyra M, Precek J, Latal J, Nykl R, Spacek M, Sluka M, Sanak D, Tudos Z, Navratil K, et al. Acute myocardial infarction, intraventricular thrombus and risk of systemic embolism. *Biomed Pap Med Fac Univ Palacky Olomouc Czech Repub* 2020; 164(1): 34-42.
20. Akodad M, Sicard P, Fauconnier J, Roubille F. Colchicine and myocardial infarction: A review. *Arch Cardiovasc Dis* 2020; 113(10): 652-659.