

Original Research Article

Assessment of wound contraction, re-epithelialization and histological changes in full thickness excision wounds of rats treated with different concentrations of hydrogen peroxide

Sunday O Udegbumam, Sunday Ogbobe, Nnamdi H Okereke*, Adaobi S Enejere, Ijeoma R Udegbumam, Toochukwu H Ezeobialu

Department of Veterinary Surgery, Faculty of Veterinary Medicine, University of Nigeria, Nsukka, Nigeria

*For correspondence: **Email:** nnamdi.okereke@unn.edu.ng; **Tel:** +234-80(3)-480-6730

Sent for review: 22 October 2020

Revised accepted: 21 July 2021

Abstract

Purpose: To investigate the impact of treatment with different strengths of hydrogen peroxide (H_2O_2) on healing of excision-type wounds in rats.

Methods: Thirty-two ($n = 8$) adult wistar rats randomly assigned to four groups A - D were used for the study. Full-thickness excision-type wound was surgically made on each rat on day 0. While wounds in group A, the control, were treated with 0.9 % normal saline, wounds in groups B - D received 1, 3, and 5 % H_2O_2 , respectively. Following the surgical wounding and treatment, the epithelialization time, wound contraction, and histological changes of the wounds were assessed.

Results: On day 21, animals in group C recorded 100% wound contraction, whereas in groups A, B and D the contraction degrees of 68.75, 79.33 and 79.00 %, respectively, were reported on the same day. Group C animals treated with 3 % of H_2O_2 had significantly ($p < 0.05$) higher degree of wound contraction and epithelialization. Histologically, by day 14, wounds of animals in group C presented with a preponderance of fibrocytes over fibroblasts spread across organized connective tissue fibres. Group C treated animals also had significantly ($p < 0.05$) faster epithelialization. No visible side effects were observed in this group following the treatments. However, the wounds of animals in groups A, B and D showed fibroblasts embedded in loose irregular connective tissue fibres with haemorrhagic lesions, alongside pronounced polymorphonuclear cell infiltration.

Conclusion: When compared to other concentrations used in the study, the optimum strength of H_2O_2 for wound dressing is 3 % in terms of rate of wound contraction, epithelialization time, histological changes and physical tissue damage.

Keywords: Excision wound, Hydrogen peroxide, Fibrocytes

This is an Open Access article that uses a funding model which does not charge readers or their institutions for access and distributed under the terms of the Creative Commons Attribution License (<http://creativecommons.org/licenses/by/4.0>) and the Budapest Open Access Initiative (<http://www.budapestopenaccessinitiative.org/read>), which permit unrestricted use, distribution, and reproduction in any medium, provided the original work is properly credited.

Tropical Journal of Pharmaceutical Research is indexed by Science Citation Index (SciSearch), Scopus, International Pharmaceutical Abstract, Chemical Abstracts, Embase, Index Copernicus, EBSCO, African Index Medicus, JournalSeek, Journal Citation Reports/Science Edition, Directory of Open Access Journals (DOAJ), African Journal Online, Bioline International, Open-J-Gate and Pharmacy Abstracts

INTRODUCTION

A wound is a disruption in the normal continuity of tissues and metabolic function of body structures [1]. Wounds may be produced

unintentionally by physical, thermal, microbial or immunological insults, or intentionally by surgical incision or excision. Wound healing is the repair of the disrupted anatomical stability and functional status of damaged tissues [2]. The

process of wound healing begins with wound cleansing [3]. This has been made possible clinically by employing various methods and agents that promote healing [3]. Antiseptics have been a popular wound cleansing agent since the nineteenth century. The commonly used antiseptics include povidone iodine, chlorhexidine, methylated spirit, chlorine compounds, silver compounds and hydrogen peroxide [4].

Among all the kinds of antiseptics prepared for commercial use, hydrogen peroxide is the most widely used. It kills pathogens through oxidative burst and local oxygen production [4]. Based on reports from clinical trials, the positive effects of 1% hydrogen peroxide include acceleration of re-epithelialization of wounds in rats [6] and excellent antibacterial effect against *Staphylococcus aureus* [7]. In addition, a cream containing 1.5-3 % hydrogen peroxide was reported to increase circulation in ischemic ulcers and surrounding skin in a guinea pig model [7]. In a Zebra fish model of wound healing, application of hydrogen peroxide helps to attract neutrophils in the wound site [6], and promotes re-innervation of the peripheral sensory axion [8]. Some workers have demonstrated that application of honey enhances the healing of chronic wounds [9]; this ability is attributed to the presence, in honey, of hydrogen peroxide generated by the degradation of glucose to gluconic acid and hydrogen peroxide through the activities of glucose oxidase [10].

Despite the beneficial effects of higher dilutions of hydrogen peroxide in the wound healing process, lower dilutions of the agent can cause tissue irritation, allergic reactions as well as blistering, redness and other skin pathologies [6]. Circumstantial evidences observed by the researchers suggest that the use of commercially available hydrogen peroxide (6% concentration) on open wounds without dilution causes severe charring of tissues. Furthermore, it has been noted that the preponderance of reactive oxygen species (ROS) - including hydrogen peroxide, hydroxyl radicals and superoxide anions- in wounds is important in the pathology of chronic wounds [11]. These ROS, cross-link with tissue nucleic acids, proteins and lipids resulting in loss of tissue structure and function [12].

In addition, the use of hydrogen peroxide as an antiseptic remains a widely disputed topic among professionals [3]. Sleigh *et al* [13] concluded that since hydrogen peroxide is harmful to newly-formed cells, it should be avoided in all wound cleaning works. Other workers further buttressed this view by observing that wound treatment with

hydrogen peroxide hinders cells from getting to the wounded area [14]. In view of the above reports, the benefits and demerits of low and high concentrations of hydrogen peroxide on wound healing need to be further investigated. The basic objective of this study was to determine the appropriate concentration of hydrogen peroxide which when used on open wounds would facilitate tissue proliferation and enhance wound healing.

EXPERIMENTAL

Ethics

This work was executed with ethical considerations guided by the National Institute of Health (NIH) revised guidelines for laboratory animals' use and care [15]. The protocols employed for the current study were subjected to the review, and obtained the endorsement of the Institutional Animal Care and Use Committee of the Faculty of Veterinary Medicine, University of Nigeria, Nsukka (approval ref no. FVM-UNN-IACUC-2019-1355).

Animals

Adult Wistar rats (n=32) which weighed between 170-184 g were used for this study. They were offered proprietary laboratory animal feed alongside potable water *ad libitum*. A two-week period of acclimatization was allowed for the experimental animals while they were being housed in fly proof cages at the laboratory animal house of Department of Veterinary Surgery, University of Nigeria.

Wound healing studies

Thirty-two rats were anaesthetized by intramuscularly injecting 10 mgkg⁻¹ body weight of xylazine hydrochloride (Xylazine 20®, Kepro Holland) and 50 mgkg⁻¹ body weight of ketamine hydrochloride (Mark pharmaceuticals® Nigeria). The dorsal aspects of the rats were shaved after scrubbing with 0.5% chlorhexidine. Full thickness circular excision wound of 2cm in diameter was created on the scrubbed area of each rat. The animals were left untreated for 24 hours to allow for bacterial contamination of the wounds. Post-wounding, the rats were assigned to four groups A-D (n = 8) in a random fashion. Wounds in group A were dressed with normal saline, while those in groups B - D were respectively treated with 1%, 3% and 5 % hydrogen peroxide. The experimental animals were housed in clean and dust free individual cages in order to prevent cannibalism or wound licking. Subsequently, on a daily basis, the rats were treated with the

specified hydrogen peroxide concentrations until the wounds healed completely.

Determination of wound contraction of excision wound

Determination of wound contraction across the groups was done as previously reported in Chah *et al* [16]. Briefly, on days 1, 4, 7, 14 and 21 following the creation of the wounds, the wound diameters were traced by means of a transparent tracing paper [16]. This was done by placing the paper on the wound and making an outline around the wound with a colored marker. The date, group name and rat identity were noted on each tracing paper after measurements. Next, the areas of the measured wounds were determined by laying the transparent tracing paper over a 1mm² graph paper and counting the square within the circumference. The difference between the area measured on particular day and the area determined on the previous day, gave the wound contraction measurement, which was further expressed as a percentage. Following dressing of wounds across the groups each day, the wound sites were observed for signs of physical damages of iatrogenic origin. Two clinicians conducted this observation and independently reported their findings. Computation of wound contraction (C) is as shown in Eq 1.

$$C (\%) = \{(W_0 - W_1) / W_0\} 100 \dots\dots\dots (1)$$

where W₀ = wound area at initial tracing day, and W₁ = wound area at each tracing or subsequent days.

Assessment of wound epithelialization time

The time required for wound epithelialization was estimated by monitoring the number of days that elapsed before scar tissues self-detached from the wound site without leaving any open wound [17]. The mean time (in days) for wound epithelialization for each group was then calculated.

Histological studies

Two rats each from the various groups were euthanized on day 14 of the study and wound tissue biopsies were harvested and preserved in 10% formal saline. For tissue processing, the samples were dehydrated in increasing concentrations of ethyl alcohol (70 - 100%); the tissues, thereafter, were treated with xylene which served as a clearing solution. This was followed by embedding of the tissues in paraffin wax. The processed tissues were cut into thin

sections each having a thickness of about five millimeters. Staining of the thin sections was done using haematoxylin and eosin to enable histological evaluations. Histological examinations for re-epithelialization, presence of polymorphonuclear leucocytes (PMNLS), tissue macrophages (TM), fibroblasts, neovascularization and new collagen formation were done.

Statistical analysis

The data on the percentage wound contraction and mean time for wound epithelialization were analyzed with the one-way analysis of variance (ANOVA) statistic. Variations in means across the groups were separated using the Duncan multiple range test (DNMRT). Probability values (*p* values) below 0.05 were deemed significant statistically.

RESULTS

Wound contraction

Treatment with the specified concentrations of H₂O₂ resulted in increase in the wound contraction percentage in rats of groups B and C by day 4. No significant difference was observed in wound contraction in the other two groups. By day 7, progressive decrease in wound size was observed in all the groups with group C animals having the topmost wound contraction percentage which was followed by group B and then group A, while rats in group D recorded the smallest wound contraction percentage. By day 7, post-surgery, group C animals had a significantly (*p* < 0.05) higher degree of wound contraction (21.50 %) than those in groups A (8.40 %), B (9.33 %) and D (5.00 %). By day 21, 100 % wound contraction was recorded in group C animals, while groups A, B, and D had 68.75, 79.33 and 79.00 % wound contraction, respectively. The rate of wound contraction of group C animals remained significantly (*p* < 0.05) higher when compared to those of all the other experimental groups. On the other hand, group A animals which were treated with normal saline, showed the least degree of wound contraction on the same day (Table 1), statistically significant though it was.

Wound epithelialization

In this study, group C animals treated with 3 % of H₂O₂ had higher degree of wound epithelialization, followed by animals in groups A, B, and D. Wound epithelialization occurred on days 45, 28, 19 and 32 in animals in groups A, B, C and D respectively (Table 2).

Table 1: Wound contraction in rats post-excision

Day	Group			
	A(0.9% normal saline)	B (1% H ₂ O ₂)	C (3% H ₂ O ₂)	D (5% H ₂ O ₂)
1	-6.86±1.32 ^{ab}	-5.25±1.93 ^{ab}	-4.13±0.79 ^a	-7.63±1.35 ^b
4	-3.00±0.79 ^b	1.75±3.22 ^{ab}	5.13±1.14 ^a	-2.13±0.64 ^b
7	8.40±1.81 ^b	9.33±4.85 ^b	21.50±4.19 ^a	5.00±1.21 ^b
14	48.00±6.55 ^b	57.67±0.67 ^b	71.50±3.23 ^a	55.75±2.25 ^b
21	68.75±4.59 ^c	79.33±2.6 ^b	100.00±0.00 ^a	79.00±2.35 ^a

Different superscripts in a column indicate significant differences between means (*p* < 0.05)

Table 2: Wound epithelialization time of rats, post-wounding

Group	A (n/saline)	B (1%)	C (3%)	D (5%)
Day of wound epithelialization	44.75±3.20 ^b	28.60±0.29 ^{ab}	19.00±0.71 ^a	32.00±2.04 ^b

Different superscripts in a row indicate significant difference between mean at *p* < 0.05

Histological findings

By day 14, there were more fibrocytes than fibroblasts with organized fibrous connective tissues in group C animals treated with 3% concentration of hydrogen peroxide as seen in Figure 1 A. In group B treated with 15 hydrogen peroxide and group D treated with 5% hydrogen peroxide there were more fibroblasts and less fibrocytes. In addition, there were loose and irregular fibrous connective tissues and marked infiltration of polymorphonuclear leukocytes in the two groups as seen in Figure 1 B and D. In normal saline-treated group (group A), there were poor fibroblastic activity, more hemorrhagic lesions and moderate polymorphonuclear leukocytes (PMNLS).

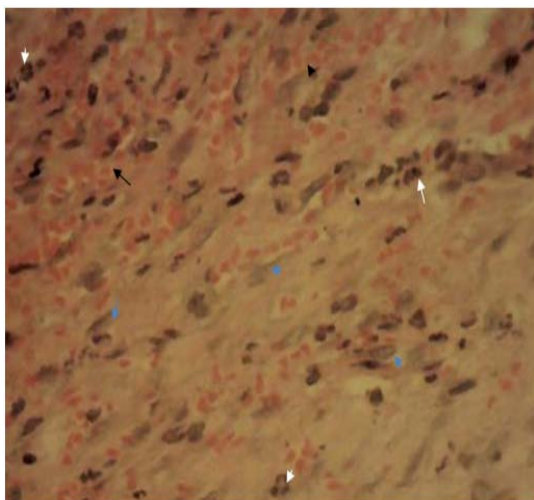


Figure 1: Photomicrograph of the skin biopsy with observed changes in the control group showing marked haemorrhage (black arrow), moderate infiltration of polymorphonuclear leukocytes (white arrow), and moderate collagen deposition with few fibroblasts (blue arrow). H & E, x400

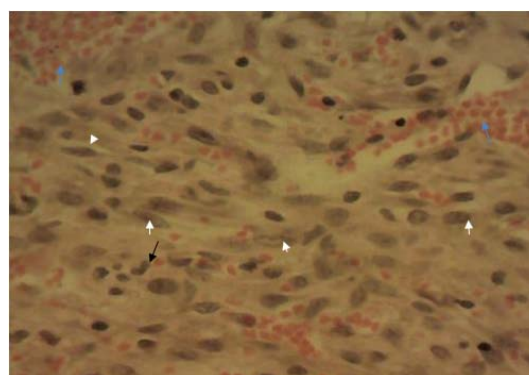


Figure 2: Photomicrograph of the skin biopsy with observed changes in group B, showing marked proliferation of fibroblasts (white arrow), fewer polymorphonuclear leukocytes (black arrow) macrophages and engorged blood vessels (blue arrow). H & E, x400

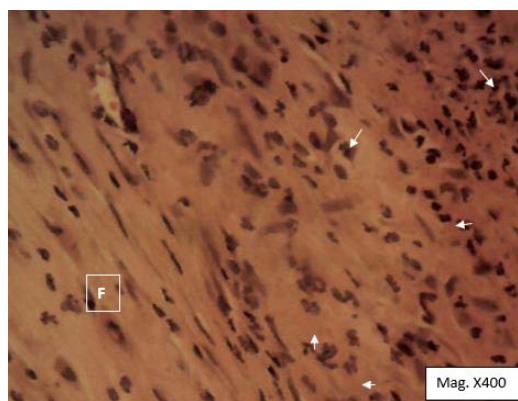


Figure 3: Photomicrograph of the skin biopsy with observed changes in group C showing intense fibroblastic activity/fibrosis (F), complete fibrosis of the affected area, presence of polymorphonuclear leukocytes (white arrow), few neutrophils on the surface of the wound and few macrophages were also observed in the granulation tissue and dermis H & E, x400

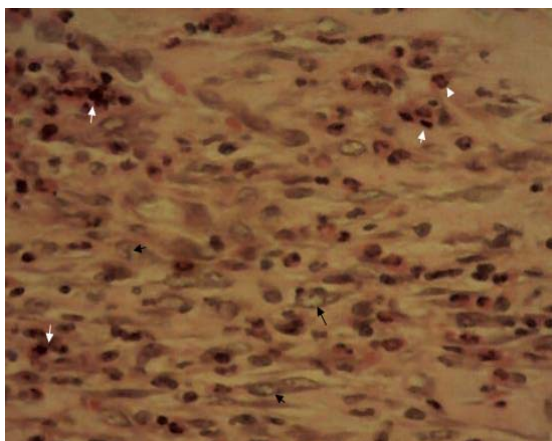


Figure 4: Photomicrograph of the skin biopsy with observed changes in group D evident in marked infiltration of polymorphs (white arrow) on the surface and deep into the wound, marked fibroblastic activity and moderate fibrous connective tissue formation. H & E x400

DISCUSSION

The aim of the study was to find the optimum strength of H_2O_2 for wound dressing with respect to selected wound healing indices. No physically observable tissue damage was detected in the groups treated with normal saline, 1% or 3% hydrogen peroxide. This indicates that the undesirable caustic action of higher concentrations of hydrogen peroxide had been lost or significantly reduced at the given concentrations.

The fastest wound contraction which was observed in 3 % H_2O_2 treated group could be attributed to its efficacy as antimicrobial agent. Antimicrobial agents kill microbes by interrupting their cellular respiration [18]. They prevent the entrance of microbes into the wound site, thereby ensuring minimal tissue damage around the wound [19]. Wound contraction and epithelialization are essential steps in the healing process of excision wounds. According to Eichler *et al* [20], contraction of wound begins approximately one week after wounding, when fibroblasts have differentiated into myofibroblasts. Wound contraction as documented by Sussman *et al* [21] peaks at 5 - 15 days post-wounding.

Histologically, certain features are important in assessment of wound healing. They include polymorphonuclear leucocyte (PMNLS) infiltration, presence or absence of macrophages, fibroblast, tissue re-epithelialization, neovascularization, and amount

of collagen deposition. Their presence in the tissues samples was used to determine the optimum concentration that would enhance wound healing with little or no side effects.

Histologically, organized fibrous tissues and a preponderance of fibrocytes were evident by day 14 in the group treated with 3 % H_2O_2 . This histological finding indicates that healing was very fast and was nearing completion in this group. It suggests that the maturation phase of fibroblasts had come to completion. According to Hinz [22], activities of myofibroblasts are essential for wound healing inasmuch as they generate contractile force that enhances wound contraction. The major source of myofibroblasts are fibrocytes [23]. About 30 - 50 % of myofibroblast in the wound may be derived from fibrocyte progenitors.

The haemorrhagic lesions and marked infiltrations of polymorphonuclear leukocytes observed in 5 % H_2O_2 and normal saline treated wounds on day 14 post-wounding could be attributed to the damaging effect of 5 % H_2O_2 on tissue and blood vessel supplying the wound area. Such damaged tissue microenvironment retards connective tissues formation and causes excessive proteolysis that result in a delayed wound healing [24]. In the normal saline treated groups, the same condition may have also weakens the bactericidal effect of normal saline and resulted in poor wound healing indices. Loss or attenuation of bacteriostatic or bactericidal effects in wound microenvironment enhances tissue damage, and delays fibroplasia and collagen synthesis [25]; this, therefore, is a conceivable reason why poor contraction and delayed epithelialization time were recorded in the normal saline treated group.

CONCLUSION

The results of this study show that 3 % H_2O_2 is the optimum concentration of hydrogen peroxide necessary for wound dressing based on the evidence of enhanced wound healing with no visible side effects.

DECLARATIONS

Acknowledgement

The authors wish to acknowledge the laboratory staff of Departments of Veterinary Surgery, and Veterinary Pathology of University of Nigeria, for their technical support towards the completion of this research.

Conflict of interest

The authors state that conflict of interest does not exist with respect to this work.

Authors' contribution

Authors named in this article contributed equally to all parts of this research.

Open Access

This is an Open Access article that uses a funding model which does not charge readers or their institutions for access and distributed under the terms of the Creative Commons Attribution License (<http://creativecommons.org/licenses/by/4.0>) and the Budapest Open Access Initiative (<http://www.budapestopenaccessinitiative.org/read>), which permit unrestricted use, distribution, and reproduction in any medium, provided the original work is properly credited.

REFERENCES

1. Tandara AA, Mustoe TA. Oxygen in wound healing—more than a nutrient. *World J Surg* 2004; 28(3): 294–300.
2. Room TS, Ukrainsky. Modulation of wound response and soft tissue in growth in synthetic allogeneic implants with platelet concentrate. *Arch Facial Plastic Surg* 2005; 7:163-169.
3. Drouso A, Fallabella A, Robert SK. Antiseptic on wound area of controversy. *Wounds* 2003; 15:149-166.
4. Zhu J, Bin Li, Horby J, Friis E, Pilgaard B, Jorgenson T. Smoking as a risk factor for wound healing and infection in breast cancer surgery. *Euro J Surg Oncol* 2002; 28: 815-820.
5. Bruno DW, Raynard RS. Studies on use of hydrogen peroxide as a method for the control see lice on Atlantic Salmon. *Aquacu Int* 1994; 2: 10-18.
6. Neithammer P, Grabher C, Look AT, Mitchison TJ. A tissue-scale gradient of hydrogen Peroxide mediates rapid wound detection in Zebrafish. *Nature* 2009; 459: 996-999.
7. Alam G, Singh M P, Singh A. Wound healing potential of some medicinal plants. *Intl J Pharm Sci Rev Res* 2011; 9(1): 136–145.
8. Tidhar D, Keren E, Brandin G, Yogev M, Armer JM. Effectiveness of compression bandaging education for wound care nurses. *J Wound Care* 2017; 26(11): 625–631.
9. Kwakman PH, Te Velde AA, de Boer L, Vandenbroucke-Grauls CM, Zaat SA. Two major medicinal honeys have different mechanisms of bactericidal activity. 2011; <https://doi.org/10.1371/journal.pone.0017709>
10. Leila AA, Khaled T, Nawel AA, Mohamed B, Cesar R, Amparo R. Euphorbia honey and garlic: Biological activity and burn wound recovery. *Burns* 2019; Nov;45(7):1695-1706. doi: 10.1016/j.burns.2019.05.002. Epub 2019 Jun 2.
11. Schater M, Werner S. Oxidative stress in normal and impaired wound repair. *Pharmacol Res* 2008; 58: 165-171.
12. Loo AE, Halliwell B. Effects of hydrogen peroxide in a keratinocyte-fibroblast co-culture model of wound healing. *Biochem Biophys Res Commun* 2012; 423: 253-258.
13. Sleigh JW, Linter SP. Hazards of Hydrogen peroxide. *Br Med J Clin Res* 1985; 291(6510): 1706.
14. Gruber RP, Vistnes L, Pardoe R. The effect of commonly used antiseptics on wound healing. *Plastic Recon Surg* 1975; 55(4): 472-476.
15. NIH, 1985. *Guide for the Care and Use of Laboratory Animal (Revised). 8th Edition.* National Academies Press, 500 Fifth Street, NW, Lockbox 285, Washington, DC, United States of America. pp: 83-123
16. Chah KF, Eze CA, Emuelosi CE, Esimone CO. Antibacterial and wound healing properties of methanolic extracts of some Nigerian medicinal plants. *J Ethnopharmacol* 2006; 104(1-2): 164-167.
17. Okoli CO, Ezike AC, Akah PA, Udegbunam SO, Okoye TC, Mbanu TP, Ugwu E. Studies on wound healing and antiulcer activities of extract of aerial parts of *Phyllanthus niruri* L. (Euphorbiaceae) *Am J Pharmacol Toxicol* 2009; 4: 118-126.
18. VinodKumar CS, Suneeta BK, Chethan KS, Abhishek KB, Varsha G, Sumanth B, Sanjay SU, Usha NP. Ability of bacteriophage in resolving wound infection caused by multidrug-resistant *Acinetobacter baumannii* in uncontrolled diabetic rats. *Microb Drug Resist*; 2015 Apr;21(2):171-7.
19. Edward R, Harding GK. Bacterial and wound healing. *Current Opinion in Infectious Disease* 2004; 17: 91-96.
20. Eichler MJ, Carlson MA, and Margret K. Modeling dermal granulation tissue with the linear populated collagen matrix: *J Dermatolo Sci* 2006; 41: 97-108.
21. Sussman C, Bates-Jensen BM. Wound healing physiology: acute and chronic. *Wound Care a Collaborative Practice Manual for Health Professionals* 2007; 21–51.
22. Hinz BJ. Formation and function of myofibroblast during tissue repair. *J Investigative Dermatol* 2007; 127: 526-537.
23. Li B, Wang JH. Fibrioblasts and myofibroblasts in wound healing; Force generation and measurement. *J Tissue Viability* 2011; 20: 108-120.
24. Waldman K, Lobman R, Schultz G, Schweck and Lehnert. Expression of matrix Metaloproteinase and their inhibitors in wound diabetic and non-diabetic patients. *Diabeol* 2002; 45: 1011-1016.
25. Udegbunam SO, Udegunam RI, Muobgo CC, Anyanwu MU, Nwaehujor CO. Wound healing and antimicrobial

properties of methanolic properties of popalia Lapacea

Juss in rats. BMC Complem Altern Med 2014; 14: 157.