

Original Research Article

Differential expressions of TGF- β 1, HIF-1, VEGF, α -SMA and E-cadherin in renal tissues of a neonatal rat model of hydronephrosis

Leibo Wang, Jianhua He, Ketao Xu, Weichao Zhu, Ketao Xu*

Pediatric Surgery, The Affiliated Hospital of Medical School, Ningbo University, Ningbo City, China

*For correspondence: Email: szkj4n@163.com

Sent for review: 31 May 2021

Revised accepted: 31 August 2021

Abstract

Purpose: To investigate the differential expressions of transforming growth factor- β 1 (TGF- β 1), hypoxia inductive factor-1 (HIF-1), vascular endothelial growth factor (VEGF), α -smooth muscle protein (α -SMA) and E-cadherin in renal tissues of neonatal rat model of hydronephrosis.

Methods: The neonatal rats (90) were randomly divided into sham group and model group. The rats in the model group were further divided into two subgroups: week 1 and week 12 after relief of obstruction, with 30 rats in each group. Six rats were taken from each group for the determination of renal histopathological changes. Levels of TGF- β 1, HIF-1, VEGF, α -SMA and E-cadherin in renal tissues were compared for different pathological grades and at different time points of obstruction relief.

Results: With increase in Elder grade, the concentrations of TGF- β 1, HIF-1, VEGF and α -SMA in renal tissues of hydronephrosis neonatal rats were gradually increased, while the expression level of E-cadherin gradually decreased ($p < 0.05$). However, the concentrations of TGF- β 1, HIF-1, VEGF and α -SMA in renal tissues were significantly reduced, while the expression level of E-cadherin was upregulated with time after relief of obstruction ($p < 0.05$).

Conclusion: These findings are of great significance in determining the degree of kidney injury and recovery, and for the development of drugs for the treatment of renal injury.

Keywords: Hydronephrosis, Renal tissue, E-cadherin, transforming growth factor- β 1 (TGF- β 1), hypoxia inductive factor-1 (HIF-1), vascular endothelial growth factor (VEGF), α -smooth muscle protein (α -SMA)

This is an Open Access article that uses a funding model which does not charge readers or their institutions for access and distributed under the terms of the Creative Commons Attribution License (<http://creativecommons.org/licenses/by/4.0>) and the Budapest Open Access Initiative (<http://www.budapestopenaccessinitiative.org/read>), which permit unrestricted use, distribution, and reproduction in any medium, provided the original work is properly credited.

Tropical Journal of Pharmaceutical Research is indexed by Science Citation Index (SciSearch), Scopus, International Pharmaceutical Abstract, Chemical Abstracts, Embase, Index Copernicus, EBSCO, African Index Medicus, JournalSeek, Journal Citation Reports/Science Edition, Directory of Open Access Journals (DOAJ), African Journal Online, Bioline International, Open-J-Gate and Pharmacy Abstracts

INTRODUCTION

Hydronephrosis is a common clinical manifestation caused by kidney stone, pressure, deformity and other internal and external renal factors acting on the urinary system, which are often accompanied by atrophy of renal tissue. If hydronephrosis is not alleviated in time, urine pressure will lead to gradual thinning down of the

renal cortex, aggravation of the degree of hydronephrosis, and exacerbation of ischemia and hypoxia of renal tissue, eventually leading to the loss of renal function [1].

Congenital hydronephrosis is a common disease in pediatric urology, and its pathogenesis is relatively complex. Since the degree of renal damage in congenital hydronephrosis often

necessitates selection of treatment methods and evaluation of postoperative efficacy, early assessment of the degree of renal damage in patients is of great significance in the treatment of congenital hydronephrosis [2]. In recent years, several cytokines have been implicated in renal damage [3]. It has been reported that TGF- β 1, HIF-1, VEGF, α -smooth muscle protein (α -SMA) and E-cadherin are involved in the pathogenesis of congenital hydronephrosis, to varying degrees [4]. However, not much is known on whether these indices can be used to determine the severity of kidney damage.

In this study, neonatal mice were used to establish an animal model of hydronephrosis, and the relationship between renal damage and these indices was investigated by assaying changes in concentrations of TGF- β 1, HIF-1, VEGF, α -SMA and E-cadherin in renal tissue.

EXPERIMENTAL

Animals

Adult SPF female and male Wistar rats were obtained from Guangzhou University of Chinese Medicine [production license SCXK (Guangdong) 2019-0047, usage license SYXK: Guangdong; 2019-0202)]. The rats had a mean body weight of 213 ± 27 g. They were maintained adaptively for 1 week in an environment with 12-h light/12-h dark cycle at a temperature of 24 ± 1 °C and relative humidity of 45 ± 5 %, with free access to feed and water. This research was approved by the Animal Ethical Committee of The Affiliated Hospital of Medical School (approval no. 20200904), and followed the guidelines of "Principles of Laboratory Animal Care" (NIH publication no. 85-23, revised 1985) [5].

Main equipment and reagents

The major instruments and reagents used, and their suppliers (in parenthesis) were: electronic balance (Shanghai Shunyu Hengping Scientific Instrument Co. Ltd, model: JA12002); low-temperature high-speed centrifuge (Eppendorf China Co. Ltd, model: 5427R); optical microscope (Shenzhen Shengtian Instrument Co. Ltd, model: ST-T200); hematoxylin and eosin dyes (Shanghai Xinfan Biotechnology Co. Ltd, specifications: 25 mL), and neutral gum (Shanghai Kemin Biotechnology Co. Ltd).

Treatments

Female rats in estrus were caged together with male rats. The rats were separated on the next day, and the female rats were examined for

vaginal secretions. If sperm or vaginal plugs were found, pregnancy was considered successful. When the rats littered, 90 neonatal rats were randomly divided into sham group ($n = 30$) and model group ($n = 60$). The model group was further divided into two groups: week 1 after relief of obstruction (sacrificed at 3 weeks after infarction), and week 12 after relief of obstruction (obstruction was removed 3 weeks after infarction and rats were sacrificed at 12 weeks thereafter), with 30 rats in each group.

To establish the animal model of hydronephrosis, the neonatal rats were anesthetized and fixed on the operating table. The left rectus abdominis was cut layer by layer to expose and remove the upper segment of the left ureter. The dorsal psoas major muscle was obtusely separated along the upper segment of the ureter, and a fissure 0.4 cm long and 0.2 cm deep was separated. The upper part of the ureter was buried in the fissure, and the psoas major fissure was closed so that the upper part of the ureter was compressed by the psoas major in the fissure. The abdominal cavity was closed and the rats were caged. At 3 weeks and 12 weeks after obstruction, the obstruction was removed from each rat, the abdomen was relieved, and the left kidney was exposed. The model was considered successfully established if the renal pelvis of the left kidney was enlarged and full. The young rats in the sham operation group were not treated with ureteral embedding.

H & E staining

Renal histopathological changes at 3 weeks and 12 weeks after obstruction in the sham operation group and the model group were assessed with H & E staining method. Six rats were sacrificed after 3 weeks and 12 weeks of obstruction. The kidney tissues were sliced into 5- μ m paraffin sections which were dried in an oven at 45 °C. The samples were stained with hematoxylin, dyed pink in acid water and ammonia water, washed with tap water, and dehydrated with alcohol. Thereafter, the samples were stained with eosin for 3min. After dehydration, clearing and sealing, the samples were examined under a microscope, and any observed changes were recorded.

Based on the Elder method, the renal histological changes in rats were divided into 5 grades: grade I was for normal kidney (3 cases); grade II was for mild obstructive nephropathy (6 cases); grade III referred to moderate obstructive nephropathy (10 cases); grade IV was for severe obstructive nephropathy (5 cases); while grade V was

severe obstructive nephropathy with subcapsular microcyst formation (no case).

Immunohistochemistry

The degrees of expressions of TGF- β 1, HIF-1, VEGF, α -SMA and E-cadherin in different pathological grades were compared at different time points after obstruction relief, using immunohistochemical methods. Following deparaffinization prior to immunohistochemical staining, the sections were incubated with rabbit anti-TGF- β 1, HIF-1, VEGF, α -SMA and E-cadherin polyclonal antibody overnight at 4°C, followed by rinsing and incubation with secondary antibody using Histofine SAB-PO(R) Kit (Nichirei Co., Japan). Finally, the sections were subjected to examination under a microscope, and photographed.

Statistical analysis

Independent sample *t*-test was used for inter-group comparison of measurement data between two groups, while single-factor and multi-sample mean comparison were used for comparison amongst multiple groups. ANOVA was used to compare the same index at different time points, while independent sample *t*-test was used to compare groups at different time points. The SPSS22.0 software package was used for statistical data analysis. Values of $p < 0.05$ indicated statistically significant differences. Spearson correlation test was used to analyze the correlation between the expression levels of TGF- β 1, HIF-1, VEGF, α -SMA and E-cadherin, and pathological grade.

RESULTS

Renal histopathological changes in neonatal rats

In the control group, the glomerular structure and morphology of young rats were normal, without dilatation. At week 1 after relief of obstruction, the glomerulus was shrunk and deformed, and

the lumen was dilated. The atrophied glomeruli were fuller at 12 weeks after relief of obstruction, and the dilatation of lumen was alleviated, relative to week 1 after relief of obstruction. These results are shown in Figure 1.

Changes in levels of TGF- β 1, HIF-1, VEGF, α -SMA and E-cadherin in different pathological grades

With increase in Elder grade, the expression levels of TGF- β 1, HIF-1, VEGF and α -SMA in renal tissues of hydronephrosis infant rats were gradually increased, while that of E-cadherin was gradually decreased ($p < 0.05$). These results are shown in Table 1.

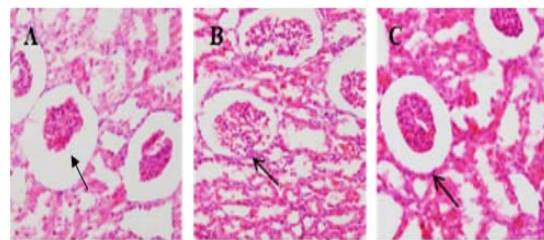


Figure 1: Renal histopathological changes in rats in each group. A: sham operation group; B: week 1 after relief of obstruction; C: week 12 after relief of obstruction

Changes in expression levels of TGF- β 1, HIF-1, VEGF, α -SMA and E-cadherin in renal tissues at different time points of obstruction relief

Compared with sham group, levels of TGF- β 1, HIF-1, VEGF and α -SMA in week 1 group after relief of obstruction were significantly increased, while that of E-cadherin was markedly decreased ($p < 0.05$). However, relative to week 1 group after relief of obstruction, levels of TGF- β 1, HIF-1, VEGF and α -SMA in week 12 group after relief of obstruction were markedly decreased, while that of E-cadherin was significantly increased ($p < 0.05$). These results are shown in Table 2.

Table 1: Changes in expression levels of TGF- β 1, HIF-1, VEGF, α -SMA and E-cadherin in different grades

Group	TGF- β 1	HIF-1	VEGF	α -SMA	E-cadherin
I	2.33±0.45	96.91±2.81	104.54±2.18	10.55±0.57	34.35±0.54
II	5.46±1.22	108.28±4.74	109.62±3.24	14.95±2.11	23.08±1.58
III	8.42±2.44	116.53±4.19	116.18±3.67	17.29±1.61	20.92±1.13
IV	13.05±1.99	124.74±5.58	120.46±4.96	21.51±2.13	17.35±0.97
V	-	-	-	-	-
F	22.79	27.78	15.14	25.98	136.67
P-value	<0.001	<0.001	<0.001	<0.001	<0.001

Table 2: Changes in expression levels of TGF- β 1, HIF-1, VEGF, α -SMA and E-cadherin in renal tissues of sham operation group and at different time points of obstruction relief

Infarction time	TGF- β 1	HIF-1	VEGF	α -SMA	E-cadherin
Sham	0.83 \pm 0.36	94.54 \pm 3.18	93.97 \pm 3.31	1.08 \pm 0.26	38.35 \pm 0.67
1 week	15.17 \pm 1.89	125.46 \pm 5.59	117.73 \pm 3.62	23.67 \pm 2.74	15.35 \pm 0.59
12 weeks	1.53 \pm 0.61	114.79 \pm 4.67	100.80 \pm 2.96	12.69 \pm 1.69	33.71 \pm 1.22
F	1155.21	281.14	328.25	880.80	4660.64
P-value	<0.001	<0.001	<0.001	<0.001	<0.001

Data are presented as mean \pm SD

Correlation between pathological grade and expression levels of TGF- β 1, HIF-1, VEGF, α -SMA and E-cadherin

As shown in Table 3, Spearson correlation analysis revealed that Elder grade was significantly and positively correlated with expression levels of TGF- β 1, HIF-1, VEGF and α -SMA, and negatively correlated with E-cadherin expression level ($p < 0.05$).

Table 3: Correlation between pathological grade and expression levels of TGF- β 1, HIF-1, VEGF, α -SMA and E-cadherin

Index	Elder grade	
	r	P-value
TGF- β 1	0.864	<0.05
HIF-1	0.567	<0.05
VEGF	0.628	<0.05
α -SMA	0.761	<0.05
E-cadherin	- 0.337	<0.05

DISCUSSION

Congenital hydronephrosis is one of the most common diseases of the urinary system in children. Advances in medical science and technology, and the popularization of prenatal tests have led to significant improvements in the diagnoses of hydronephrosis. Currently, the degree of detection of neonatal hydronephrosis is about 1 %. The pathogenesis of hydronephrosis is relatively complex. Studies have shown that obstruction of the ureteropelvic junction is the main cause of more than 85 % of hydronephrosis cases seen in clinical practice [6].

Obstructions at the ureteropelvic junction may block outflow of urine, leading to hydronephrosis and dilation of the renal pelvis and calices, renal compression of parenchyma and ischemia, and ultimately to impairment of renal function [7]. In recent years, advanced molecular biology techniques have been gradually applied in the study of hydronephrosis, with research focused on a new field dealing with the mechanism of renal damage in hydronephrosis patients. This is aimed at acquiring a deeper understanding of

hydronephrosis caused by ureteral obstruction. Moreover, the clinical treatment for hydronephrosis has continued to attract more and more attention from physicians.

The TGF- β superfamily is a class of cytokines that regulate cell growth, differentiation and secretion. It is known that TGF- β 1, a member of the TGF- β superfamily, is a fibrogenic factor that enhances the synthesis of extracellular matrix, reduces its degradation, inhibits cell mitosis, and promotes intercellular fibrosis [8]. In studies on chronic kidney diseases, some scholars have found that TGF- β 1 binds to its corresponding receptor, replicates in the nucleus through the transcription of Smad protein, and promotes the aggregation of a large number of extracellular matrix proteins, thereby promoting renal interstitial fibrosis, and damaging renal tubular epithelial cells [9]. The results of this study showed that the expression level of TGF- β 1 in renal tissue is of great significance to the degree of renal damage and recovery.

It is generally believed that hydronephrosis causes up-regulation or down-regulation of a large number of molecular substances in renal tissue, thereby affecting the recovery of renal function, or accelerating renal failure [10]. In recent years, studies have shown that microvascular injury is one of the important causes of renal failure after hydronephrosis [11]. Hypoxia-inducing factor-1 (HIF-1) participates in the transcription and regulation of target genes through a variety of signaling pathways, thereby improving tissue and local ischemia and hypoxia [12]. One of the target genes of HIF-1 is VEGF. Indeed, VEGF is currently considered to be the most important angiogenic factor which promotes the migration and proliferation of endothelial cells and enhances their permeability and angiogenesis [13].

Studies have confirmed that VEGF significantly increases the expression level of VEGFR-2 during the development of glomerular endothelial cells in neonatal rats. However, a study has reported that following blockage of VEGF, the generation of renal cortical blood vessels in neonatal rats was inhibited, and some glomeruli

lacked capillary network, suggesting that VEGF maintains glomerular development and maturation [14]. The results of the present study suggest that HIF-1 and VEGF may be involved in the development of hydronephrosis in neonatal rats.

The α -SMA is a major marker protein for phenotypic transformation of renal tubular epithelial cells. Studies have shown that under normal conditions, α -SMA is only expressed on vascular smooth muscle cells in the kidney, but under pathological conditions, α -SMA is expressed on renal tubular epithelial cells, suggesting that renal tubular epithelial cells have the characteristics of myofibroblasts [15]. E-Cadherin, a calcium-dependent adhesion molecule and a major component of cell juncture, plays important roles in embryonic development, morphogenesis, and maintenance of epithelial polarity and integrity in adult tissues. When E-cadherin expression is down-regulated, the integrity of renal tubular epithelial cells may be damaged, and the cell boundaries may become unclear and gradually separated. In disease state, E-cadherin is gradually replaced by α -SMA-positive fibroblasts [16]. The results of this study showed that the expression level of α -SMA was significantly increased, while that of E-cadherin was markedly decreased in neonatal rats with hydronephrosis. Thus, α -SMA and E-cadherin are of great significance as indices of renal damage.

CONCLUSION

There are significant higher levels of TGF- β 1, HIF-1, VEGF, α -SMA and E-cadherin in renal tissues of neonatal rat with hydronephrosis, but the level of E-cadherin is markedly lower. These findings are of great significance in the assessment of the degree of kidney injury and recovery, and therefore, may be useful in the development of new drugs for the treatment of renal injury.

DECLARATIONS

Conflict of interest

No conflict of interest is associated with this work.

Contribution of authors

We declare that this work was performed by the authors named in this article, and all liabilities pertaining to claims relating to the content of this article will be borne by the authors. Leibo Wang

designed the study, supervised the data collection, and analyzed the data. Jianhua He, Ketao Xu and Weichao Zhu interpreted the data and prepared the manuscript for publication. Ketao Xu supervised the data collection, analyzed the data and reviewed the draft of the manuscript.

Open Access

This is an Open Access article that uses a funding model which does not charge readers or their institutions for access and distributed under the terms of the Creative Commons Attribution License (<http://creativecommons.org/licenses/by/4.0>) and the Budapest Open Access Initiative (<http://www.budapestopenaccessinitiative.org/read>), which permit unrestricted use, distribution, and reproduction in any medium, provided the original work is properly credited.

REFERENCES

1. Santos AI, Violante L, Carmona S, Prata A, Rodrigues VM, Santos JG, Araújo SJ, Alves M, Papoila AL, Piepsz A. Interobserver agreement on cortical tracer transit in 99mTc-MAG3 renography applied to congenital hydronephrosis. *Nucl Med Commun* 2017; 38(2): 124-128.
2. Zhao Q, Yang Y, Wang C, Hou Y, Chen H. ATP5B and ETFB metabolic markers in children with congenital hydronephrosis. *Mol Med Rep* 2016; 14(6): 5111-5115.
3. Landsend ECS, Utheim ØA, Pedersen HR, Aass HCD, Lagali N, Dartt DA, Baraas RC, Utheim TP. The Level of Inflammatory Tear Cytokines is Elevated in Congenital Aniridia and Associated with Meibomian Gland Dysfunction. *Invest Ophthalmol Vis Sci* 2018; 59(5): 2197-2204.
4. Guo M, Mu Y, Yu D, Li J, Chen F, Wei B, Bi S, Yu J, Liang F. Comparison of the expression of TGF- β 1, E-cadherin, N-cadherin, TP53, RB1CC1 and HIF-1 α in oral squamous cell carcinoma and lymph node metastases of humans and mice. *Oncol Lett* 2018; 15(2): 1639-1645.
5. World Health Organization. Principles of laboratory animal care. *WHO Chron* 1985; 39: 51-56.
6. Bazic-Dorovic B, Radulovic M, Sisic M, Jaukovic L, Dugonjic S, Pucar D, Jankovic Z, Beatovic S, Jankovic M, Krstic Z, et al. Technetium-99m-dimercaptosuccinic acid renal scintigraphy can guide clinical management in congenital hydronephrosis. *Hell J Nucl Med* 2017; 20 Suppl: 114-122.
7. Xie J, Zhou Y, Gao W, Li Z, Xu Z, Zhou L. The relationship between amniotic fluid miRNAs and congenital obstructive nephropathy. *Am J Transl Res* 2017; 9(4): 1754-1763.
8. Shiina Y, Niwa K. Cardio-Ankle Vascular Index (CAVI) and Plasma Transforming Growth Factor- β 1 (TGF- β 1)

- Level Correlate with Aortopathy in Adults with Repaired Tetralogy of Fallot. *Pediatr Cardiol* 2017; 38(2): 338-343.
9. Moore-Smith LD, Isayeva T, Lee JH, Frost A, Ponnazhagan S. Silencing of TGF- β 1 in tumor cells impacts MMP-9 in tumor microenvironment. *Sci Rep* 2017; 7(1): 8678.
 10. Nikolopoulou E, Galea GL, Rolo A, Greene ND, Copp AJ. Neural tube closure: cellular, molecular and biomechanical mechanisms. *Development* 2017; 144(4): 552-566.
 11. Li X, Liu X, Li J, Song E, Sun N, Liu W, Wang T, Yang J, Li Z. Semaphorin-3A and Netrin-1 predict the development of kidney injury in children with congenital hydronephrosis. *Scand J Clin Lab Invest* 2018; 78(1-2): 55-61.
 12. Piccoli M, Conforti E, Varrica A, Ghiroldi A, Cirillo F, Resmini G, Pluchinotta F, Tettamanti G, Giamberti A, Frigiola A, Anastasia L. NEU3 sialidase role in activating HIF-1 α in response to chronic hypoxia in cyanotic congenital heart patients. *Int J Cardiol* 2017; 230: 6-13.
 13. Bimpaki E, Bitsori M, Choulaki C, Galanakis E. Vascular endothelial growth factor-A gene polymorphism is associated with congenital renal lesions in children with urinary tract infections. *Acta Paediatr* 2017; 106(8): 1348-1353.
 14. Mavroudis CD, Seung Kim D, Burnham N, Morss AH, Kim JH, Burt AA, Crosslin DR, McDonald-McGinn DM, Zackai EH, Cohen MS, et al. A vascular endothelial growth factor A genetic variant is associated with improved ventricular function and transplant-free survival after surgery for non-syndromic CHD. *Cardiol Young* 2018; 28(1): 39-45.
 15. Li YH, Choi DH, Lee EH, Seo SR, Lee S, Cho EH. Sirtuin 3 (SIRT3) Regulates α -Smooth Muscle Actin (α -SMA) Production through the Succinate Dehydrogenase-G Protein-coupled Receptor 91 (GPR91) Pathway in Hepatic Stellate Cells. *J Biol Chem* 2016; 291(19): 10277-10292.
 16. Lee DW, Chung JH, Lee SH, Park CW, Kang SH, Oh YH, Pyo JY. Comparative analysis of the expression of E-cadherin, β -catenin, and β 1 integrin in congenital and acquired cholesteatoma. *Eur Arch Otorhinolaryngol* 2016; 273(4): 845-851.