

## Original Research Article

# Gastroprotective and ulcer healing properties of ethanol extract of *Alpinia conchigera* rhizome in experimentally-induced gastric ulcer in rats

Xin Jin<sup>1</sup>, Qiang Liu<sup>2</sup>, Minyan Dang<sup>3</sup>, Wenzhi Zhang<sup>3</sup>, Xia Li<sup>4\*</sup>

<sup>1</sup>General Surgery Department, Ankang Central Hospital, Shaanxi 725000, <sup>2</sup>Department of Gastroenterology, Liaocheng Women and Children Health, Shandong Province 252000, China, <sup>3</sup>Innoscience Research Sdn Bhd, Suites B-5-7, Skypark@One City, Jalan USJ 25/1, 47650 Subang Jaya, Selangor Malaysia, <sup>4</sup>Department of Chinese Medicine, Jinan Central Hospital, No. 105, Jie Fang Road, Li Xia District, Jinan, Shandong Province 250013, China

\*For correspondence: **Email:** [xli670@yahoo.com](mailto:xli670@yahoo.com)

Sent for review: 17 August 2018

Revised accepted: 21 August 2019

## Abstract

**Purpose:** To investigate the gastroprotective effect of *Alpinia conchigera* rhizome in an ulcer rat model.

**Method:** Sprague-Dawley rats were treated with ethanol extract of *Alpinia conchigera* at doses of 75 and 150 mg/kg body weight. After 28 days, the rats were sacrificed. Ulcer index, total acidity, pH, hemoglobin levels, and hemorrhagic lesions were determined through macroscopic assessment and histopathological examination. The levels of lipid peroxidation (LPO), superoxide dismutase (SOD), and catalase (CAT), and inflammatory markers (TNF- $\alpha$ , IL-1 $\beta$ , and IL-6) were also determined.

**Results:** *Alpinia conchigera* significantly reduced ulcer index, total acidity, pH and hemoglobin levels ( $p < 0.05$ ). Results from histology revealed that the extract protected the mucosa from lesions. Moreover, the extract significantly enhanced gastric mucosal activities of SOD and CAT, and decreased LPO levels and plasma concentrations of TNF- $\alpha$ , IL-1 $\beta$ , and IL-6 ( $p < 0.05$ ).

**Conclusion:** These results validate the traditional claims on the gastroprotective effects of *Alpinia conchigera* as revealed through its antioxidant and ulcer-healing properties by stimulation of important cellular mechanisms.

**Keywords:** *Alpinia conchigera*, Antioxidant enzymes, Gastric ulcer, Inflammatory cytokines

This is an Open Access article that uses a fund-ing model which does not charge readers or their institutions for access and distributed under the terms of the Creative Commons Attribution License (<http://creativecommons.org/licenses/by/4.0>) and the Budapest Open Access Initiative (<http://www.budapestopenaccessinitiative.org/read>), which permit unrestricted use, distribution, and reproduction in any medium, provided the original work is properly credited.

Tropical Journal of Pharmaceutical Research is indexed by Science Citation Index (SciSearch), Scopus, International Pharmaceutical Abstract, Chemical Abstracts, Embase, Index Copernicus, EBSCO, African Index Medicus, JournalSeek, Journal Citation Reports/Science Edition, Directory of Open Access Journals (DOAJ), African Journal Online, Bioline International, Open-J-Gate and Pharmacy Abstracts

## INTRODUCTION

Gastric mucosal integrity is associated with various factors such as maintenance of microcirculation, secretion of alkaline mucus, antioxidant effects, LPO, SOD and CAT, all of which are linked to the endogenous and exogenous protection of the stomach lumen from gastro-irritants. Earlier studies have shown that

disturbances in gastric mucosal blood perfusion might cause formation of ulcers and erosions [1]. The gastric mucosal antioxidant enzyme, SOD catalyzes the dismutation of superoxide radical anion ( $O_2^-$ ) into the less noxious  $H_2O_2$  which is further inactivated by glutathione peroxidase (GPx) [2,3].

Pro-inflammatory cytokines, tumor necrosis factor- $\alpha$  (TNF- $\alpha$ ), interleukin-1 $\beta$  (IL-1 $\beta$ ), and interleukin-6 (IL-6) are involved in the pathogenesis of gastric ulcer [1]. Clinical and experimental data have shown that ulcerogenic factors such as stress, non-steroidal anti-inflammatory drugs (NSAIDs), and *H. pylori* increase the expressions of pro-inflammatory cytokines in the gastric mucosa [4]. Hence, the antioxidant and inflammatory responses at the ulcer site might be critical for ulcer healing.

Medicinal plants from various climes have been associated with gastric ulcer treatment [5]. One of such herbs is *Alpinia conchigera* Griff. (Zingiberaceae), which in Malay, is called *lengkuas ranting*. Different parts of *A. conchigera* (e.g. rhizome, leaves and young shoots) are used as medicines for treating muscle pains, sprains, and bleeding problems. It has been reported that 1,7-disphenyl-3,5-heptanedione, a compound isolated from the rhizome of *A. conchigera*, possesses anti-inflammatory properties [6]. Bioactive compounds like uegenol acetate, chavicol acetate and henylpropanoid have been isolated from the fruits of *A. conchigera* [7]. Other species of *Alpinia* also possess various pharmacological properties [8]. The current study was aimed at investigation of the antioxidant and anti-inflammatory effects of ethanol extract of *A. conchigera* rhizomes in a rat model of gastric ulcer.

## EXPERIMENTAL

### Chemicals and drugs

Paraffin, HCl/ethanol, cyanide/ferricyanide, Tris, butylated hydroxytoluene, Tween 80, hematoxylin/eosin, MNaCl, EDTA, glycerine, PMSF, leupeptin, xylene, NaOH, phenolphthalein, trichloroacetic acid, thiobarbituric acid, tetrahydrobenzofluorene, and aprotinin were purchased from Sigma Aldrich Pvt. Ltd. (USA). Assay kits (ELISA) for TNF- $\alpha$ , IL-1 $\beta$ , and IL-6 were procured from R & D systems (MN, USA). All chemicals used in the current research were of analytical grade.

### Plant material

Rhizomes of *A. conchigera* were collected from the Herb Garden, Jinan on November, 2017. They were taxonomically identified by a botanist (Mr. Li) affiliated to the Department of Chinese Medicine, Jinan Central Hospital, China. A voucher specimen (no. JH657821) was deposited at the herbarium of Department of Chinese Medicine, Jinan Central Hospital, China.

### Extract preparation

Approximately 50 g of *A. conchigera* rhizome was cleaned, washed, rinsed with distilled water, and dried at 45 °C overnight. The dried *A. conchigera* rhizome was ground into powder and homogenized in 95 % ethanol in the ratio of 1:10 (w/v) [9]. The homogenate was subjected to filtration, and the filtrate was kept in an incubator (50 °C) for up to 4 days. The solvent was removed through rotary evaporation at 50 °C, and the dry extract (approx. 1.34 g; yield = 2.67 %) was kept at a temperature of 4°C prior to use in subsequent experiments.

### Animals

Sprague-Dawley rats (200 - 300 g) were obtained from the Animal Unit of the Jinan Central Hospital, Jian, China. The animals were fed with a standard diet and water in an environment with 12 h light/12 h dark cycle at 22  $\pm$  2 °C. The animal studies were approved by the ethical committee of the Jilin University Cancer Center, China (approval no. 309/2018) and followed international guidelines [10].

### Induction of gastric ulcer by hydrochloric acid (HCl)/ethanol

Gastric hemorrhage lesions were induced in the rats using HCl/ethanol (0.1 mL/20 g) mixture (0.15 M HCl in 98 % ethanol) through oral administration [11].

### Experimental design

The rats were kept in individual cages and subjected to 24 h fasting with free access to clean drinking water. The water was withdrawn 1 h before inducing gastric ulcer. Forty rats were randomly divided into four groups (10 rats per group). Group I (control) rats received vehicle (0.1 % Tween 80 in normal saline) orally, while group II (HCL/ethanol) rats received HCl/ethanol mixture orally. Group III rats received *A. conchigera* extract at a dose of 75 mg/kg body weight (bwt), while rats in group IV were given *A. conchigera* extract at a dose of 150 mg/kg bwt.

The ethanol extract of *A. conchigera* rhizome was dissolved in 0.1 % Tween 80 (in normal saline) prior to administration. The dose regimens were selected based on a previous study on other *Alpinia* species [12].

### Tissue collection and preparation

After 1 h of ethanol administration, the animals were euthanized under deep ether anesthesia.

After laparotomy, the stomachs were opened and washed with normal saline to remove blood clots and gastric contents. The stomachs were blotted dry and inspected for gastric injury (expressed as ulcer index) and later investigated for gastric lesions. Then, all the stomachs were divided into portions. For histopathological analysis, one portion was fixed in 10 % buffered formol saline. The portion for glandular gastric tissues was divided into 3 parts and kept at -80°C for biochemical investigations. One part of the samples was homogenized in lysis buffer, pH 7.4 consisting of 200 mM NaCl, 5 mM EDTA, 10 mM Tris, 10 % glycerine, 1 mM PMSF, 1 mg/mL leupeptin, and 28 mg/mL aprotinin, for the assay of TNF- $\alpha$ , IL-1 $\beta$ , and IL-6. Another part of the sample was homogenized in ice-cold 100 mM phosphate buffer, pH 7.4 for estimation of antioxidant markers (LPO, SOD, and CAT).

### Gastric ulcerative lesions

The range of gastric damage was estimated by calculating the gastric lesion areas. The stomach was dissected, and blood clots were removed by rinsing with cold saline. Then, the flattened stomach of all the rats was photographed.

### Evaluation of ulcer index

The stomach was opened along the better curvature and rinsed slowly under tap water. The sample was then placed on a glass slide and observed under a microscope at x10 magnification. The ulcer index were expressed as mean score value for each rat.

### Histological examination

For histopathological examination, gastric tissue was fixed in 10 % buffered formol saline for 24 h. It was then washed and dehydrated with alcohol, and embedded in paraffin in an oven for an additional 24 h. The paraffin-embedded blocks were cut into 5- $\mu$ m thick sections using a microtome. The sections were examined under the light microscope after hematoxylin and eosin (H & E) staining.

### Determination of pH and total acidity

The pH of gastric juice was recorded using a digital pH meter. Gastric content was centrifuged and diluted with distilled water (1:10 v: v). The clear supernatant was titrated against 0.01 N NaOH, using Toper's reagent until orange color formation, which corresponded to free acidity, and then titrated to pink color with phenolphthalein. The total NaOH titer corresponded to the total acidity. The acidity was

expressed as *titre of NaOH  $\times$  normality  $\times$  100/0.1 milli-equivalents per litre/100g.*

### Assessment of hemoglobin

Buffered cyanide/ferricyanide reagent (5 mL) was pipetted into a clean and dry test tube. Then, 0.02 mL of blood was added to the tube. The solution was mixed well and incubated at 30 °C. Absorbance of sample was read against distilled water after 3 min at 546 nm. The concentration 'C' of hemoglobin was calculated as in Eq 1.

$$C \text{ (g/100 mL)} = 36.77 \times A \dots\dots\dots (1)$$

### Evaluation of cytokines

The levels of cytokines (TNF $\alpha$ , IL-1 $\beta$ , and IL-6) were assayed using ELISA kits in line with the manufacturer's protocol (R & D systems, USA). The cytokine experiment employs measurable sandwich enzyme immunoassay technique with pre-coated specific antibodies in the microplate. The rat cytokines were immersed to bind with immobilized antibody in standards, control, and samples. The unbound substances were washed and the specific rat cytokine enzyme-linked secondary antibody was added to the wells. Following development of color, the reactions were stopped, and the absorbance was read at 450 nm. The color intensity is proportional to corresponding amount of the targets bound in the primary step. The results were expressed in pg/g of tissue.

### Determination of lipid peroxidation

The reaction was carried out in 15 % (w/v) trichloroacetic acid, 0.375 % (w/v) thiobarbituric acid and 0.25 N HCl at 90 °C for 30 min. The mixture was cooled and centrifuged, and the precipitate was removed. The absorbance of resulting supernatant was read at 535 nm. The results were expressed in nmol/g of tissue.

### Evaluation of SOD activity

The SOD activity was assayed colorimetrically based on the SOD-mediated increase in the rate of autooxidation of tetrahydrobenzofluorene in alkaline aqueous solution to yield a chromophore which absorbs maximally at 525 nm. The results were expressed in U/g of tissue.

### Assessment of catalase

Gastric mucosal scrapings were homogenized in phosphate buffer at 1- 4°C, and centrifuged. The sediment was stirred in cold phosphate buffer, and was allowed to stand in the cold with occasional

shaking. The extraction procedure was repeated twice and the combined supernatant was used for CAT assay. The supernatant was diluted ten times with distilled water and 0.04 ml of the diluted supernatant was used for the assay. The decomposition of H<sub>2</sub>O<sub>2</sub> in presence of CAT was followed at 240 nm. The results were expressed in U/mg of wet tissue.

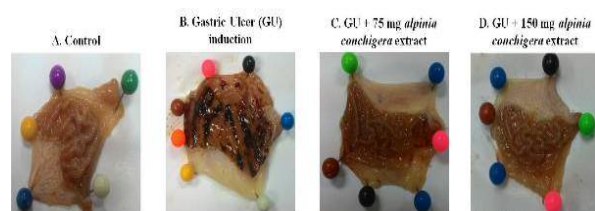
### Statistical analysis

Data are presented as mean ± standard error of the mean (SEM). SPSS 7.5 Windows (Student's version) software was used for data analysis. Statistical significance of differences between the control and treated groups were assessed using one-way ANOVA, followed by Student's–Newman–Keuls (SNK) test. Values of *p* < 0.05 were considered statistically significant.

## RESULTS

### Macroscopic features of ulcer injury

Figure 1 shows the severity of the gastric injury as seen through macroscopic examination. Huge areas of ulcerative gastric hemorrhagic lesions were observed in gastric ulcer rats, when compared to the control animals.



**Figure 1:** Macroscopic assessment of the healing of acute gastric mucosal injury induced by HCL/Ethanol in rats and its prevention by *Alpinia conchigera*. Section of rat stomachs obtained from A: normal control rats; B: ulcerated induced rats, C: ulcer induced animals treated with 75 mg/kg *Alpinia conchigera*; D: ulcer induced animals treated with 150 mg/kg *Alpinia conchigera*

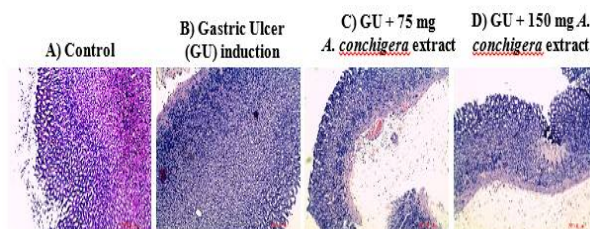
Interestingly, rats treated with *A. conchigera* showed significant mitigation of gastric mucosal

damage (inhibition of UI scores), as well as reductions in the area of gastric lesions associated with HCL/ethanol-induced gastric ulcer. These data show that *A. conchigera* decreased the incidence of ethanol-induced gastric ulcerative lesions.

Table 1 shows the levels of gastric index markers in the control and experimental rats.

### Histopathological features of *Alpinia conchigera*-treated rat gastric mucosa

Figure 2 shows the effect of *A. conchigera* on the histopathology of gastric damage induced by HCL/ethanol, relative to control rats. HCL/ethanol administration triggered severe gastric injury and disruption of the gastric mucosa, in addition to reduction in epithelial cells. However, *A. conchigera*-treated groups exhibited intact gastric architecture.



**Figure 2:** The histological effect of *Alpinia conchigera* on gastric mucosal - H&E staining in HCL/Ethanol induced gastric ulcer in rats. Section of rat stomachs obtained from A: normal control rats; B: ulcerated induced rats, C: ulcer induced animals treated with 75 mg/kg *Alpinia conchigera*; D: ulcer induced animals treated with 150 mg/kg *Alpinia conchigera*

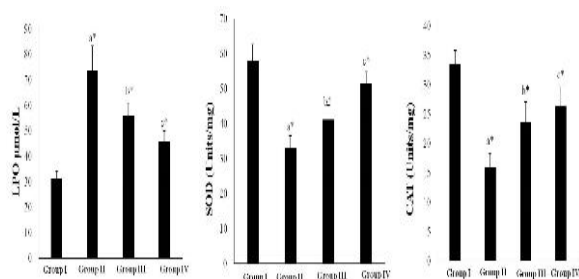
### Effect of *Alpinia conchigera* on antioxidant enzymes in rats

The HCL/ethanol-treated rats showed significant alterations in oxidative stress markers, with increased lipid peroxidation, when compared with control rats (Figure 3). However, rats treated with *A. conchigera* at doses of 75 and 150 mg/kg bwt had significantly attenuated oxidative stress.

**Table 1:** *A. conchigera* treated animals showed significantly lower levels of gastric index markers near towards normal rats

| Group | Treatment              | Ulcer index                | Total acidity                | pH                        | Hemoglobin                 |
|-------|------------------------|----------------------------|------------------------------|---------------------------|----------------------------|
| 1     | Control                | 0.0 ± 0.0                  | 113.01 ± 6.96                | 5.86 ± 0.35               | 15.5 ± 0.61                |
| 2     | GU                     | 15.36 ± 3.31 <sup>a†</sup> | 144.08 ± 12.76 <sup>a†</sup> | 3.43 ± 0.54 <sup>a†</sup> | 11.76 ± 0.96 <sup>a†</sup> |
| 3     | GU+ 150 mg A.c extract | 10.45 ± 1.7 <sup>b†</sup>  | 124.18 ± 6.51 <sup>b†</sup>  | 4.21 ± 0.38 <sup>b†</sup> | 13.68 ± 0.61 <sup>b†</sup> |
| 4     | GU+ 150 mg A.c extract | 3.71 ± 1.97 <sup>c†</sup>  | 112.41 ± 5.99 <sup>c†</sup>  | 4.83 ± 0.35 <sup>c†</sup> | 15.31 ± 0.63 <sup>c†</sup> |

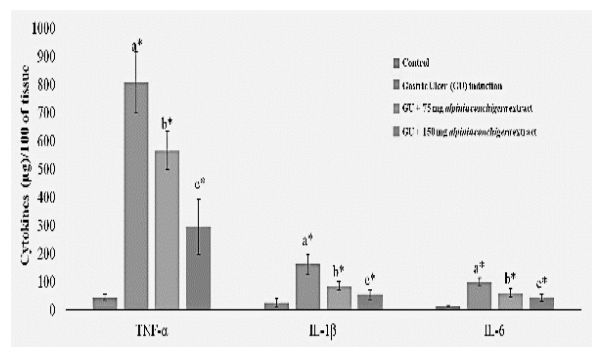
Statistical analysis revealed significant decreases in activities of SOD and CAT in the gastric tissue after HCl/ethanol treatment, when compared with control group. In contrast, administration of *A. conchigera* significantly reversed the decreases in activities of CAT and SOD in a dose-dependent manner, relative to rats in respective control groups.



**Figure 3:** Effects of *Alpinia conchigera* on lipid peroxidation and antioxidant enzyme levels. Data are mean  $\pm$  SEM; a\*  $p < 0.05$ , compared with the control; b\* and c\* indicate significant difference at  $p < 0.05$  compared with the ulcer control

### Effect of *Alpinia conchigera* extract on rat cytokine levels

Treatment with HCL/ethanol produced significant increases in levels of gastric inflammatory cytokines TNF- $\alpha$ , IL-1 $\beta$ , and IL-6 (Figure 4). However, *A. conchigera*-treated rats showed decreased gastric levels of these cytokines, when compared to HCL/ethanol-treated animals.



**Figure 4:** The effects of *Alpinia conchigera* on proinflammatory cytokine levels. All values are expressed as mean  $\pm$  standard error of the mean; a\*  $p < 0.05$  compared with the control; b\* and c\* indicate significant difference at  $p < 0.05$  compared with ulcer control

## DISCUSSION

Gastric injury induced by ethanol is a popular experimental model for the assessment of preclinical studies on potential anti-ulcer effects [13]. Plant extracts are the most attractive sources of new drugs, and have produced

promising outcome for the gastric ulcer treatment in numerous experimental models. Numerous phytonutrients and herbal extracts meet the increasing demand for therapeutic drugs in the pharmaceutical industry. Gastric mucosa plays an important role in the defense of gastric wall from damaging factors through formation of a barrier against these agents [14]. In this study, ulcer index scores were high in the gastric ulcer control rats, but the lesion scores were decreased in the herbal drug-treated rats. Mucosal integrity essentially offers shelter to the inner muscular and glandular layers of stomach wall. Treatment with *A. conchigera* not only protected the gastric mucosa, but also facilitated in the regeneration of the damaged regions, thereby exerting cytoprotective effects.

Free radicals are generated as by-products of exogenous factors or biological reactions. Several enzymatic and non-enzymatic antioxidants such as SOD, CAT, GPx, GSH and sulfhydryl groups scavenge reactive oxygen species (ROS); they serve as first line cellular defenses in gastric cells. Extreme generation of ROS causes increased LPO, leading to suppression of antioxidant enzyme activities [16]. The SOD enzyme converts the highly reactive superoxide anion into H<sub>2</sub>O<sub>2</sub>, which is in turn degraded to water by GPx and CAT.

Indomethacin, a non-steroidal analgesic and anti-inflammatory drug, has been reported to reduce the levels of GSH, SOD, and CAT [17]. In gastric tissues, alcohol is linked to oxidative stress; it enhances LPO which arises through increased MDA formation and decreased GSH levels [18]. A previous study showed that manassantin A pretreatment inhibited LPO, increased mucosal GSH, and enhanced activities of SOD and CAT, prior to ethanol-induced acute gastric lesion in a rat model [19]. In the current study, *A. conchigera* significantly preserved the levels of SOD and CAT in the gastric tissues of experimental rats, indicating its cytoprotective effect.

In addition to generation of ROS, administration of ethanol induces an inflammatory response, releasing various inflammatory cytokines such as TNF- $\alpha$ , IL-6, and IL-1 $\beta$  [20]. During inflammation, macrophages secrete inflammatory cytokines [21]. This decreases the gastric microcirculation adjacent to an ulcer site, causing delayed healing of the ulcer [22]. In peptic ulcer, high concentrations of IL-6 triggers release of neutrophils, monocytes/macrophages and lymphocytes at the site of inflammation, leading to increased toxic metabolites, oxidative bursts, and lysosomal enzymes all of which damage

surrounding tissues [23]. Studies have shown that IL-1 $\beta$  plays an important role in systemic acute-phase reactions, and also in the release of additional members of the pro-inflammatory cytokines such as TNF- $\alpha$ , platelet activating factor (PAF), prostaglandins (PGs), and ILs [24]. A previous study showed that manassantin A pretreatment reversed the mucosal mRNA expressions of TNF- $\alpha$ , IL-6, and IL-1 $\beta$  in ethanol-induced gastric ulcer in rats [25].

## CONCLUSION

The present study has established the gastroprotective and ulcer-healing effects of *A. conchigera* extract in a rat model of HCL/ethanol-induced gastric ulcer. The gastroprotective and ulcer-healing properties occur via a mechanism involving mitigation of oxidative stress and inflammation.

## DECLARATIONS

### Conflict of interest

No conflict of interest is associated with this work.

### Contribution of authors

We declare that this work was done by the authors named in this article and all liabilities pertaining to claims relating to the content of this article will be borne by the authors.

### Open Access

This is an Open Access article that uses a funding model which does not charge readers or their institutions for access and distributed under the terms of the Creative Commons Attribution License (<http://creativecommons.org/licenses/by/4.0>) and the Budapest Open Access Initiative (<http://www.budapestopenaccessinitiative.org/read>), which permit unrestricted use, distribution, and reproduction in any medium, provided the original work is properly credited.

## REFERENCES

1. Kwiecień S, Brzozowski T, Konturek PC, Pawlik MW, Pawlik WW, Kwiecień N, Konturek SJ. Gastroprotection by pentoxifylline against stress-induced gastric damage. Role of lipid peroxidation, antioxidizing enzymes and proinflammatory cytokines. *J Physiol Pharmacol* 2004; 55(2): 337-355.
2. Kwiecień S, Brzozowski T, Konturek SJ. Effects of reactive oxygen species action on gastric mucosa in various models of mucosal injury. *J Physiol Pharmacol* 2002; 53: 39-50.
3. Kwiecień S, Brzozowski T, Sliwowski Z. Helicobacter pylori infection in experimental model of ischemia-reperfusion induced gastric mucosa damage. *Gastroenterol Po* 2001; 8: 111-125.
4. Watanabe T, Higuchi K, Tanigawa T, Fujiwara Y, Arakawa T. Mechanisms of peptic ulcer recurrence: role of inflammation. *Inflammopharmacol* 2002; 10:291-302.
5. Zakaria ZA, Balan T, Suppaiah V, Ahmad S, Jamaludin F. Mechanism(s) of action involved in the gastroprotective activity of *Muntingia calabura*. *J Ethnopharmacol* 2014; 151(3): 1184-1193.
6. Athamaprasangsa S, Buntrarongroj U, Dampawan P, Ongkavoranan P, Rukachaisirikul V, Sethijinda S, Sornnarindra M, Sriwub P, Taylor WC. A 1,7-diarylheptanoid from *Alpinia conchigera*. *Phytochem* 1994; 37: 11-14.
7. Yu J, Fang H, Chen Y, Yao Z. Identification of the chemical components of two *Alpinia* species. *Zhongyao Tongbao* 1988; 13: 132-135.
8. Araújo Pinho FVS, Coelho-de-Souza AN, Morais SM, Ferreira Santos C, Leal-Cardoso JH. Antinociceptive effects of the essential oil of *Alpinia zerumbet* on mice. *Phytomed* 2005; 12: 51-56.
9. Esra K, Nurgun H, Erdem JR, Bilge HB. Anti-inflammatory and antinociceptive activity of taxoids and lignans from the heartwood of *Taxus baccata* L. *J Ethnopharmacol* 2003; 89: 83-89
10. National Research Council. *Guide for the care and use of laboratory animals*. 2011; National Academies Press.
11. Oyagi A, Ogawa K, Kakino M, Hara H. Protective effects of a gastrointestinal agent containing Korean red ginseng on gastric ulcer models in mice. *BMC Complement Altern Med* 2010; 10: 45.
12. Arambewela LS, Arawwawala LD, Ratnasooriya WD. Antinociceptive activities of aqueous and ethanolic extracts of *Alpinia calcarata* rhizomes in rats. *J Ethnopharmacol* 2004; 95(2-3): 311-316.
13. Liu Y, Tian X, Gou L, Fu X, Li S, Lan N, Yin X. Protective effect of L-citrulline against ethanol-induced gastric ulcer in rats. *Environ Toxicol Pharmacol* 2012; 34(2): 280-287.
14. Hills BA. Gastric mucosal barrier: evidence for *Helicobacter pylori* ingesting gastric surfactant and deriving protection from it. *Gut* 1933; 34(5): 588-593.
15. Dengiz GO, Odabasoglu F, Halici Z, Cadirci E, Suleyman H. Gastroprotective and antioxidant effects of montelukast on indomethacin-induced gastric ulcer in rats. *J Pharmacol Sci* 2007; 105(1): 94-102.
16. Zakaria ZA, Balan T, Suppaiah V, Ahmad S, Jamaludin F. Mechanism(s) of action involved in the gastroprotective activity of *Muntingia calabura*. *J Ethnopharmacol* 2014; 151(3): 1184-1193.
17. Nasri H, Baradaran A, Shirzad H, Rafieian-Kopaei M. New concepts in nutraceuticals as alternative for pharmaceuticals. *Int J Prev Med* 2014; 5(12): 1487-1499.

18. Athamaprasangsa S, Buntrarongroj U, Dampawan P, Ongkavoranan P, Rukachaisirikul V, Sethijinda S, Sornnaritra M, Sriwub P, Taylor WC. A 1,7-diarylheptanoid from *Alpinia conchigera*. *Phytochem* 1994; 37: 153-157.
19. Song JW, Seo CS, Kim TI, Moon OS, Won YS, Son HY, Son JK, Kwon HJ. Protective Effects of Manassantin A against Ethanol-Induced Gastric Injury in Rats. *Biol Pharm Bull* 2016; 39(2): 221-229.
20. Salga MS, Ali HM, Abdulla MA, Abdelwahab SI. Gastroprotective activity and mechanism of novel dichlorido-zinc(II)-4-(2-(5-methoxybenzylideneamino)ethyl)piperazin-1-iumphenolate complex on ethanol-induced gastric ulceration. *Chem Biol Interact* 2012; 195(2): 144-153.
21. Rozza AL, Meira de Faria F, Souza Brito AR, Pellizzon CH. The gastroprotective effect of menthol: involvement of anti-apoptotic, antioxidant and anti-inflammatory activities. *PLoS One* 2014; 9(1): e86686.
22. Abdelwahab SI. Protective mechanism of gallic acid and its novel derivative against ethanol-induced gastric ulcerogenesis: Involvement of immunomodulation markers, Hsp70 and Bcl-2-associated X protein. *Int Immunopharmacol* 2013; 16(2): 296-305.
23. Mei X, Xu D, Xu S, Zheng Y, Xu S. Novel role of Zn(II)-curcumin in enhancing cell proliferation and adjusting proinflammatory cytokine-mediated oxidative damage of ethanol-induced acute gastric ulcers. *Chem Biol Interact* 2012; 197(1): 31-39.
24. Dinarello CA. A clinical perspective of IL-1beta as the gatekeeper of inflammation. *Eur J Immunol* 2011; 41(5): 1203-1217.
25. Kim JY, Kang JS, Kim HM, Kim YK, Lee HK, Song S, Hong JT, Kim Y, Han SB. Inhibition of phenotypic and functional maturation of dendritic cells by manassantin a. *J Pharmacol Sci* 2009; 109(4): 583-592.