

## Original Research Article

# Evaluation of L-carnitine in an animal model of cholesterol-induced atherosclerosis

Mehran Bahrami-Bukani<sup>1</sup>, Leila Zarei<sup>2\*</sup>, Ata Abbasi<sup>3</sup>, Negin Farhad<sup>1</sup>, Hawdam Rostami<sup>4</sup>, Ali Mehrshad<sup>5</sup>

<sup>1</sup>Student Research Committee, <sup>2</sup>Solid Tumor Research Center, <sup>3</sup>Department of Pathology, Urmia University of Medical Sciences, <sup>4</sup>Department of Surgery and Diagnostic Imaging, Faculty of Veterinary Medicine, Urmia University, <sup>5</sup>Department of Clinical Sciences, Faculty of Veterinary Medicine, Urmia Branch, Islamic Azad University, Urmia, Iran

\*For correspondence: **Email:** leilazarei652@yahoo.com; **Tel:** +98-9368203813

Sent for review: 8 September 2017

Revised accepted: 2 August 2019

### Abstract

**Purpose:** To explore the effect of L-carnitine on atherosclerotic plaques in hyperlipidemic rabbits.

**Methods:** Twenty five male white New Zealand rabbits were randomized into five groups (n = 5): In the normal control (NC) group, the animals were fed on a plain chow diet for 75 days. In atherosclerosis (AS) group, the animals were fed on a hypercholesterolemic diet for 75 days. In atorvastatin (ATOR) group, the animals were fed on a hypercholesterolemic diet for 75 days and received atorvastatin via oral gavage (20 mg/kg/day) from day 45 for 30 days. In L-carnitine (L) group, the animals were fed on a hypercholesterolemic diet for 75 days and received intraperitoneal L-carnitine (250 mg/kg/day) from day 45 for 30 days (end of the study). In ATOR/L group, the animals were fed on a hypercholesterolemic diet for 75 days, and received both atorvastatin and L-carnitine with the aforementioned dosage from day 45 for 30 days. Triglycerides (TG), total cholesterol (TC), high-density lipoprotein (HDL) and low-density lipoprotein (LDL-C) in sera were determined. The aorta, including the ascending and descending parts, was excised to measure plaque size (end of the study). The blood samples were taken from a marginal ear vein.

**Results:** Rabbits in AS group showed highly significant increase in serum total cholesterol and LDL-C levels compared to NC group (p < 0.05). Daily administration of L-carnitine significantly reduced serum levels of total cholesterol and LDL-C compared to AS (positive control) group (p < 0.05). Additionally, no significant difference was found between serum levels of total cholesterol and LDL-C in groups that received either atorvastatin or L-carnitine (p > 0.05). Combined administration of L-carnitine and atorvastatin produced no benefits over either of them alone (p > 0.05).

**Conclusion:** The results indicate that the administration of L-carnitine has anti-atherosclerotic effects by reducing oxidized LDL cholesterol levels but further investigations are recommended to ascertain these findings.

**Keywords:** L-Carnitine, Cholesterol, Atherosclerosis, Atorvastatin, Hypercholesterolemic diet

This is an Open Access article that uses a fund-ing model which does not charge readers or their institutions for access and distributed under the terms of the Creative Commons Attribution License (<http://creativecommons.org/licenses/by/4.0>) and the Budapest Open Access Initiative (<http://www.budapestopenaccessinitiative.org/read>), which permit unrestricted use, distribution, and reproduction in any medium, provided the original work is properly credited.

Tropical Journal of Pharmaceutical Research is indexed by Science Citation Index (SciSearch), Scopus, International Pharmaceutical Abstract, Chemical Abstracts, Embase, Index Copernicus, EBSCO, African Index Medicus, JournalSeek, Journal Citation Reports/Science Edition, Directory of Open Access Journals (DOAJ), African Journal Online, Bioline International, Open-J-Gate and Pharmacy Abstracts

## INTRODUCTION

It is believed that a sequence of highly specific cellular and molecular responses of the

endothelium to atherogenic factors leads to atherosclerosis [1]. Formation and progression of atherosclerosis is a long-term process which begins with accumulation of fat within vessel

walls. Fat accumulation triggers an inflammatory process as well as platelet activation and accumulation which subsequently lead to formation of an atherosclerotic plaque [2-4]. This pathway is boosted by risk factors like hypercholesterolemia, hypertension, Diabetes mellitus (DM), smoking, vascular endothelial injury, decreased nitric oxide bioactivity and/or synthesis, lipid peroxidation, amplified platelet aggregation, inflammation and genetic alterations through increased adhesiveness of endothelium, accumulation of mononuclear cells, migration and proliferation of smooth muscle cells that result in plaque cell formation that would probably cause thickening of the vessel wall [2,3]. It is believed that the main initial treatment approach for managing and/or preventing progression of atherosclerosis and its pathological consequences is decreasing the atherogenic factors. In this regard, several agents were examined including L-carnitine and its natural short chain derivative propionyl-L-carnitine [4].

L-carnitine, a naturally occurring quaternary ammonium compound, is responsible for carrying the activated long-chain fatty acids from cytoplasmic compartment into mitochondria in which beta-oxidation enzymes are located [5]. It is believed that L-carnitine is a therapeutic agent to treat hyperlipidemia based on its involvement in fatty acid metabolism [6]. According to the applied hyperlipidemia in rat models, L-carnitine was capable of reducing the synthesis of VLDL by promotion of beta-oxidation and increasing the hepatic level of fatty acid binding proteins [7,8]. Studies show that the lipid-lowering effect of L-carnitine could be due to reduced VLDL-TG transport [9]. Other studies argue that L-carnitine influences cholesterol metabolism by repressing 3-hydroxy-3-methyl-glutaryl-CoA reductase activity with increasing LDL binding [10]. It has been reported that carnitine deficiency is significantly involved in pathophysiology of cardiovascular diseases [11,12].

Therefore, this study was conducted to investigate the beneficial effects of intraperitoneal administration of L-carnitine on the development of atherosclerosis in hyperlipidemic rabbits.

## EXPERIMENTAL

### Study design and animals

Male white New Zealand rabbits, 3 – 4 months old and weighing 2.0 – 2.5 kg were selected. They were divided randomly into five experimental groups (n = 5). In normal control

(NC) group, the animals were fed on a plain chow diet (Super Fosskorn, Dam Pars Co., Tehran, Iran) for 75 days. In atherosclerosis (AS) group, the animals were kept on a hypercholesterolemic diet (2 % cholesterol) for 75 days. In atorvastatin (ATOR) group, the animals were fed on hypercholesterolemic diet for 75 days and received atorvastatin via oral gavage (20 mg / kg / day) from day 45 for 30 days (end of the study) [13]. In L-carnitine (L) group, the animals were kept on hypercholesterolemic diet for 75 days and intraperitoneal L-carnitine (250 mg / kg / day) was administered from day 45 for 30 days [14]. In ATOR/L group the animals were kept on hypercholesterolemic diet for 75 days, and received atorvastatin and L-carnitine as mentioned above from day 45 for 30 days.

The animals were housed in individual plastic cages with an ambient temperature of (23 ± 3) ° C, stable air humidity and a 12:12 h light:dark cycle . The rats had free access to standard rodent laboratory food and tap water. All measurements were made by two observers unaware of the analyzed groups. All animal procedures were in accordance with guide for the care and use of laboratory animals (NIH US publication no. 85–23 revised 1985) [15]. All experiments were performed in agreement with the ethical considerations, recommended by the Pasteur Institute of Iran and the study protocol was reviewed and approved by the Ethical Committee of Urmia University of Medical Sciences [ir.Umsu.rec.1395.115]. L-carnitine and cholesterol were bought from Sigma (St. Louis, USA). All the used chemicals were of the highest analytical grade.

### Induction of hypercholesterolemia in rabbits

To induce hypercholesterolemia, rabbits were fed with 2 % cholesterol-enriched fat diet for 75 days following the method described earlier [16]. To prepare the diet, the plain chow pellets were spray coated with cholesterol along with acetone, ethyl alcohol, PVP, acetyl alcohol and carbowax as solvent and binding agents [14].

### Histopathological studies of aorta

The aorta including ascending and descending parts was excised from its base and totally immersed in phosphate buffered formalin (PBF) for at least 24 h for fixation in 10 % neutral-buffered formalin. After fixation the samples were embedded in paraffin. Then 5 µm sections were obtained from each paraffin block and stained with Hematoxylin and Eosin (H&E). After microscopic evaluation of the sections, the

images from the best areas were captured under light microscopy. Maximum intima thickness (plaque size) of each sample was measured using an image evaluation program (Optika, Italy) and compared with others.

### Assessment of serum biochemistry profile

At the end of the experiment, the rabbits were fasted for 12 h prior to anesthesia (combination of ketamine-xylazine) and peripheral blood samples were obtained from the marginal vein of their ear. To separate the serum samples, they were centrifuged at 3500 rpm for 10 min. Next, analysis was carried out to determine triglycerides (TG), total cholesterol (TC), high density lipoprotein (HDL) and low density lipoprotein (LDL-C) in serum using manufacturers' kits (Pars Azmoon, Iran).

### Statistical analysis

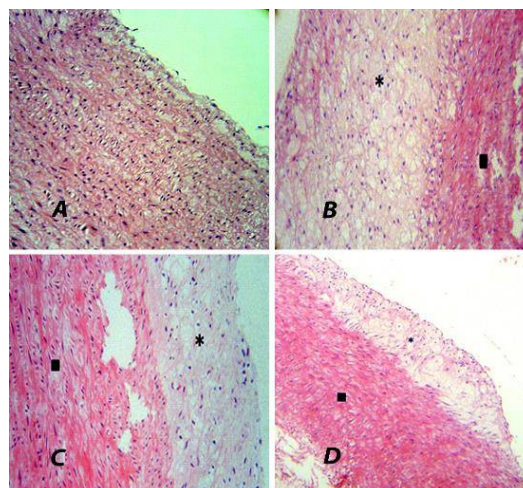
The results are expressed as mean  $\pm$  standard error of the mean (SEM). Statistical analysis was performed using SPSS version 16.0 (SPSS Inc., Chicago, IL, USA) and analysis of variance (ANOVA). Normality of data was evaluated with Kolmogorov–Smirnov test. P-values  $< 0.05$  were considered statistically significant.

## RESULTS

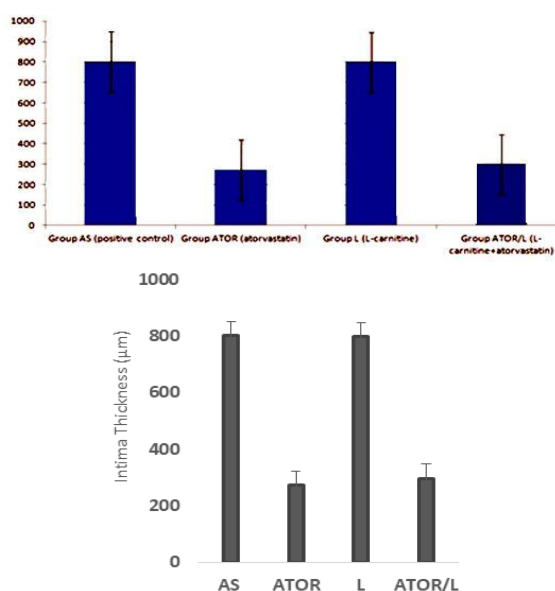
### Histopathological findings

Figure 1 A shows the histopathological examination of aorta obtained from NC group. The aorta wall revealed uniform thickness with no bulging in the lumen and the endothelial lining was complete with no irregularities. Furthermore, elastic lamina and muscle fibers were regular. In contrast, rabbits receiving cholesterol-enriched diet displayed atherosclerotic lesions with noticeable irregularities in the aortic wall (Figure 1 B). Magnifying these plaques displayed endothelial gaps with accumulated foam cells in sub-endothelial layer. The results showed that the administration of L-carnitine did not decrease the size of plaques comparing to the control group (Figure 1 C), but atorvastatin significantly decreased their size (Figure 1 D).

Furthermore, combination therapy of L-carnitine and atorvastatin (ATOR/L group) showed no advantages over using atorvastatin alone and the plaques size in these two groups (ATOR/L group vs ATOR group) was not different ( $p > 0.05$ ), (Figure 2).



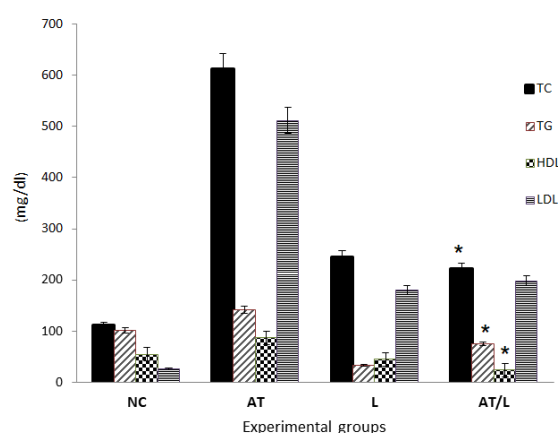
**Figure 1:** **A:** Section of a normal aorta without any atheroma plaque. **B:** Section of aorta of atherosclerotic rabbit that received high fat diet for 75 days without any medication. A large atherosclerotic plaque is seen containing foamy macrophages (area shown by \*) attached to muscular layer of aorta (shown by black square). **C:** Section of aorta of atherosclerotic rabbit received L-carnitine along with high fat diet. A large atherosclerotic plaque (area shown by \*) is seen containing foamy macrophages attached to muscular layer of aorta (muscle layer is shown by black square). No obvious reduction is seen in the plaque size compared to B. **D:** Section of aorta of atherosclerotic rabbit received atorvastatin along with high fat diet. A small atherosclerotic plaque (area shown by \*) is seen attached to muscular layer of aorta (shown by black square). The smaller size of the attached plaque is obvious compared to B, C. (H&E staining, x 20).



**Figure 2:** Aortic intima thickness in examined rabbits. Intima thickness analysis showed that L-carnitine did not reduce the plaque size comparing to positive controls. The Figure shows that atorvastatin can reduce atherosclerotic plaque size effectively ( $p < 0.05$ ) and subsequently the aortic intimal thickness.

## Serum profile

Rabbits in AS group showed highly significant increase in serum total cholesterol and LDL-C levels compared to NC group ( $p < 0.05$ ). Daily administration of L-carnitine significantly reduced serum levels of total cholesterol and LDL-C compared to AS (positive control) group ( $p < 0.05$ ). Additionally, no significant difference was found between serum levels of total cholesterol and LDL-C in groups that received either atorvastatin or L-carnitine ( $p > 0.05$ ). Combined administration of L-carnitine and atorvastatin produced no benefits over using each of them alone ( $p > 0.05$ ), (Figure 3). No statistical difference was found between serum levels of TG and HDL in the examined groups (Figure 3).



**Figure 3:** Serum concentration of triglyceride (TG), total cholesterol (TC), high-density lipoprotein (HDL) and low-density lipoprotein (LDL-C) in the examined groups. The graph shows that LDL and TC levels significantly decreased after the administration of L-carnitine. Atorvastatin as a main anti-lipemic drug has also reduced serum LDL and TC levels. There is no statistically significant difference between serum levels of HDL and TG in examined groups

## DISCUSSION

The purpose of the present study was to evaluate the effects of L-carnitine administration on atherosclerotic plaques in a rabbit model of atherosclerosis. Rabbits are very similar to human in many aspects including lipoprotein metabolism which makes them excellent models to assess various aspects of lipoproteins metabolism and atherosclerosis [17,18].

In this model, it was showed that although L-carnitine reduced serum levels of TC and LDL-C, unlike previous studies, it had no significant effect on atherosclerotic plaques and did not reduce the plaque sizes [19,20].

It has been shown that L-carnitine is a crucial cofactor for mitochondrial transportation and oxidation of long chain fatty acids, which are the favorite substrate to produce ATP in adult myocardium of vascular endothelial and smooth muscle cells [21,22]. This would be the reason why vessels are found to be susceptible for alteration of serum L-carnitine level. Former studies reported a close link between L-carnitine deficiency and numerous forms of cardiovascular disorders [12,23], and cardiac function was enhanced by administrating L-carnitine supplements in many cases [4,5,24], but some controversies do exist. There are new studies reporting against the protective effects of carnitine on atherosclerosis and some of them have even introduced adverse effects [25]. Thus, to explore this relationship, the current study has tried to show if administrating L-carnitine would inhibit the development of atherogenesis in rabbit model of high fat induced atherosclerosis. Under our experimental conditions, 35-day treatment with L-carnitine did not prevent the progression of atherosclerotic lesions which were clearly shown in aorta of hypercholesterolemic rabbits. Earlier, it was shown that administrating L-carnitine inhibited the progression of early atherosclerotic lesions through reduction of plasma cholesterol and triglyceride levels, and decreasing the extent of liver steatosis [4]; however, this issue is questioned by new studies suggesting that L-carnitine and its intermediary products are capable of accelerating atherosclerosis [25]. Our results are in line with recent studies showing that L-carnitine does not have any significant effect on reducing atherosclerotic plaques size.

Results of this study, in line with the present controversial findings, warrant establishing new studies to monitor the effects of carnitine and its intermediary metabolites on various aspects of atherosclerosis.

## CONCLUSION

Overall, we showed that L-carnitine administration could reduce serum levels of LDL-C and TC, but it was not effective on atherosclerotic plaques and the plaques size was not decreased after L-carnitine administration. Our results do not support the previous reports showing anti-atherosclerosis effects of L-carnitine. According to our results, the use of L-carnitine is recommended not as the main anti-atherosclerotic drug in the treatment of atherosclerotic patients, but as a supplementary medication to control serum levels of LDL-C and total cholesterol in these patients.

## DECLARATIONS

### Acknowledgement

The authors appreciate the support by Vice-Chancellor of Research Center at Urmia University of Medical Sciences.

### Conflict of interest

No conflict of interest is associated with this work.

### Contribution of authors

We declare that this work was done by the authors named in this article and all responsibilities pertaining to claims relating to the content of this article will be borne by the authors. Mehran Bahrami-Bukani: Conducted the experiments, acquisition of data, analysis and interpretation of data. Leila Zarei: The conception and design of the study, analysis and interpretation of data, drafting the article and revising it critically for important intellectual content. Ata Abbasi: Analysis and interpretation of data and revising the manuscript for important intellectual content. Negin Farhad: Conducting the experiments and acquisition of data. Hawdam Rostami: Acquisition of data, analysis and interpretation of data. Ali Mehrshad: Conducting the experiments, acquisition of data and revising the manuscript for important intellectual content.

### Open Access

This is an Open Access article that uses a funding model which does not charge readers or their institutions for access and distributed under the terms of the Creative Commons Attribution License (<http://creativecommons.org/licenses/by/4.0>) and the Budapest Open Access Initiative (<http://www.budapestopenaccessinitiative.org/read>), which permit unrestricted use, distribution, and reproduction in any medium, provided the original work is properly credited.

## REFERENCES

- Ross R. *The pathogenesis of atherosclerosis: a prospective of the 1990s*. *Nature* 1993; 6423: 801–809.
- Tsao PS, Cooke JP. *Endothelial alterations in hypercholesterolemia: more than simply vasodilator dysfunction*. *J Cardiovasc Pharmacol* 1997; 32: S48–553.
- Ross R. *Mechanism of disease: atherosclerosis-an inflammatory disease*. *New Engl J Med* 1999; 340: 115–126.
- Secombe DW, James L, Hahn P, Jones E. *L-carnitine treatment in the hyperlipidemic rabbit*. *Metabolism* 1987; 36: 1192–1196.
- Spagnoli LG, Orlandi A, Mauriello A, De Angelis C, Ramacci MT. *Propionyl-L-carnitine prevents the progression of atherosclerotic lesions in aged hyperlipemic rabbits*. *Atherosclerosis* 1995; 114: 29–44.
- Flanagan JL, Simmons PA, Vehige J, Willcox MD, Garrett Q. *Role of carnitine in disease*. *Nutrition & metabolism* 2010; 7(1): 30.
- Maccari F, Pessotto P, Ramacci MT, Angelucci L. *The effect of exogenous L-carnitine on fat diet-induced hyperlipidemia in the rat*. *Life Sci* 1985; 36: 1967–1975.
- Maccari F, Arseni A, Chiodi P, Ramacci MT, Angelucci L, Hulsmann WC. *L-carnitine effect on plasma lipoproteins of hyperlipidemic fat-loaded rats*. *Lipids* 1987; 22: 1005–1008.
- James L, Bhuiyan AJ, Foster D, Secombe D. *Effect of L-carnitine treatment on very low density lipoprotein kinetics in the hyperlipidemic rabbit*. *Clin Biochem* 1995; 28: 451–458.
- Mondola P, Santillo M, De Mercato R, Santangelo F. *The effect of L-carnitine on cholesterol metabolism in rat (Rattus bubalus) hepatocyte cells*. *Int J Biochem* 1992; 24: 1047–1050.
- Paulson DJ, Traxler J, Schmidt M, Noonan J, Shug AL. *Protection of the ischemic myocardium by L-propionylcarnitine: effects on the recovery of cardiac output after ischemia and reperfusion, carnitine transport, and fatty acid oxidation*. *Cardiovasc Res* 1986; 20: 536–541.
- Paulson DJ. *Carnitine deficiency-induced cardiomyopathy*. *Mol Cell Biochem* 1998; 180: 33–41.
- Zarei L, Bahrami M, Farhad N, Froushani SM, Abbasi A. *All-trans retinoic acid effectively reduces atheroma plaque size in a rabbit model of high-fat-induced atherosclerosis*. *Advances in clinical and experimental medicine: official organ Wroclaw Medical University* 2018.
- Sayed-Ahmed MM, Khattab MM, Gad MZ, Mostafa N. *L-carnitine prevents the progression of atherosclerotic lesions in hypercholesterolaemic rabbits*. *Pharmacological Research* 2001; 44(3): 235-42.
- National Research Council. *Guide for the care and use of laboratory animals*. *National Academies Press*; 2010 Dec 27.
- Kolodgie FD, Katocs AS, Largis EE, Wrenn SM, Cornhill JF, Herderick EE, Lee SJ, Virmani R. *Hypercholesterolemia in the rabbit induced by feeding graded amounts of low-level cholesterol: methodological considerations regarding individual variability in response to dietary cholesterol and development of lesion type*. *Arterioscler Thromb Vasc Biol* 1996; 16: 1454-1464.

17. Corseaux D, Meuride T, Six I, Rugeri L, Ezekowitz MD, Rouvier P, Bordet R, Bauters C, Jude B. Basic fibroblast growth factor increases tissue factor expression in circulating monocytes and in vascular wall. *Circulation* 2000; 101: 2000-2006.
18. Abela GS, Picon PD, Friedl SE, Gebara OC, Miyamoto A, Federman M, Tofler GH, Muller JE. Triggering of plaque disruption and arterial thrombosis in an atherosclerotic rabbit model. *Circulation* 1995; 91: 776-784.
19. Lee BJ, Lin JS, Lin YC, Lin PT. Effects of L-carnitine supplementation on lipid profiles in patients with coronary artery disease. *Lipids in health and disease* 2016; 15(1):107.
20. Zhao Y, Yang N, Gao J, Li H, Cai W, Zhang X, Ma Y, Niu X, Yang G, Zhou X, Li Y. The Effect of Different L-Carnitine Administration Routes on the Development of Atherosclerosis in ApoE Knockout Mice. *Molecular nutrition & food research* 2018; 62(5): 1700299.
21. Neely JR, Morgan HE. Relationship between carbohydrate and lipid metabolism and the energy balance of heart muscle. *Annu Rev Physiol* 1974; 36: 413-459.
22. Hulsmann WC, Dubelaar ML. Carnitine in metabolism of paced cardiac and skeletal muscles: prevention of acidosis and improvement of vascular flow. In: Ferrari R, Dimauro S, Sherwood G: editors. *L-carnitine and its role in medicine: from function to therapy*. London: Academic Press Limited; 1992. p. 345-358.
23. Regitz-Zagrosek V, Fleck E. Myocardial carnitine deficiency in human cardiopathia. In: De Jong JW, Ferrari R: editors. *The carnitine system – A new therapeutical approach to cardiovascular diseases*. Dordrecht: Kluwer Academic Publishers; 1995. p. 145-166.
24. Hiatt WR, Nawaz D, Brass EP. Carnitine metabolism during exercise in patients with peripheral vascular disease. *J Appl Physiol* 1987; 62: 2383-2387.
25. Koeth RA, Levison BS, Culley MK, Buffa JA, Wang Z, Gregory JC, Org E, Wu Y, Li L, Smith JD, et al.  $\gamma$ -Butyrobetaine is a proatherogenic intermediate in gut microbial metabolism of L-carnitine to TMAO. *Cell Metab* 2014; 20: 799-812.