

Original Research Article

Effect of doxycycline-bioglass treatment on calvarial bone defect in rats: A histological study

Mona Mokhtarian¹, Mohammad Reza Nourani², Nasrin Esfahanizadeh^{1*}

¹Department of Periodontics, Islamic Azad University of Tehran, Faculty of Dentistry, ²Division of Tissue Engineering, Nanobiotechnology Research Center, Baqiyatallah University of Medical Sciences, Tehran, Iran

*For correspondence: **Email:** n_esfahanizadeh@yahoo.com; **Tel:** +98-912-2156687

Sent for review: 14 January 2020

Revised accepted: 18 May 2020

Abstract

Purpose: To evaluate the osteogenic properties of a bioglass-doxycycline complex for bone regeneration applications in calvarial bone defects in rats.

Methods: Three critical-size bone defects were created in each of eight experimental rats using a trephine bur. The experimentally created defects were then filled with bioglass-doxycycline (BG-D group), bioglass alone (BG group), or left unfilled (control group). Four randomly selected rats were sacrificed after 4 weeks while the other four rats were sacrificed after 8 weeks. The amount of newly regenerated bone and the osteoblast and osteoclast counts were calculated using histological analysis.

Results: Increase in the amount of regenerated bone was significant in the bioglass-doxycycline group at both 4 and 8 weeks ($p < 0.05$). Differences between the three groups in the mean number of osteoblasts were also significant at both 4 and 8 weeks ($p < 0.05$). Comparison of the three groups revealed significant increase in osteogenesis rate and considerable enhancement of the number of osteoblasts in both bioglass and bioglass-doxycycline groups ($p < 0.05$).

Conclusion: The complex of doxycycline and bioglass increased the rate of osteogenesis and number of osteoblasts in rats but decreased the number of osteoclasts. Therefore, bioglass-doxycycline can be considered as a bone graft in bone regeneration for medical applications.

Keywords: Bone, Regeneration, Osteoblasts, Osteoclasts, Osteogenesis, Bioglass, Doxycycline

This is an Open Access article that uses a fund-ing model which does not charge readers or their institutions for access and distributed under the terms of the Creative Commons Attribution License (<http://creativecommons.org/licenses/by/4.0>) and the Budapest Open Access Initiative (<http://www.budapestopenaccessinitiative.org/read>), which permit unrestricted use, distribution, and reproduction in any medium, provided the original work is properly credited.

Tropical Journal of Pharmaceutical Research is indexed by Science Citation Index (SciSearch), Scopus, International Pharmaceutical Abstract, Chemical Abstracts, Embase, Index Copernicus, EBSCO, African Index Medicus, JournalSeek, Journal Citation Reports/Science Edition, Directory of Open Access Journals (DOAJ), African Journal Online, Bioline International, Open-J-Gate and Pharmacy Abstracts

INTRODUCTION

Regeneration of bone defects is a challenging topic in dentistry [1]. Several factors such as type of tissue, defect location and position, number of blood vessels, microbial status, and other local and systemic factors affect the process of wound healing [2,3]. Different types of grafts have been suggested for reconstruction and regeneration of

periodontal bone defects including autografts, allografts, and xenografts [4].

At present, biomaterials, including bioglass, have found a pivotal role in bone regeneration applications. Bioglass has represented a growing popularity due to its antimicrobial, osteoinductive, and osteoconductive properties [2,4-5]. Bioglass is commonly used for coating the orthopedic implants in medicine and as a bone substitute in

periodontology and endodontics. It is also used as a scaffolding material in tissue engineering [6-8]. Available evidence shows that some medications such as tetracyclines and bisphosphonates and their combination can prevent bone resorption following periodontitis and promote the regeneration of bone defects by inducing osteogenesis.

Doxycycline is a structural isomer of tetracycline with antibacterial, immunosuppressive, anti-inflammatory, and anti-collagenase properties. Recently, the topical application of doxycycline has been confirmed to have treating effects on periodontitis and peri-implantitis [9-12]. Moreover, some recent studies demonstrated that doxycycline inhibits the production of osteoclasts. Since any bone manipulation in surgical procedures is shown to be able of activating osteoclasts, inhibition of their productions by tetracyclines is an advantage [3,4,10].

However, the simultaneous application of tetracyclines with bone grafts has shown controversial results. Some studies reported increased bone regeneration while some others reported no significant advantage for the application of a combination of tetracyclines and bone grafts for osteogenesis compared to bone grafting alone [4,6,13]. Due to the existing controversy concerning the effect of simultaneous application of tetracyclines and bone grafting on the rate of osteogenesis, and considering the gap in the information regarding the effect of applying bioglass-doxycycline complex on osteogenesis, here, the osteogenic properties of bioglass-doxycycline complex was studied for regenerating the calvarial bone defects in rats.

EXPERIMENTAL

Materials

Bioglass 45S5 (sterile) was purchased from Medzist Company (Tehran, Iran) and doxycycline powder was gifted from Hakim Pharmaceutical Company (Tehran, Iran).

Animals

This animal study was performed on eight adult male Wistar rats of 250 to 300 g weight. All animal experimental protocols were performed according to the Guide for the Care and Use of Laboratory Animals [14]. This study was approved by the Ethical Committee for Animal Research of Islamic Azad University of Tehran, Tehran, Iran (no. IR.IAU.DENTAL.REC.1395,2).

The animals were housed in cages with diurnal lighting on a 12:12 h light-dark cycle and controlled temperature conditions (22 ± 2 °C) and supplied with free access to standard food and water.

Animal surgery

The rats were anesthetized using a mixture of 60 mg/kg ketamine and 16 mg/kg xylazine. Their head fur was shaved and the exposed scalp was disinfected using povidone-iodine. After preparation, a longitudinal incision was created in the scalp and a flap was elevated to expose the calvaria. Then, three defects with the critical size of 5 mm in diameter were created in the calvaria bone of each rat using a trephine 5 mm diameter bur (Figure 1). The defects were located in the right, left, and center of the calvaria two of which were filled with bioglass-doxycycline (BG-D group) or standard bioglass (BG group) alone, and one was left unfilled (control group). The scalp was then sutured using 3-0 sutures.

After 4 weeks, four rats were randomly chosen and sacrificed while the remaining four were sacrificed after 8 weeks. The rats were sacrificed in a CO₂ chamber. Thereupon, the resected rats' calvaria pieces were fixed in 10% formalin. They were then decalcified, embedded in paraffin, and sectioned into 5 μm slices at the center of defects. Staining the tissue sections was performed using Masson's trichrome and Hematoxylin-Eosin protocols [15-21]. The stained tissue sections were inspected under a light microscope (Leica, Germany) at × 40 magnification. The newly formed bone was evaluated in each group using ImageJ software [5] and reported.

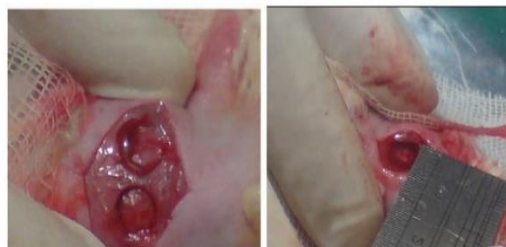

Figure 1: Defects were made on calvaria in both parietal bones

Statistical analysis

Data were analyzed using SPSS version 22 (SPSS Inc, IL, USA). The groups were compared using repeated-measures ANOVA. The significance of differences was analyzed by a

paired t-test and the level of significance was set at $p < 0.05$.

RESULTS

Qualitative histological findings

The margins of the calvarial bone and the defect site were evident at 4 weeks in the control group and no newly regenerated bone was observed in the calvarial bone tissue. However, the defect site was covered with a fibrous membrane in this group. In the BG group (that received the standard bioglass alone), the distance between the defect margins was filled with bioglass granules and the space between the granules was filled with connective tissue. A newly regenerated bone was observed around the granules and calvarial bone after 4 weeks. In the BG-D group (that received the bioglass-doxycycline), the defect margins were filled with granules and the connective tissue between the granules was more organized and the blood vessels were seen as well. The newly regenerated bone could be observed around the granules, and the bone trabecula had penetrated between the granules at 4 weeks (Figure 2).

In the 8-week rats, the control group represented an evident calvarial bone margin and defect site and the newly regenerated bone was seen in the calvarial bone tissue. The defect site was covered with a thicker fibrous membrane. In the BG group, the defect was filled with bioglass granules. The space between the granules was filled with a more organized connective tissue compared to the 4-week group. The newly regenerated bone was detected around the granules and adjacent to the calvarial bone. Bone trabecula was formed and penetrated through the granules and blood vessels were observed around the granules within the connective tissue. Compared to other groups, the rate of osteogenesis was higher in the BG-D group. Also, an organized connective tissue containing blood vessels and bone trabeculae filled the space of defect (Figure 2).

Histomorphometric features

Newly regenerated bone

The repeated measures ANOVA showed the rate of the new bone formation to be significantly different between the three groups at 4 ($p = 0.004$) and 8 weeks ($p = 0.004$). The maximum mean percentage of the new bone formation was seen in the BG-D group followed by the standard BG group and the control group at either 4 or 8 weeks (Table 1).

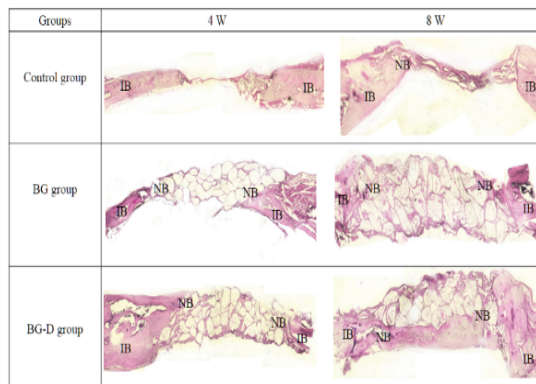


Figure 2: Histological features at 4 and 8 weeks; H & E $\times 40$). IB: Intact bone; NB: Newly regenerated bone; BG: bioglass; BG-D: bioglass-doxycycline

Table 1: Amount of newly regenerated bone in the study groups at 4 and 8 weeks (mean \pm SD)

Group	Duration		P-value
	4 weeks	8 weeks	
Doxycycline-bioglass	3.219 \pm 7.725	7.5 \pm 19.79	0.004
Bioglass	0.526 \pm 3/650	1.163 \pm 9.400	
Control	0.737 \pm 2.25	0.842 \pm 4.725	
P-value	0.004		

Number of osteoblasts

The three groups showed a significant difference in the number of osteoblasts at 4 ($P = 0.007$) and 8 weeks ($p = 0.001$). The maximum number of osteoblasts was considerable in the BG-D group compared to the BG and control groups at both 4 and 8 weeks (Table 2).

Table 2: Mean number of osteoblasts in the study groups at 4 and 8 weeks (mean \pm SD)

Group	Duration		P-value
	4 weeks	8 weeks	
Doxycycline-bioglass	9.878 \pm 23.75	74.534 \pm 176.00	0.007
Bioglass	2.500 \pm 12.25	40.468 \pm 140.50	
Control	0.000 \pm 0.000	5.737 \pm 15.250	
P-value	0.001		

Number of osteoclasts

Repeated measures ANOVA revealed that the three groups were not significantly different in terms of the number of osteoclasts at 4 ($p = 0.057$) or 8 weeks ($p = 0.189$). At 4 weeks, the maximum mean number of osteoclasts was higher in the BG-D group, followed by the BG group and the control group (Table 3), respectively. At 8 weeks, the mean number of

osteoclasts showed more decrease in the BG-D group compared to the BG group.

Table 3: Mean number of osteoclasts in the study groups at 4 and 8 weeks (mean \pm SD)

Group	Duration		P-value
	4 weeks	8 weeks	
Doxycycline-bioglass	1.826 \pm 2.000	1.500 \pm 1.250	0.057
Bioglass	0.957 \pm 0.750	4.933 \pm 5.500	
Control	0.000 \pm 0.000	0.500 \pm 0.250	
P-value	0.189		

Pairwise comparisons of the groups for the number of osteoblasts and rate of osteogenesis (new bone formation) using paired t-test are as follow. The results showed that the number of osteoblasts was considerably higher in BG-D and BG groups compared to the control group at both 4 and 8 weeks ($p < 0.05$). At 8 weeks, a significant increase was detected in the amount of new bone formation in the BG-D and BG groups compared to the control group ($p < 0.05$).

DISCUSSION

This study assessed the osteogenic properties of the bioglass-doxycycline complex in bone regeneration. Histological findings showed that the percentage of newly regenerated bone in defects filled with bioglass-doxycycline complex was significantly higher than that in other groups at either 4 or 8 weeks. Accordingly, Silva *et al* [4] assessed the efficacy of topical application of doxycycline gel for regeneration of bone defects in rats' calvaria. They found that at the end of week 8, the new bone formation rate in the BG-D group was significantly higher than in other groups. They concluded that doxycycline gel can effectively enhance bone formation in calvarial bone defects of rats. In the present study, the bioglass-doxycycline complex decreased the number of osteoclasts after 8 weeks more efficiently than 4 weeks.

Evidence shows that doxycycline inhibits the production of osteoclasts by decreasing RANKL [11,22]. It also prevents bone resorption due to its anti-collagenolytic and anti-proteolytic properties. It increases the chemotaxis of osteoblasts and leads to bone regeneration [23]. Soufdoost *et al* researched the novel Tadalafil/ β -TCP/collagen scaffold for bone regeneration and they found that Tadalafil/ β -TCP/collagen scaffold had better results in *in vitro* and *in vivo* tests compared to β -TCP/Collagen scaffold [5]. In an animal study, Gomes *et al* [24] evaluated the systemic doxycycline impact on the alveolar bone regeneration and the number of osteoblasts and osteoclasts. They found a complete tissue

remodeling and bone formation after 14 days in the doxycycline-treated group. Moreover, they reported a reduction in the number of osteoclasts and an increase in the number of osteoblasts in the groups treated with doxycycline after 7 and 14 days.

In the present study, the maximum number of osteoblasts was detected in the bioglass-doxycycline group at both 4 and 8 weeks that complied with their results. However, no reduction in the number of osteoclasts at 4 weeks was detected in the bioglass-doxycycline group compared to the bioglass and control groups. After 8 weeks, the mean number of osteoclasts showed more decline in the bioglass-doxycycline group than the bioglass group alone. The different results of the two studies can be possibly due to different assessment time points and different methods of doxycycline application.

Furthermore, Agarwal *et al* [23] compared the efficacy of decalcified freeze-dried bone allografts with and without topical doxycycline for regeneration of 16 infrabony defects in patients suffering from moderate to severe chronic periodontitis. They reported that the topical application of doxycycline accompanied by allografts did not show any greater efficacy for the regeneration of bone defects than using allograft alone. The difference in the results of the two studies may be due to differences in the study design, type of used graft materials, and type of bone defects.

Al-Ali *et al* [13] evaluated the effect of topical application of doxycycline with/without tri-calcium phosphate on the regeneration potential of periodontal defects in the alveolar bone of dogs. They reported an increase in the formation of new bone, cementum, and periodontal ligament, and a reduction in crystal bone resorption in doxycycline and doxycycline plus tricalcium phosphate received groups. The rate of regeneration was greater in doxycycline plus tricalcium phosphate group. They concluded that the combination of doxycycline with tricalcium phosphate results in faster and easier attachment of tricalcium phosphate to bone [13].

Also, positive effects have been confirmed for systemic administration of low-dose doxycycline on bone resorption. In an animal study, Yagan *et al* [10] demonstrated that the systemic administration of low-dose doxycycline for 21 days significantly decreased bone resorption compared to the no-medication received group (control). Zhou *et al* [11] evaluated the efficacy of tetracycline for preventing osteoclasts from formation and activity. They showed that the

number of osteoclasts in tetracycline and oxytetracycline groups significantly decreased in comparison with other groups. In the present study, the number of osteoclasts was reduced in the bioglass-doxycycline complex group; however, the difference between the three groups in this respect was not statistically significant. The difference between present results and foregoing studies may be due to the different methodologies and staining methods for detection of osteoclasts [11].

Osteogenesis enhancement by bioglass-doxycycline complex is hypothesized to be due to the osteoinductive and osteoconductive properties of bioglass, the bactericidal, inflammation reductive, immunosuppressive, and anti-collagenase properties of the doxycycline, osteoclastogenesis inhibition by BG-D, and increasing the chemotaxis of osteoblasts [4,23]. Further studies are required to better determine the contribution of each aforementioned parameters. In the present study, bone regeneration was higher in the bioglass-doxycycline group compared to the bioglass group. Further studies containing a larger sample size are required to assess the doxycycline efficacy in combination with bone grafts. The efficacy of doxycycline in combination with bioglass for regeneration of bone defects should be also tested in clinical trials.

CONCLUSION

The results obtained show that doxycycline increases the number of osteoblasts and decreases the number of osteoclasts when it used in combination with bioglass to enhance new bone formation in rats. Thus, bioglass-doxycycline complex may be a suitable graft in bone regeneration for medical applications.

DECLARATIONS

Acknowledgement

The authors are deeply thankful to all colleagues for their kind support.

Conflicts of interest

No conflict of interest is associated with this work. No financial support was received for this study

Contribution of authors

We declare that this work was done by the authors named in this article and all liabilities

pertaining to claims relating to the content of this article will be borne by the authors. Mona Mokhtarian contributed to the proposal preparation, materials order, and surgical assessments. Nasrin Esfahanizadeh contributed to the proposal preparation, analysis of the data, project management, and manuscript writing. Mohammad Reza Nourani contributed to composing the main idea, designing the research plan, analyzing the histological slides, and finalizing the manuscript preparation.

Open Access

This is an Open Access article that uses a funding model which does not charge readers or their institutions for access and distributed under the terms of the Creative Commons Attribution License (<http://creativecommons.org/licenses/by/4.0>) and the Budapest Open Access Initiative (<http://www.budapestopenaccessinitiative.org/read>), which permit unrestricted use, distribution, and reproduction in any medium, provided the original work is properly credited.

REFERENCES

1. Limirio PH, Rocha FS, Batista JD, Guimaraes-Henriques JC, de Melo GB, Dechichi P. The Effect of Local Delivery Doxycycline and Alendronate on Bone Repair. *AAPS PharmSciTech* 2016; 17(4): 872-877.
2. Bassetti C, Kallenberger A. Influence of chlorhexidine rinsing on the healing of oral mucosa and osseous lesions. *J Clin Periodontol* 1980; 7 (6): 443-456.
3. Devlin H, Sloan P. Early bone healing events in the human extraction socket. *Int J Oral Maxillofac Surg* 2002; 31 (6): 641-5.
4. Silva AC, Oliveira MR, Amaral LF, Ferreira S, Garcia IR, Mariano RC. Effect of Doxycycline in Gel Form on Bone Regeneration: Histomorphometric and Tomographic Study in Rat Calvaria. *J Periodontol* 2016; 87 (1): 74-82.
5. Soufdoost RS, Yazdani M, Tahmasebi E, Yazdani A, Tebyanian H, Karami A, Nourani MR, Panahi Y. In vitro and in vivo evaluation of novel Tadalafil β -TCP/Collagen scaffold for bone regeneration: A rabbit critical-size calvarial defect study. *Biocybernetics and Biomedical Engineering* 2019; 39 (3): 789-796.
6. Hench LL, Jones JR. Bioactive Glasses: frontiers and challenges. *Front Bioeng Biotechnol* 2015; 3: 194.
7. Jones JR. Reprint of: Review of bioactive glass: from hench to hybrids. *Acta Biomater* 2015; 23: 53-82.
8. Liu J, Rawlinson SC, Hill RG, Fortune F. Strontium-substituted bioactive glasses in vitro osteogenic and antibacterial effects. *Dent Mater* 2016; 32 (3): 412-422.
9. Esfahanizadeh N, Daneshparvar P, Takzaree N, Rezvan M, Daneshparvar N. Histologic Evaluation of the Bone Regeneration Capacities of Bio-Oss and MinerOss X in

- Rabbit Calvarial Defects. *Int J Periodontics Restorative Dent* 2019; 39 (6): 219-227.
10. Yagan A, Kesim S, and Liman N. Effect of low-dose doxycycline on serum oxidative status, gingival antioxidant levels, and alveolar bone loss in experimental periodontitis in rats. *J Periodontol* 2014; 85 (3): 478-489.
 11. Zhou X, Zhang P, Zhang C, An B, Zhu Z. Tetracyclines inhibit rat osteoclast formation and activity in vitro and affect bone turnover in young rats in vivo. *Calcif Tissue Int* 2010; 86 (2): 163-171.
 12. Mosaddad SA, Tahmasebi E, Yazdani A, Rezvani MB, Seifalian A, Yazdani M, Tebyanian H. Oral microbial biofilms: an update. *Eur J Clin Microbiol Infect Dis* 2019; 38 (11): 2005-2019.
 13. Al-Ali W, Bissada NF, Greenwell H. The effect of local doxycycline with and without tricalcium phosphate on the regenerative healing potential of periodontal osseous defects in dogs. *J Periodontol* 1989; 60 (10): 582-590.
 14. National Research Council. *Guide for the care and use of laboratory animals*. National Academies Press; 2010.
 15. Babavalian H, Shokrgozar MA, Bonakdar S, Shakeri F, Tebyanian H. Healing effects of synthetic and commercial alginate hydrogel dressings on wounds: a comparative study. *Trauma Mon* 2017; 22 (6): e38941.
 16. Babavalian H, Tebyanian H, Latifi AM, Shokrgozar MA, Bonakdar S, Shakeri F. The effect of synthetic alginate sulfate hydrogels with recombinant pdgf-bb on wound healing. *Bratisl Lek Listy* 2018; 119 (6): 391-396.
 17. Karami A, Tebyanian H, Barkhordari A, Motavallian E, Soufdoost RS, Nourani MR. Healing effects of ointment drug on full-thickness wound. *CR Acad Bulg Sci* 2019; 72 (1): 123-129.
 18. Shakeri F, Tebyanian H, Karami A, Babavalian H, Tahmasbi MH. Effect of topical phenytoin on wound healing. *Trauma Mon* 2017; 22 (5): e35488.
 19. Tebyanian H, Karami A, Motavallian E, Aslani J, Samadikuchaksaraei A, Arjmand B, Nourani MR. Histologic analyses of different concentrations of TritonX-100 and Sodium dodecyl sulfate detergent in lung decellularization. *Cell Mol Biol (Noisy-le-grand)* 2017; 63 (7): 46-51.
 20. Tebyanian H, Karami A, Motavallian E, Aslani J, Samadikuchaksaraei A, Arjmand B, Nourani MR. A comparative study of rat lung decellularization by chemical detergents for lung tissue engineering. *Open Access Maced J Med Sci* 2017; 5 (7): 859-865.
 21. Tebyanian H, Karami A, Motavallian E, Samadikuchaksaraei A, Arjmand B, Nourani MR. Rat lung decellularization using chemical detergents for lung tissue engineering. *Biotech Histochem* 2019; 94 (3): 214-222.
 22. Franco GC, Kajiya M, Nakanishi T, Ohta K, Rosalen PL, Groppo FC, Ernst CW, Boyesen JL, Bartlett JD, Stashenko P, et al. Inhibition of matrix metalloproteinase-9 activity by doxycycline ameliorates RANK ligand-induced osteoclast differentiation in vitro and in vivo. *Exp Cell Res* 2011; 317 (10): 1454-1464.
 23. Agarwal A, Bhattacharya HS, Srikanth G, Singh A. Comparative evaluation of decalcified freeze-dried bone allograft with and without local doxycycline in non-contained human periodontal infrabony defects. *J Indian S Periodontology* 2013; 17 (4): 490-494.
 24. Gomes KDN, Alves A, Dutra PGP, Viana GSB. Doxycycline induces bone repair and changes in Wnt signalling. *Int J Oral Sci* 2017; 9 (3): 158-166.