

Original Research Article

Effect of *Angelica gigas* Nakai extract on hepatic damage in rats

Won Tae Kim¹, Kang Min Kim^{2*}, Jae Seon Kang^{1*}

¹Department of Pharmacy, ²Department of Pharmaceutical Science and Technology, Kyungsoong University, Busan, Republic of Korea

*For correspondence: **Email:** kimkms@ks.ac.kr; **Tel:** +82-51-663-4891

Sent for review: 19 December 2019

Revised accepted: 20 April 2020

Abstract

Purpose: To determine the antioxidant and hepatoprotective effects of decursin and decursinol angelate (D/DA) isolated from *Angelica gigas* Nakai (AGN).

Methods: The 2,2-diphenyl-1-picrylhydrazyl (DPPH) scavenging activity of D/DA was assessed in a rat model using blood tests, western blotting, and histopathological analyses to identify the pharmaceutical effects of D/DA on liver morphology.

Results: The DPPH scavenging activity of D/DA was 47.11 µg/mL. Administration of D/DA to carbon tetrachloride (CCl₄)-treated rats led to a decrease (13.59 %) in the total liver mass of control rats. Decursin and decursinol angelate also lowered the levels of alanine aminotransferase (ALT) and aspartate aminotransferase (AST), but increased the concentrations of antioxidant enzymes in the liver, including catalase (CAT) and glutathione peroxidase (GPx). Histological examination revealed that D/DA also reduced hepatocellular damage in the rats.

Conclusion: D/DA from AGN has significant anti-hepatotoxic and antioxidant activities, and thus, is a potential herbal drug for treating liver damage.

Keywords: Decursin, Decursinol angelate, Antihepatotoxicity, Antioxidant, *Angelica gigas* Nakai

This is an Open Access article that uses a fund-ing model which does not charge readers or their institutions for access and distributed under the terms of the Creative Commons Attribution License (<http://creativecommons.org/licenses/by/4.0>) and the Budapest Open Access Initiative (<http://www.budapestopenaccessinitiative.org/read>), which permit unrestricted use, distribution, and reproduction in any medium, provided the original work is properly credited.

Tropical Journal of Pharmaceutical Research is indexed by Science Citation Index (SciSearch), Scopus, International Pharmaceutical Abstract, Chemical Abstracts, Embase, Index Copernicus, EBSCO, African Index Medicus, JournalSeek, Journal Citation Reports/Science Edition, Directory of Open Access Journals (DOAJ), African Journal Online, Bioline International, Open-J-Gate and Pharmacy Abstracts

INTRODUCTION

Angelica gigas Nakai is a medicinal herb that is widely used in Asia (Korea, Japan, and China) [1]. In the US and Europe, AGN is used as a dietary supplement [2]. The AGN of Korea produces dark-purple flowers that contain coumarins. The most representative substances of this herb are D and DA, which are known to have a range of pharmacological effects and are used to treat symptoms of menopause, migraines, dysmenorrhea, anemia, and pain.

They are also used in tonics and as sedative agents [3-5].

Antioxidants, such as coumarins, reduce the risk of diseases, such as cancer and heart disease, by eliminating reactive oxygen species (ROS), including H₂O₂, hydroxyl radicals, and superoxide ions [6,7]. Plants are the primary sources of antioxidants. The 2,2-diphenyl-1-picrylhydrazyl assay is commonly used to evaluate antioxidant activity [7].

Alcohol metabolism takes place primarily in the liver and is accompanied by the production of acetaldehyde and nicotinamide adenine dinucleotide (NADH). The amount of reactive radicals is increased in the liver due to acetaldehyde accumulation and leads to lipid peroxide production, fat accumulation, and a decrease in the protein-synthesis capacity of the liver [8-9].

Here, using a rat model of CCl₄-induced hepatotoxicity, the possible ability of D/DA to diminish or prevent tissue damage caused by ROS was investigated.

EXPERIMENTAL

Reagents and animals

D/DA from AGN used in this study was extracted, isolated, and identified using high performance liquid chromatography (HPLC) [10], as described below. The D/DA standards are provided by the Ministry of Food and Drug Safety (MFDS). All chemicals and solvents were purchased from Tedia Co., Ltd (Tedia, USA) and Sigma-aldrich (Seoul, Korea). Sprague Dawley rats having approximately 150 g body weight were obtained from Samtako Bio Korea (Ohsan, Korea).

Before conducting the experiments, the rats were housed for two weeks at 23 ± 1 °C and 60 ± 5 % humidity to acclimatize. The study was performed in accordance with the guidelines provided by the Institutional Review Board of Kyungshung University (Confirmation no. research-2017-003) and the World Health Organization guidelines for the evaluation of herbal medicines [11].

Identification of decursin and decursinol angelate

Angelica gigas Nakai was obtained from the Simmani Corporation (Hamyang, Kyungnam, Korea) in 2019. A *voucher* specimen of AGN was kept at the herbarium in the College of Pharmacy, Kyungshung University (no. 19-01-AG). D/DA from AGN was extracted using 95 % ethanol and analyzed using HPLC, as previously described by Lee *et al* [12].

DPPH radical scavenging activity

The radical-scavenging capacity of test compounds (D/DA) was determined using the DPPH antioxidant assay using a modification of the method described by Blois [13]. D/DA ethanol solution was firstly mixed with the DPPH stock solution in methanol for DPPH radical

scavenging activity. The final concentration was 0.2 mM for DPPH in every D/DA (1, 10, 20, 40, 80, and 160 µg/mL) ethanol solution (experiment), 0.2 mM DPPH in ethanol (Control), and D/DA in a methanol and ethanol solutions (blank). The standard solution used was α-tocopherol. The final concentrations of α-tocopherol used were the same as those of the corresponding D/DA samples. The analysis was performed after 30 min of preparing each sample using a UV-Vis spectrophotometer, at a 518 nm wavelength. The DPPH scavenging activity (D) was computed as in Eq 1.

$$D (\%) = \{1 - (At - Ab)/Ac\}100 \dots\dots\dots (1)$$

Where At, Ab and Ac are the absorbance of test, blank and control samples, respectively.

In vivo study

The following 4 groups of rats (n = 5 per group) were used: a no-treatment control group (CG), a negative group (NG; treated with CCl₄), a positive group (PG; treated with CCl₄ and silymarin), and an experimental group (EG, treated with CCl₄ and D/DA) [14]. Rats in CG received 0.5 % carboxymethyl cellulose (7 mL/kg body weight) solution orally for 14 days. Rats in NG received a 0.5 % carboxymethyl cellulose solution (7 mL/kg body weight) orally for 14 days, and then received CCl₄ (3 mL/kg body weight) containing olive oil intraperitoneally. CG rats received 0.5 % carboxymethyl cellulose (7 mL/kg body weight) solution orally for 14 days. NG rats received a 0.5 % carboxymethyl cellulose solution (7 mL/kg body weight) orally for 14 days, and then received CCl₄ (3 mL/kg body weight) in olive oil intraperitoneally. PG and EG rats received silymarin and D/DA, respectively, orally at a daily dose of 50 mg/kg for 14 days and then received CCl₄ (3 mL/kg body weight) in olive oil intraperitoneally. At day 15, serum blood samples were collected for AST and ALT analysis, which were analyzed with a GOT-GPT assay kit (Asan Pharmaceutical Inc., Korea) and AST and ALT levels were quantified using a microplate reader (EL 800 Universal Microplate Reader, BIOTEK Instrument, Inc., Winooski, VT, USA) at a 505 nm wavelength.

Histopathological studies

The staining protocol used was adapted from the method described by Akhtar *et al* [15]. Blood was washed out from the liver and kidney using a PBS (0.01 M phosphate buffered saline, pH 7.4) at 4°C. Then, the liver and kidney samples were fixed in 4 % neutral buffered paraformaldehyde solution for 12 h, then dehydrated and embedded

in paraplast (60 °C). Finally, 5- μ m sections were observed with hematoxylin and eosin (H & E) staining. Light microscope used for histopathology of testes (DP-70, Olympus, Tokyo, Japan).

Western blot analysis

Liver tissues from the four groups of rats treated with CMC solution, CCl₄, silymarin, and D/DA were washed and lysed with 1X ice-cold lysis buffer (pH 7.4). Cell lysates were centrifuged at 13,000 rpm for 15 min; the supernatant was collected for further analysis. The Protein concentration was analyzed by the BCA protein assay kit (Pierce, Rockford, IL, USA). Protein solutions were pre-heated (95 °C, 5 min), loaded on a gel plate and separated using 10% sodium dodecyl sulfate-polyacrylamide gel electrophoresis (SDS-PAGE). The samples were transferred onto a polyvinylidene difluoride (PVDF) membrane using a semi-dry transfer system (Bio-Rad, Hercules, CA, USA) and blocked using a solution containing PBS with Tween 20 (PBST) and 5 % non-fat milk solution for 3 h. The membrane was incubated for 16 h at 4°C with a primary antibody (β - actin, CAT, and GPX) and then incubated for 1 h with secondary antibody (anti-rabbit IgG and anti-goat IgG), finally, the membrane was washed three times (4 min each) with PBST. The samples' chemiluminescence was quantified using a chemiluminescence detection system (Santa Cruz Biotechnology Inc., Delaware, CA, USA) [16].

Statistical analysis

Data are expressed as mean \pm standard deviation (n = 5). All statistical analyses (*p* values < 0.05) were carried out using one-way analysis of variance. Data with the *p* values < 0.05 are considered to be statistically significant.

RESULTS

DPPH radical scavenging activity

The D/DA were obtained and identified as previously described [12]. The yield of D/DA from AGN was 75%, as analyzed by HPLC. Although the DPPH radical scavenging activity of D/DA was lower than that of α -tocopherol, D/DA displayed better antioxidant potential as compared to that of ascorbic acid (Figure 1), indicating that D/DA was able to capture free radicals formed by DPPH. The SC₅₀ values obtained were 47.11 and 9.3 μ g/mL for D/DA and ascorbic acid, respectively [17].

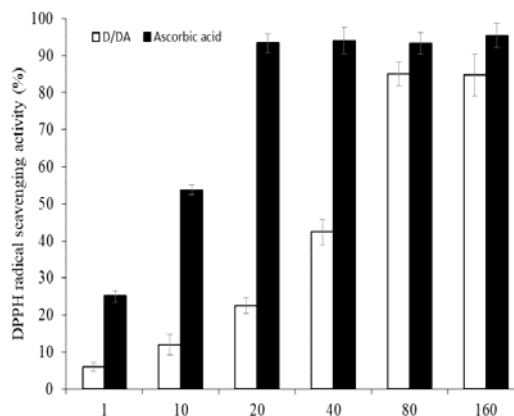


Figure 1: DPPH radical-scavenging activities of D/DA and α -tocopherol

Liver weight and serum levels of AST and ALT

The hepatoprotective effects of D/DA on CCl₄-treated rats (at a dose of 3 mL/kg body weight) are summarized in Table 1. These results indicate that rats administered CCl₄ showed severe hepatic damage (NG) compared to rats in the CG and those in the PG and EG groups, which were treated with silymarin (PG) and D/DA (EG), respectively. The beneficial effects of silymarin (PG) and D/DA (EG) were confirmed by the decrease in liver mass (13.24 g \pm 0.99 g and 12.98 g \pm 1.01 g; *p* < 0.05) when compared to that of rats treated with CCl₄ alone (NG) (Table 1). The levels of ALT and AST in CG were lower than those in the other groups (Table 1). The NG rats showed increased levels of AST and ALT. The PG and EG rats also had clearly reduced levels of AST and ALT when compared to those of the NG rats (*p* < 0.05) (Table 1). Serum AST levels decreased clearly in the PG compared to those in the NG and EG rats, but ALT serum levels were lower in the EG rats compared to those in the PG and NG rats. The AST/ALT ratio in the CG rats was calculated to be 1.03, and the NG rats showed the highest AST/ALT ratio of 1.14.

The effects of hepatotoxicity in liver tissues

The effect of D/DA on the expression of antioxidant enzymes was evaluated. In the liver tissue, a significant decrease in CAT (44 %) and GPx (36 %) levels was observed in the NG rats as compared to the levels in the CG rats (Figure 2). Pretreatment with D/DA (EG) and silymarin (PG) significantly increased CAT (87 and 99 %) and GPx (54 and 59 %) levels (*p* < 0.05) (Figure 2).

Table 1: Effect of D/DA on serum-enzyme concentration in rats

Group	Liver weight (g)	ALT (IU/L)	AST (IU/L)	AST/ALT
CG	11.08 ± 0.25	56.2 ± 3.02	57.8 ± 4.9	1.03 ± 0.01
NG	15.02 ± 0.57	329.5 ± 14.9	374.2 ± 20.6	1.14 ± 0.02
PG	13.24 ± 0.99*	259.4 ± 6.30*	217.9 ± 4.55*	0.84 ± 0.01
EG	12.98 ± 1.01*	227.0 ± 6.35*	237.5 ± 21.6*	1.05 ± 0.01

All values are mean ± SD (n = 5). *Significantly different from NG ($p < 0.05$)

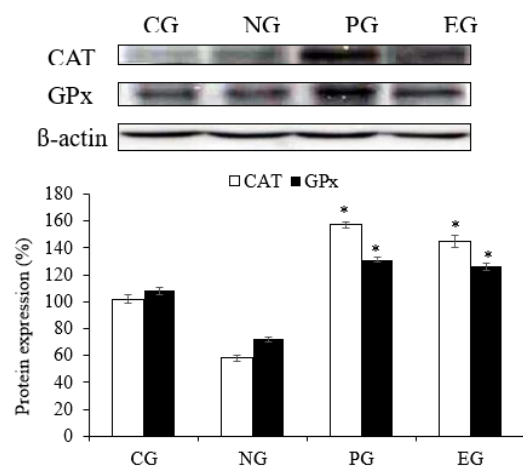


Figure 2: The antioxidant effect of D/DA on catalase and glutathione peroxidase enzymes in the rats with CCl_4 -induced hepatotoxicity. *Significantly different from NG ($p < 0.05$)

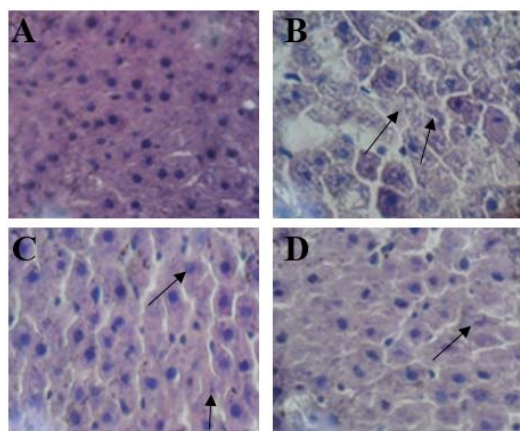


Figure 3: Histological results of the liver tissue of rats with CCl_4 -induced hepatic damage. (A) CG, (B) NG, (C) PG and (D) EG. The arrows indicate cells undergoing necrosis. *significantly different from NG ($p < 0.05$)

Histopathological features

The results of liver histopathology examination are shown in Figure 3. The normal structure of CG rat liver is shown in Figure 3 A. In comparison, the evidence for tissue necrosis in

NG is shown in Figure 3 B. Treatment with silymarin and D/DA resulted in a lower level of cell necrosis (Figures 3 C and D).

DISCUSSION

This study examined the DPPH-scavenging and hepatoprotective effects of D/DA obtained from AGN. *Angelica gigas* Nakai is routinely used for the treatment or prevention of various diseases, such as menopausal syndromes, injuries, arthritis, and dysmenorrhea [2]. The D/DA pyranocoumarins components of AGN exhibit several pharmacological effects, such as bacterial growth inhibition, metabolic inhibition, and antitumor, anti-inflammatory, and antioxidant effects [18].

Many herbal medicines are known to have properties that could be benefit disorders and cancer [19,20]. Figure 1 shows that D/DA, when tested using the DPPH assay, was able to show free-radical scavenging effects. Decursin and decursinol angelate displayed a higher antioxidant activity compared to that of ascorbic acid (Figure 1). The scavenging activity of D/DA was found to be 85.01 ± 3.21 % for DPPH at 80 $\mu\text{g}/\text{mL}$. In comparison, the activity of ascorbic acid was found to be 93.45 ± 2.57 % for DPPH at 20 $\mu\text{g}/\text{mL}$. Although D/DA has antioxidant activity at higher concentrations compared to ascorbic acid, it may possess a potent antioxidant activity.

Increased levels of ALT and AST indicate poor liver function, liver damage and necrosis [21, 22]; The AST/ALT ratio is an important indicator of hepatic injury [23]. Clinically, an AST/ALT ratio less than 1 needs to be maintained for optimal liver function during mild liver damage [24]. Severe liver damage is indicated by an AST/ALT ratio >1 [25]. The PG and EG AST/ALT ratios (0.84 and 1.05, respectively) showed decreased values when compared to NG AST/ALT ratio (1.14). These results indicate that D/DA is able to significantly decrease the levels of hepatic injury (Table 1).

The NG group rats, which were treated with CCl₄, showed a slightly decreased expression of CAT and GPx proteins when compared with CG rats [26]. Treatment with silymarin showed a significant increase in the expressions of the CAT and GPx in the liver tissue compared to the expression of those proteins in the untreated NG group [27]. As seen in Figure 2, CAT and GPx activities also increased significantly ($p < 0.05$) in the EG rats compared to those in the NG rats. Carbon tetrachloride causes a reduction in the activities of CAT and superoxide dismutase (SOD) [27]; it activates lipid peroxidation and an excessive formation of damaging free radicals in tissue [26]. These results clearly indicate that treatment with D/DA and silymarin attenuate these changes in rats enzymatic activities.

Histology of liver tissues from pretreated with D/DA and silymarin showed significant liver protection against necrosis when compared to NG rats. No-treatment control-group rats displayed normal liver tissues [28]. Hence, it can be said that D/DA has the ability to protect the liver against CCl₄-induced damage.

CONCLUSION

The findings of this study show that D/DA has DPPH radical scavenging effects, decreases AST and ALT levels, and normalize CAT and GPx enzyme expression levels in rats with CCl₄-induced hepatotoxicity. Thus, D/DA may have protective effects against liver damage in humans but this required further investigations.

DECLARATIONS

Acknowledgement

This research was supported by Kyungsoong University Research Grant in 2020.

Conflict of interest

No conflict of interest is associated with this work.

Contribution of authors

We declare that this work was done by the authors named in this article and all liabilities pertaining to claims relating to the content of this article will be borne by the authors. The experiments in this study were done by Won Tae Kim. Jae Seon Kang reviewed this manuscript and gave comments for designing this study. Kang Min Kim and Jae Seon Kang drafted this manuscript and supervised the other authors.

Open Access

This is an Open Access article that uses a funding model which does not charge readers or their institutions for access and distributed under the terms of the Creative Commons Attribution License (<http://creativecommons.org/licenses/by/4.0>) and the Budapest Open Access Initiative (<http://www.budapestopenaccessinitiative.org/read>), which permit unrestricted use, distribution, and reproduction in any medium, provided the original work is properly credited.

REFERENCES

1. Bae SJ, Rho GJ, Kim KM, Kang JS. Pharmacological effects of active saponins from *Panax ginseng* Meyer. *Trop J Pharm Res* 2019; 18: 556-561.
2. Kim KM, Kim TH, Park YJ, Kim IH, Kang JS. Evaluation of the genotoxicity of decursin and decursinol angelate produced by *Angelica gigas* Nakai. *Mol Cell Toxicol* 2009; 5: 83-87.
3. Konoshima M, Chi HJ, Hata K. Coumarins from the root of *Angelica gigas* Nakai. *Chem Pharm Bull* 1968; 16: 1139-1140.
4. Yuk CS. Coloured medicinal plants of Korea. Seoul, Korea: Korea academic book Co.; 1989.
5. Lee S, Lee YS, Jung SH, Shin KH, Kim BK, Kang SS. Anti-tumor activities of decursinol angelate and decursin from *Angelica gigas*. *Arch Pharm Res* 2003; 26: 727-730.
6. Shekhar TC, Anju G. Antioxidant activity by DPPH radical scavenging method of *Ageratum conyzoides* Linn. *Leaves. A J Ethno* 2014; 1: 244-249.
7. Padmanabhan P, Jangle SN. Evaluation of DPPH radical scavenging activity and reducing power of four selected medicinal plants and their combinations. *Int J Pharm Sci Drug Res* 2012; 4: 143-146.
8. Lee S, Lee YS, Jung SH, Shin KH, Kim BK. Antioxidant activities of decursinol angelate and decursin from *Angelica gigas* roots. *Nat Prod Sci* 2003; 9: 170-173.
9. Blois MS. Antioxidant determination by the use of a stable free radical. *Nature* 1958; 181: 1199-1200.
10. Kim KM, Jung YJ, Hwang SW, Kim MJ, Kang JS. Isolation and purification of decursin and decursinol angelate in *Angelica gigas* Nakai. *J Korean Soc Food Sci Nutr* 2009; 38: 653-656.
11. World organization for animal health. *Terrestrial animal helath code, Chapter 7.8 Use of animals in research and education*. 2015; 372-381.
12. Lee YJ, Kim KM, Kang JS. Preventive effect of *Angelica gigas* Nakai extract oral administration on dry eye syndrome. *Asian Pac J Trop Med* 2018; 11: 369-375.
13. Zhou K, Yin JJ, Yu L. ESR determination of the reactions between selected phenolic acids and free radicals or transition metals. *Food Chem* 2006; 95: 446-457.
14. Yang DS, Hong SG, Choi SM, Kim BN, Sung HJ, Yoon Y. Effect of an oriental herbal composition, jang baek

- union, on alcohol-induced hangover and CCl₄-induced liver injury in rats. *J Korean Soc Food Sci Nutr* 2004; 33: 78-82.
15. Akhtar N, Srivastava MK, Raizada RB. Assessment of chlorpyrifos toxicity on certain organs in rat, *Rattus norvegicus*. *J Environ Biol* 2009; 30: 1047-1053.
 16. Ok S, Kang JS, Kim KM. Cultivated wild ginseng extracts upregulate the anti-apoptosis systems in cells and mice induced by bisphenol A. *Mol Cell Toxicol* 2019; 13: 73-82.
 17. Oh CW, Li MH, Kim EH, Park JS, Lee JC, Ham SW. Antioxidant and radical scavenging activities of ascorbic acid derivatives conjugated with organogermanium. *Bull Korean Chem Soc* 2010; 31: 3513-3514.
 18. Kim KM, Ok S, Go YS, Kang JS. Recovery from the two-generation reproductive toxicity in sprague-dawley rats by treatment with decursin and decursinol angelate. *J Life Sci* 2015; 25: 765-772.
 19. Kasote DM, Katyare SS, Hegde MV, Bae H. Significance of antioxidant potential of plants and its relevance to therapeutic applications. *Int J Biol Sci* 2015; 11: 982-991.
 20. Krishnaiah D, Sarbatly R, Nithyanandam R. A review of the antioxidant potential of medicinal plant species. *Food Bioprod Process* 2011; 89: 217-233.
 21. Liu D, He H, Yin D, Que A, Tang L, Liao Z, Huang Q, He M. Mechanism of chronic dietary iron overload induced liver damage in mice. *Mol Med Rep* 2013; 7: 1173-1179.
 22. Poortahmasebi V, Alavian SM, Keyvani H, Norouzi M, Mahmoodi M, Jazayeri SM. Hepatic steatosis: prevalence and host/viral risk factors in Iranian patients with chronic hepatitis B infection. *Asian Pac J Cancer Prev* 2014; 15: 3879-3884.
 23. Chen SS, Zhu K, Wang R and Zhao X. Preventive effect of polysaccharides from the large yellow croaker swim bladder on HCl/ethanol induced gastric injury in mice. *Exp Ther Med* 2014; 8: 316-322.
 24. Nyblom H, Berggren U, Balldin J, Olsson R. High AST/ALT ratio may indicate advanced alcoholic liver disease rather than heavy drinking. *Alcohol Alcoholism* 2004; 39: 336-339.
 25. Mabrouk M, El Raziky M, Zayed N, Salama R, El Akel W, Awad T, El Beshlawy M, Esmat G. Clinical, biochemical and pathological profiles of 5464 Egyptian chronic hepatitis C infected patients. *Hepatogastroenterol* 2013; 60: 1731-1735.
 26. Jyothi Y, Sangeetha D. Anti-hepatotoxic and antioxidant activity of *Limnanthemum indicum* against carbon tetrachloride induced liver toxicity in rats. *Indian J Pharm Educ* 2017; 51: 321-328.
 27. Ramezannezhad P, Nouri A, Heidarian E. Silymarin mitigates diclofenac-induced liver toxicity through inhibition of inflammation and oxidative stress in male rats. *J Herbmed Pharmacol* 2019; 8: 231-237.
 28. Adewale OB, Adekeye AO, Akintayo CO, Onikanni A, Sabiu Sahee. Carbon tetrachloride (CCl₄)-induced hepatic damage in experimental Sprague Dawley rats: Antioxidant potential of *Xylopiya aethiopicum*. *J Phytopharmacol* 2014; 3: 118-123.