

Original Research Article

Studies on the protective effect of total flavonoids from *Cichorium glandulosum* roots against carbon tetrachloride-induced liver fibrosis in rats

Dong-Mei Qin¹, Li-Ping Hu², Yu Zhang¹, Yu Kang¹, Chang Han¹, Ting Dang¹, Yun-Bin Jiang^{1,3*}

¹School of Pharmacy/Key Laboratory of Xinjiang Phytomedicine Resource and Utilization, Ministry of Education, Shihezi University, Shihezi 832002, ²Department of Infectious Diseases, First Affiliated Hospital of Xinjiang Medical University, Urumqi 830054, ³College of Pharmaceutical Sciences and Chinese Medicine, Southwest University, Chongqing 400715, PR China

*For correspondence: **Email:** yunbinjiang@sina.com; yunbinjiang@swu.edu.cn

Sent for review: 7 June 2018

Revised accepted: 17 January 2019

Abstract

Purpose: To study the protective influence of total flavonoids from *Cichorium glandulosum* roots (TFCG) against carbon tetrachloride-mediated hepatic fibrosis in rats, and the probable mechanism of action involved.

Methods: Rats with liver fibrosis were orally administered TFCG (50, 100 or 200 mg/kg) once a day for 13 weeks. Liver index and liver injury indices in serum alanine aminotransferase (ALT), aspartate aminotransferase (AST), alkaline phosphatase (AKP), lactate dehydrogenase (LDH), γ -glutamyl transpeptidase (γ -GT), hydroxyproline (HYP), albumin (ALB) and malondialdehyde (MDA) were determined using electronic balance or corresponding assay kits, as appropriate. Following staining with hematoxylin and eosin and Van Gieson, histopathological changes in liver tissues were examined by light microscopy. TGF- β /Smad pathway-related protein expressions in liver tissues, viz, transforming growth factor- β 1 (TGF- β 1), mothers against decapentaplegic homolog 3 (Smad3), Smad7, toll-like receptor 4 (TLR4) and α -smooth muscle actin (α -SMA) were determined using immunohistochemical techniques.

Results: Exposure to TFCG significantly reversed abnormal serum levels of ALT, AST, AKP, LDH, γ -GT, HYP, ALB and MDA rats with liver fibrosis to normal levels, and also decreased their liver index values ($p < 0.01$). Moreover, TFCG improved histopathological changes in the liver tissues of fibrotic rats, and significantly reversed abnormal TGF- β 1, Smad3, Smad7, TLR4 and α -SMA protein expressions in the liver tissues of fibrotic rats to normal levels ($p < 0.05$ or 0.01).

Conclusion: These results indicate that TFCG exerts protective effect against liver fibrosis via a mechanism related to inactivation of TGF- β /Smad pathway. Thus, TFCG may find application in liver fibrosis therapy.

Keywords: *Cichorium glandulosum*, Flavonoids, Liver, Fibrosis, TGF- β /Smad pathway

This is an Open Access article that uses a funding model which does not charge readers or their institutions for access and distributed under the terms of the Creative Commons Attribution License (<http://creativecommons.org/licenses/by/4.0>) and the Budapest Open Access Initiative (<http://www.budapestopenaccessinitiative.org/read>), which permit unrestricted use, distribution, and reproduction in any medium, provided the original work is properly credited.

Tropical Journal of Pharmaceutical Research is indexed by Science Citation Index (SciSearch), Scopus, International Pharmaceutical Abstract, Chemical Abstracts, Embase, Index Copernicus, EBSCO, African Index Medicus, JournalSeek, Journal Citation Reports/Science Edition, Directory of Open Access Journals (DOAJ), African Journal Online, Bioline International, Open-J-Gate and Pharmacy Abstracts

INTRODUCTION

Liver fibrosis results from abnormal proliferation of connective tissue in the liver due to long-term exposure to various hepatotoxic factors such as viruses and alcohol [1]. It is a common pathological feature of various chronic liver diseases [2], and it results in severe damage to the morphology and function of the liver [3]. Liver fibrosis plays an important role in the development of liver cirrhosis. It has been reported that liver cirrhosis resulted in 0.8 million deaths in 1990s, but the figure was more than 1.2 million in 2013, and it is growing rapidly [4]. Therefore, the search for new, effective and safe anti-liver fibrosis drugs is important and urgent. Studies have shown that traditional Chinese medicines (TCMs) have been an essential therapy for liver fibrosis, which implies that the development of anti-liver fibrosis drugs from TCMs is feasible [5,6].

Cichorium glandulosum is found mostly in Xinjiang Uygur Autonomous Region and Caucasia area, and its aerial part and roots are used as medicine [7]. The plant is used to treat hepatitis in folk therapy. In recent years, many studies have reported that *Cichorium glandulosum* exerts hepatoprotective and anti-lipemic effects, and promotes digestion [8]. Flavonoids such as quercetin and isorhamnetin are some of the main active components of *Cichorium glandulosum* [9,10]. Based on the above-mentioned folkloric medical application of *Cichorium glandulosum*, total flavonoids from *Cichorium glandulosum* roots (TFCG) may show anti-liver fibrotic effects. However, there are no studies on the anti-liver fibrotic effects of TFCG at present. Therefore, the present study was aimed at investigating the anti-fibrotic effects of TFCG in a rat model of carbon tetrachloride (CCl₄)-induced hepatic fibrosis, and the possible mechanism involved.

EXPERIMENTAL

Chemicals and reagents

Analytical grade reagents (CCl₄ and ethyl alcohol) were purchased from Tianjin Zhiyuan Chemical Reagent (Tianjin, China). Olive oil was purchased from CPFCCO Food Marketing (Beijing, China), while AB-8 macroporous resin was product of Chemical Plant of Nankai University (Tianjin). Silybin, an anti-liver fibrotic drug [11], was produced by Tianjin Tasly pharmaceutical Company Ltd (Tianjin) and suspended in distilled water prior to use for assays. Assay kits for alanine aminotransferase (ALT), aspartate aminotransferase (AST), lactate dehydrogenase

(LDH), γ -glutamyl transpeptidase (γ -GT), hydroxyproline (HYP), albumin (ALB) and malondialdehyde (MDA) were obtained from Nanjing Jiancheng Bioengineering Institute (Nanjing, China), while alkaline phosphatase (AKP) kit was product of Beyotime (Shanghai, China).

Hematoxylin and eosin (H&E) and Van Gieson (VG) stain kits were purchased from Beijing Solarbio Sci. & Tech. Company Ltd (Beijing). Primary antibodies for transforming growth factor- β 1 (TGF- β 1), mothers against decapentaplegic homolog 3 (Smad3), Smad7, toll-like receptor 4 (TLR4) and α -smooth muscle actin (α -SMA) were purchased from Bioworld (Minneapolis, Minnesota, USA). Biotin-conjugated secondary antibody, ready-to-use strept avidin-biotin complex (SABC) immunohistochemical kits and Diaminobenzidine (DAB) chromogenic reagent kits were products of Nanjing Jiancheng Bioengineering Institute (Nanjing) and Beijing Zhongshan Jinqiao Biotechnology Company Ltd (Beijing), respectively.

Plant material

Cichorium glandulosum roots were obtained from College of Xinjiang Uyghur Medicine (Hetian, China) in August 2015, and were authenticated by Yun-Bin Jiang, a taxonomist. A voucher specimen (no. SHZU 20150806) of the plant was kept at the Herbarium of Shihezi University for further reference.

Experimental animals

Healthy SD rats (200 \pm 30 g) of both sexes were purchased from Experimental Animal Center, Xinjiang Medical University (Urumchi, China). They were kept in a vivarium at 22 \pm 2 °C and 12/12-h light-dark cycle in an atmosphere with a relative humidity of 60 \pm 5 %. They were permitted unlimited access to standard rat feed and water. The rats were handled in line with the directives of the National Institutes of Health Guide regarding the Care and Use of Laboratory Animals for research [12]. The study was approved by the Ethics Committee of Shihezi University (no. 2015-030-01).

Preparation of TFCG

Air-dried *Cichorium glandulosum* roots were finely ground and extracted thrice for 2 h through refluxing with 70 % ethanol (solid/liquid ratio = 1:15). The combined ethanol supernatant was evaporated under reduced pressure to afford a crude extract equivalent to 5.3 % yield. The

crude extract was diluted to 3.0 mg/mL with water, and the pH was adjusted to 7.0 by adding inorganic acid or alkali. Then, the 3.0 mg/mL extract solution (5 bed volume, BV) was subjected to AB-8 macroporous resin column chromatography at a flow rate of 4 BV/h, eluted with 2 BV of 50 % ethanol at a flow rate of 2 BV/h. The combined eluent was evaporated under reduced pressure to yield the purified extract (50.82 % TFCG) which was suspended in distilled water for further assays.

Replication of liver fibrosis model in rats, grouping and treatment

Sixty rats (30 male and 30 female) were hierarchically assigned to normal group (n = 10) and CCl₄-treated group (n = 50). Rat model of liver fibrosis was established by subcutaneous injection of 40 % CCl₄ suspended in olive oil at an initial dose of 1.0 mL/kg, followed with 0.5 mL/kg twice a week for 13 weeks [13]. The rats in the normal group were subcutaneously administered olive oil twice a week for 13 weeks, in place of CCl₄.

At the end of the 4th week, the rats in the CCl₄-treated group were hierarchically and randomly divided into model, positive, 50 mg/kg TFCG, 100 mg/kg TFCG and 200 mg/kg TFCG groups (n = 10). Starting from the 5th week, the rats in the positive and TFCG (50, 100 or 200 mg/kg) groups were orally administered silybin at a dose of 0.2 mg/kg and TFCG at doses of 50, 100 or 200 mg/kg once daily for 13 weeks. The rats in the normal and model groups received equivalent amount of distilled water once a day for 13 weeks, in place of silybin or TFCG.

Determination of liver injury indices in serum

Following the last treatments, the animals were subjected to 24-h fast and their weights were recorded. Under 10 % chloral hydrate anesthesia (3.5 mL/kg), blood was taken from each rat through the abdominal aortic method. Following centrifugation at 3,000 × g and 4 °C for 15 min, the serum samples were frozen at -70 °C and used for determination of liver injury indices i.e. ALT, AST, AKP, LDH, γ-GT, HYP, ALB and MDA with appropriate assay kits in line with the kit protocols. The level of each analyte was from its standard calibration curve [14].

Determination of liver index

After collecting blood, the rats were sacrificed through decapitation, and their livers were excised and rinsed with ice-cold normal saline. After blotting with filter paper, the weights of the

liver samples were recorded. Then, the liver of each rat was fixed in 10 % formalin for histopathological and immunohistochemical assays. Liver index was calculated as in Eq 1.

$$\text{Liver index (\%)} = (A/B)100 \dots \dots \dots (1)$$

where A and B are the liver weight (g) and body weight (g) of rat, respectively.

Histopathology

The liver tissues from all groups which were fixed in 10 % formalin were washed 6 times with phosphate buffer saline, dehydrated in ethanol, and embedded in paraffin. They were sliced into 4-μm thick sections using a microtome [15]. After dewaxing, the sections were stained by H&E and VG according to reported procedures [16], and observed with the aid of NIKON CI-S light microscopy (Tokyo, Japan).

Immunohistochemistry

As described in the histopathology assay, the liver tissues were sliced into 4-μm thick sections. After dewaxing and heat-mediated antigen retrieval, the sections were subjected to incubation with the primary antibodies for TGF-β1, Smad3, Smad7, TLR4 and α-SMA overnight at 4 °C. This was followed with incubation at room temperature with biotin-conjugated secondary antibody for 30 min, and then with SABC immunohistochemical kit under the same conditions.

After staining with DAB chromogenic reagent kit, the sections were examined using NIKON CI-S light microscopy. The sections were scored according degree of staining of cells: no staining, faint yellow, pale brown and brown field under light microscopy were scored 0, 1, 2 and 3, respectively. The score was designated *a*. In addition, the percentage of stain-positive cells under high-power field was calculated. This was designated *b*. Randomly-selected, five high-power fields of each section were observed, and the mean was taken as the final value. The score of semi-quantitative analysis of target protein was given as the product of *a* and *b* i.e. the value of *a* × *b*, and the higher the score, the huger the expression of the target protein.

Statistical analysis

The data are reported as mean ± standard deviation. Statistical differences amongst the various groups were determined using ANOVA followed by LSD multiple comparison (SPSS 21.0 for Windows; SPSS, Inc., Chicago, IL, USA)

[17]. Values of $p < 0.05$ were assumed to indicate significant differences.

RESULTS

Effect of TFCG on liver index of rats with liver fibrosis

Higher liver index was seen significantly in the model group (4.38 ± 0.48 %) than that in the normal group (2.63 ± 0.52 %) ($p < 0.01$). The liver indices were lowered significantly in positive (2.96 ± 0.18 %), 50 mg/kg TFCG (2.79 ± 0.15 %), 100 mg/kg TFCG (2.82 ± 0.17 %) and 200 mg/kg TFCG (2.78 ± 0.48 %) groups, relative to that in the model group ($p < 0.01$).

Influence of TFCG on liver injury indices in the serum of liver fibrotic rats

As shown in Figure 1, markedly higher levels of ALT, AST, AKP, LDH, γ -GT, HYP and MDA were seen in the model group than those in the normal group, and the ALB level in the model group was lower than that in the normal group ($p < 0.01$). The levels of these liver injury indices in positive and TFCG (50, 100 or 200 mg/kg) groups were markedly reversed, relative to those in the model group ($p < 0.01$).

Effect of TFCG on histopathological changes of liver tissues from rats with liver fibrosis

Results of H&E staining revealed that liver tissue in the normal group had normal histomorphology including clear outline of liver lobule, radial

hepatic cords from central veins to periphery, normal hepatocellular morphology, and few inflammatory cell infiltrations. Histopathological changes including destruction of liver tissue structure, fiber mediastinum, pseudo-lobule, disordered rope arrangement, obvious degeneration and hyperplasia of liver cells, vacuolation (fatty degeneration) in cell lumen, swelling of liver cells, balloon-shaped cell frame, and fiber enlargement were observed in the model group. The degree of inflammatory cell infiltrations in the positive group was reduced relative to that in the model group. The fatty degeneration and necrosis in liver cells, degree of inflammatory cell infiltrations, proliferation of fiber connective tissue and pseudo-lobule formation in the TFCG (50, 100 or 200 mg/kg) groups were improved, when compared with those in the model group. With increases in TFCG dose, inflammatory cell numbers were decreased, and hepatocellular morphology got closer to normal. These results are shown in Figure 2.

In Figure 3, liver tissue in the normal group showed normal liver lobule structure, and few fibrous protein depositions around portal area and central veins, as revealed through VG staining. Histopathological changes such as destruction of liver lobule structure, fibrous protein depositions around portal area, and fiber spacing among central veins or portal area in the model group were evident. However, the fibrous protein depositions and fiber spacing among central veins or portal area in the TFCG (50, 100 or 200 mg/kg) groups were decreased, when compared with those in the model group. A few fibrous protein depositions were observed in the

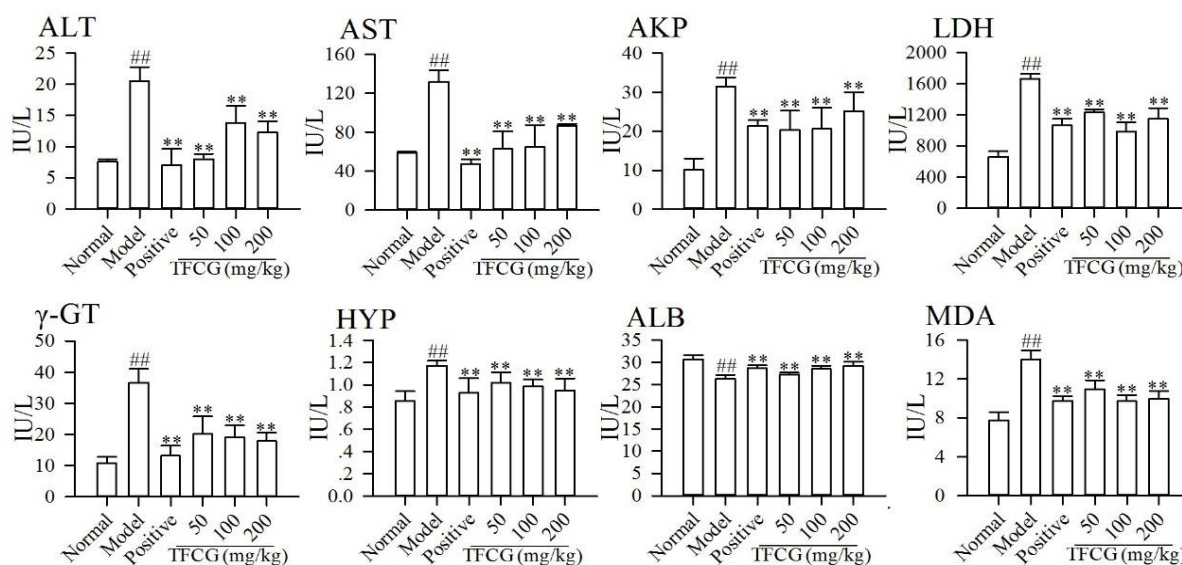


Figure 1: Improved effect of TFCG on liver injury indices in the serum of liver fibrotic rats; $## p < 0.01$, compared with those in the normal group; $**p < 0.01$, compared with those in the model group

200 mg/kg TFCG group. Bubble-like degeneration and inflammatory cell infiltrations were observed in the 100 mg/kg TFCG group, while obvious fibroplasia were observed in the 50 mg/kg TFCG group.

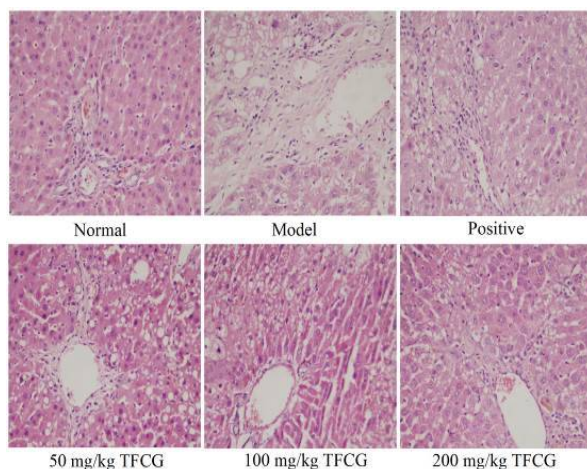


Figure 2: Mitigation effect of TFCG on histopathological changes in liver tissues from rats with liver fibrosis (H&E staining, $\times 200$)

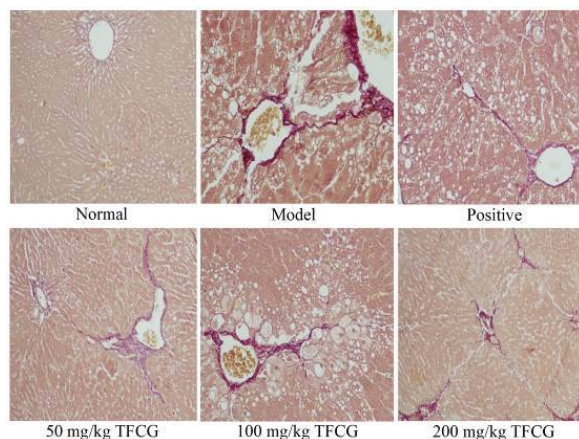


Figure 3: Mitigation effect of TFCG on histopathological changes in liver tissues from rats with liver fibrosis (VG staining, $\times 200$)

Effect of TFCG on TGF- $\beta 1$, Smad3, Smad7, TLR4 and α -SMA protein expressions in liver tissues

Protein expressions of TGF- $\beta 1$, Smad3, TLR4 and α -SMA in the model group were markedly increased, when compared with those in the normal group, and the Smad7 protein expression in the model group was significantly decreased ($p < 0.01$). The protein expressions of TGF- $\beta 1$, TLR4 and α -SMA in the positive group were significantly reduced, relative to those in model group ($p < 0.01$). However, the changes in TGF- $\beta 1$, Smad7, TLR4 and α -SMA protein expressions were significantly reversed in the TFCG (50, 100 or 200 mg/kg) groups, relative to

those in the model group ($p < 0.01$). The Smad3 protein expression in the TFCG (50 or 200 mg/kg) groups was significantly reduced, when compared with that in the model group ($p < 0.05$ or 0.01). These results are shown in Figure 4 and Figure 5.

DISCUSSION

In the present investigation, the protective influence of TFCG against liver fibrosis and related mechanism of action were studied. The findings revealed that TFCG protected against liver fibrosis through a mechanism related to inactivation of the TGF- β /Smad pathway.

Liver index is a macroscopic reflection of liver function, and studies have shown that it is elevated in CCl₄-induced liver fibrosis in rats [18]. The transaminases ALT and AST are procedurally used to evaluate liver damage, which promotes their release from the liver into the blood. Increases in AKP level in the serum results mostly from cholestasis-induced liver injury [19]. Elevations in serum of LDH and γ -GT levels are related to liver pathologies, such as inflammation, cirrhosis and carcinogenesis [20]. It has been reported that Hyp, a non-essential amino acid, is a vital product of collagen metabolism which can objectively indicate the extent of liver fibrosis [21]. Decreased ALB level in the serum is an important pathological manifestation of liver cirrhosis and can objectively reflect the degree of liver fibrosis [22].

Studies have shown that MDA promotes the activation of hepatic stellate cells (HSCs), the central link in occurrence of liver fibrosis; increased MDA level in the serum is an objective reflection of the extent of liver fibrosis [23]. In this study, it was shown that TFCG significantly reversed the abnormal levels of ALT, AST, AKP, LDH, γ -GT, HYP, ALB and MDA in the serum of rats with liver fibrosis to normal, and decreased the liver index of rats with liver fibrosis. These results suggest that TFCG significantly exhibited hepatoprotective and anti-fibrotic effects in the liver.

Usually, H&E staining shows normal liver tissue with clear outline of liver lobule, radial hepatic cords from central veins to periphery, normal hepatocellular morphology, and few inflammatory cell infiltration [24,25]. However, liver tissue with fibrosis exhibits destruction of liver tissue structure, fiber mediastinum, pseudo-lobule, disordered liver rope arrangement, degeneration and hyperplasia of liver cells, vacuolation (fatty degeneration) in cell lumen, swelling of liver

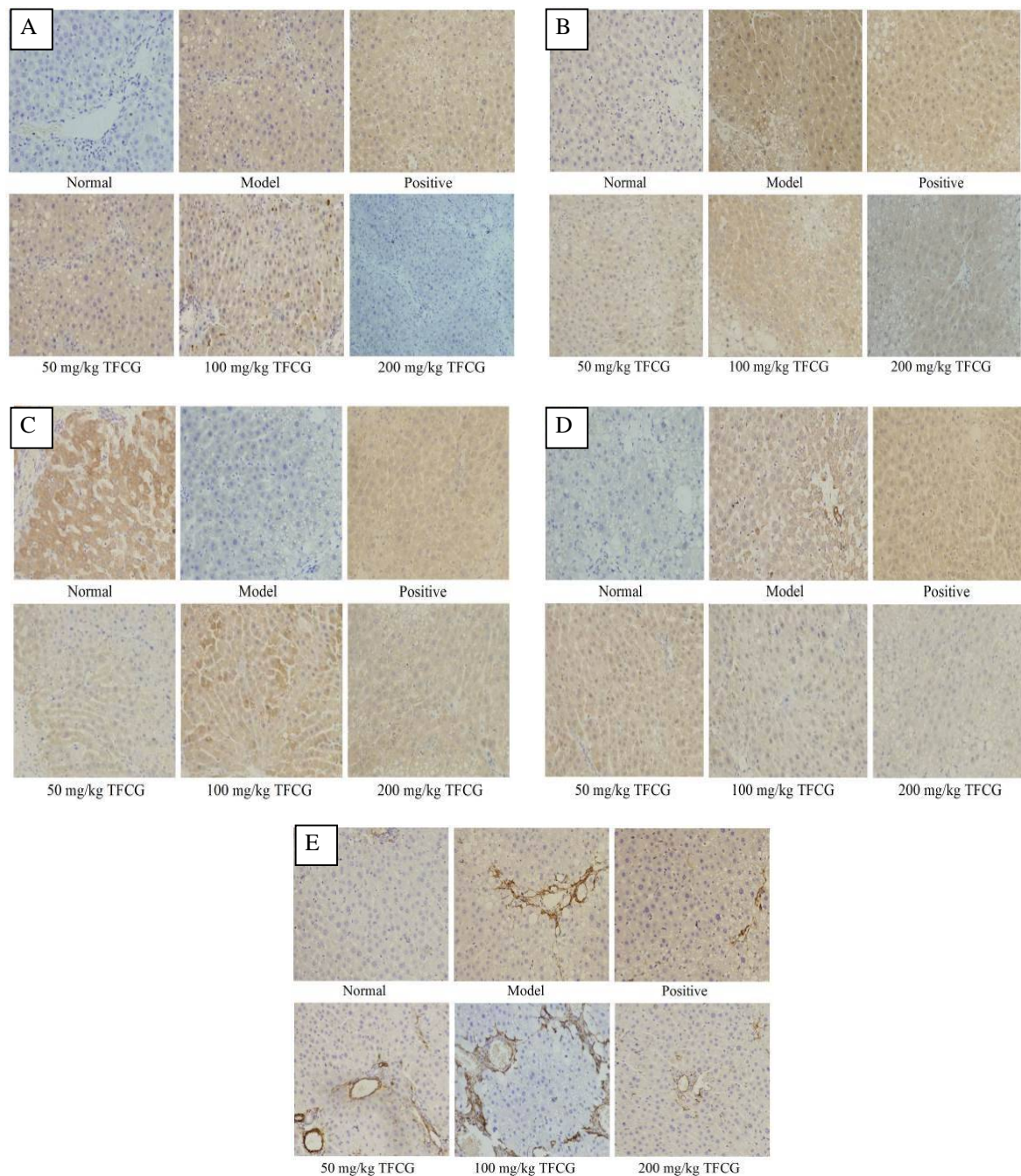


Figure 4: Effect of TFCG on TGF- β 1 (A), Smad3 (B), Smad7 (C), TLR4 (D) and α -SMA (E) protein expression in liver tissues from liver fibrotic rats (immunohistochemical image, $\times 200$)

cells, balloon-shaped cell frame, and fiber enlargement [26,27].

Fibrous protein appears red when stained with VG. After staining with VG, normal liver tissue shows normal liver lobule structure and few fibrous protein depositions around portal area and central veins. However, liver tissue with fibrosis exhibits evidence of destruction of liver lobule structure, fibrous protein depositions around portal area, and clear fiber spacing among the central veins or portal area [28]. The present study showed that TFCG mitigated these

histopathological changes (fatty degeneration and necrosis of liver cells, degree of inflammatory cell infiltrations, proliferation of connective tissue fibers, pseudo-lobule formation, fibrous protein depositions, and fiber spacing among central veins or portal area) in fibrotic liver tissue.

Liver injury-induced multiple stimuli such as oxidative stress, histanoxia, inflammation and immunoreaction result in the occurrence of liver fibrosis [29]. The HSCs are vital in the pathogenesis of hepatic fibrosis [30,31]. Liver

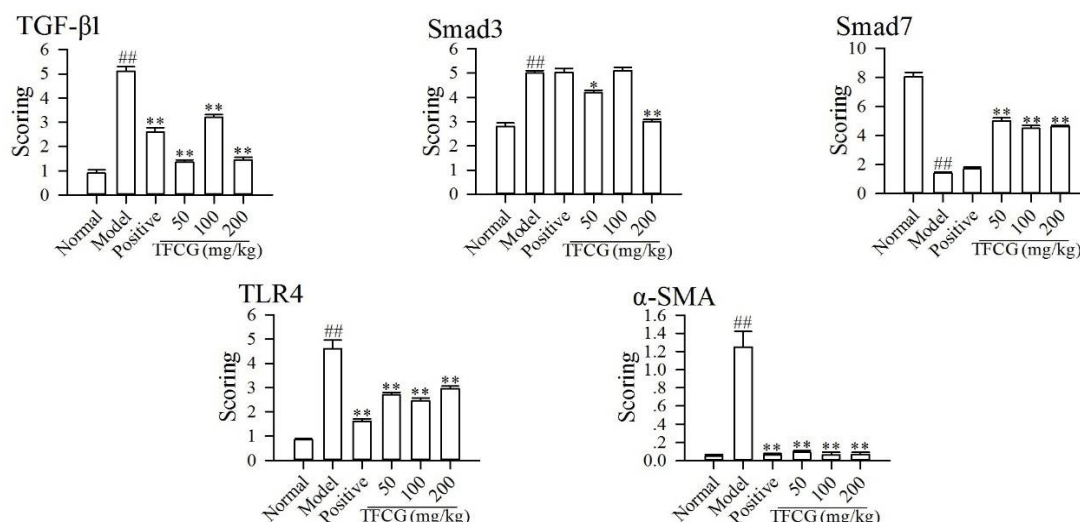


Figure 5: Effect of TFCG on TGF- β 1, Smad3, Smad7, TLR4 and α -SMA protein expressions in liver tissues from liver fibrotic rats (scores from semi-quantitative analysis); ## $p < 0.01$, relative to those in the normal group; * $p < 0.05$, ** $p < 0.01$, relative to those in the model group

injury stimulates HSCs to secrete TGF- β 1. Conversely, TGF- β 1 also stimulates the activation of HSCs, and activated HSCs secrete copious amounts of TGF- β 1 and fibrous collagen, leading to the deposition of extracellular matrix which exacerbates liver fibrosis [32].

It has been reported that TLR4 stimulates HSCs to secrete TGF- β 1 [33], and the expression of α -SMA is a marked feature of HSCs activation [34]. The biological effect of TGF- β 1 is regulated by the TGF- β /Smad pathway. It is known that Smad7 is a major inhibitory regulatory protein, and Smad3 is the activated regulatory protein in the TGF- β /Smad pathway [35]. The present study showed that TFCG significantly reversed the abnormal expressions of TGF- β 1, Smad3, Smad7, TLR4 and α -SMA protein in liver tissues of rats with liver fibrosis to normal. This indicates that the protective effect of TFCG against hepatic fibrosis involves a mechanism related to inactivation of the TGF- β /Smad pathway.

CONCLUSION

The findings of this work indicate that TFCG has a protective effect against liver fibrosis via a mechanism related to inactivation of TGF- β /Smad pathway. Thus, TFCG can potentially be developed into a drug for fibrosis therapy.

DECLARATIONS

Acknowledgement

This work was financially supported by Natural Science Foundation of China (no. 81560680).

Conflict of interest

No conflict of interest is associated with this work.

Contribution of authors

We declare that this work was done by the authors named in this article and all liabilities pertaining to claims relating to the content of this article will be borne by the authors. Yun-Bin Jiang and Dong-Mei Qin conceived and designed the study. Dong-Mei Qin, Li-Ping Hu, Yu Zhang and Yu Kang performed the experiments and collected the data. Dong-Mei Qin, Chang Han and Ting Dang analyzed the data. Yun-Bin Jiang wrote the manuscript. All authors read and approved the manuscript for publication.

REFERENCES

- Bai G, Yan G, Wan P, Zhang R. Anti-hepatic fibrosis effects of a novel turtle shell decoction by inhibiting hepatic stellate cell proliferation and blocking TGF- β 1/Smad signaling pathway in rats. *Oncol Rep* 2016; 36: 2902-2910.
- Wei SZ, Luo SQ, Wang J, Wang JB, Li RS, Zhang XM, Guo YL, Chen C, Ma X, Chen Z, et al. San-Cao Granule (三草颗粒) ameliorates hepatic fibrosis through high mobility group Box-1 protein/Smad signaling pathway. *Chin J Integr Med* 2018; 24: 502-511.
- Brunt EM. Pathology of nonalcoholic fatty liver disease. *Nat Rev Gastroenterol Hepatol* 2010; 7: 195-203.
- GBD 2013 Mortality and Causes of Death Collaborators. Global, regional, and national age-sex specific all-cause and cause-specific mortality for 240 causes of death,

- 1990-2013: a systematic analysis for the Global Burden of Disease Study 2013. *Lancet* 2013; 385: 117-171.
5. Luk JM, Wang X, Liu P, Wong KF, Chan KL, Tong Y, Hui CK, Lan GK, Fan ST. Traditional Chinese herbal medicines for treatment of liver fibrosis and cancer: from laboratory discovery to clinical evaluation. *Liver Int* 2007; 27: 879-890.
 6. Wang CW, Fang XH. Protective effect of rhamnopyranosyl vanilloyl isolated from *Scrophularia ningpoensis* Hemsl (*Scrophulariaceae*) root against acute liver injury in mice. *Trop J Pharm Res* 2016; 15: 1499-1505.
 7. Chinese Pharmacopoeia Commission. *Chinese pharmacopoeia*. Beijing: China Pharmaceutical Technology Press, 2015. 310 p.
 8. Wang XF, Zhang YH, Huang YJ, Shang J, Yang J. The mechanism underlying the therapeutic effect of alcohol extract of *Cichorium glandulosum* Boiss et Hoet on hyperlipidemia in rats. *Progress Mod Biomed* 2014; 14: 3642-3645.
 9. Long T, Gao Y, Niu YJ, Wang H. Research progress in chemical constituents and pharmacological activities of plants in *Cichorium* genus. *Strait Pharmaceut J* 2014; 26: 1-6.
 10. Yang WZ, Wang H, Shang J, Feng F, Xie N. Chemical constituents from *Cichorium glandulosum*. *Chin J Nat Med* 2009; 7:193-195.
 11. Malaguarnera M, Motta M, Vacante M, Malaguarnera G, Caraci F, Nunnari G, Gaqliano C, Greco C, Chisari G, Drao F, Bertino G. Silybin-vitamin E-phospholipids complex reduces liver fibrosis in patients with chronic hepatitis C treated with pegylated interferon α and ribavirin. *Am J Transl Res* 2015; 7: 2510-2518.
 12. The National Research Council of The National Academy of Sciences. *Guide for the Care and Use of Laboratory Animals*. 8th ed. Washington: The National Academies Press; 2010.
 13. Zhang LN, Gong J, Chai NL. Comparison study of hepatic fibrosis in rats induced by carbon tetrachloride and tioacetamide. *J Fourth Mil Med Univ* 2009; 30: 1909-1912.
 14. Wang CX, Chen JS, Sun ZX, Li H, Men B, Zhang XQ, Li YW. Effect of *Lycii fructus* polysaccharides on ovulation failure in rats. *Trop J Pharm Res* 2016; 15: 799-804.
 15. Jiang Y, Wang J, Wang Y, Ke X, Zhang C, Yang R. Self-emulsifying drug delivery system improves preventive effect of curcuminoids on chronic heart failure in rats. *Saudi Pharm J* 2018; 26: 528-534.
 16. Kraehmer H, Baur P. *Tissue Preparation and Staining Procedures*. Oxford, UK; 2013.
 17. Jiang YB, Zhong M, Hu MX, Chen L, Gou Y, Zhou J, Wu PE, Ma YY. Spectrum-effect relationships between high performance liquid chromatography fingerprint and analgesic property of *Anisodus tanguticus* (Maxim) pascher (*Solanaceae*) roots. *Trop J Pharm Res* 2017; 16: 379-386.
 18. Zhou CY, Ai LY, Wang M, Wang X. Protection of *Eucommia ulmoides* polysaccharide on liver fibrosis. *Chin Tradit Herb Drugs* 2011; 42: 324-329.
 19. Liu YS, Cai W, Wu SM, Qian LH. Effect of S-adenosylmethionine on total parenteral nutrition-associated cholestasis. *World J Pediat* 2007; 3: 218-221.
 20. Su BS. Application value of various biochemical indexes in the diagnosis of liver diseases. *China Med Pharma* 2014; 4: 120-122.
 21. Koda M, Murawaki Y, Hirayama C. Free and small peptide-bound [14 C]hydroxyproline synthesis in rat liver in vitro in CCl $_4$ -induced hepatic fibrosis. *Biochem Biophys Res Commun* 1988; 151: 1128-1135.
 22. Chan RW, Wong J, Chan HL, Mok TS, Lo WY, Lee V, To KF, Lai PB, Rainer TH, Lo YM, Chiu RW. Aberrant concentrations of liver-derived plasma albumin mRNA in liver pathologies. *Clin Chem* 2010; 56: 82-89.
 23. Wang XL, Liu P, Cui YH, Hu XD, Li BQ, Ying XP. Inhibitory effect of salvianolic acid B on malondialdehyde-stimulated proliferation of rat hepatic stellate cells in vitro. *World Chin J Digestol* 2006; 14: 476-480.
 24. Yoshida T, Ogata H, Kamio M, Joo A, Shiraishi H, Tokunaga Y, Sata M, Nagai H, Yoshimura A. SOCS1 is a suppressor of liver fibrosis and hepatitis-induced carcinogenesis. *J Exp Med* 2004; 199: 1701-1707.
 25. Plank LD, Gane EJ, Peng S, Muthu C, Mathur S, Gillanders L, McIlroy K, Donahy AJ, McCall JL. Nocturnal nutritional supplementation improves total body protein status of patients with liver cirrhosis: a randomized 12-month trial. *Hepatology* 2008; 48: 557-566.
 26. Yamanaka-Okumura H, Nakamura T, Takeuchi H, Miyake H, Katayama T, Arai H, Taketani Y, Fujii M, Shimada M, Takeda E. Effect of late evening snack with rice ball on energy metabolism in liver cirrhosis. *Eur J Clin Nutr* 2006; 60: 1067-1072.
 27. Tipoe GL, Lau TY, Nanji AA, Fung ML. Expression and functions of vasoactive substances regulated by hypoxia-inducible factor-1 in chronic hypoxemia. *Cardiovasc Hematol Agents Med Chem* 2006; 4: 199-218.
 28. Dang SS, Li YP, Wang XF, Wang WJ, Li M, Wang Y. PP-099 Evaluating the immunogenicity of TGF- β 1 antigen peptide coupled-KLH as anti-hepatic fibrosis vaccine. *Int J Infect Dis* 2011; 15: S73.
 29. Guo J, Friedman SL. Hepatic fibrogenesis. *Semin Liver Dis* 2007; 27: 413-426.
 30. Safadi R, Friedman SL. Hepatic fibrosis role of hepatic stellate cell activation. *Med Gen Med* 2002; 4: 27.
 31. Cao S, Zheng B, Chen T, Chang X, Yin B, Huang Z, Shuai P, Han L. Semen *Brassicae* ameliorates hepatic fibrosis by regulating transforming growth factor- β 1/Smad, nuclear factor- κ B, and AKT signaling pathways in rats. *Drug Des Dev Ther* 2018; 12: 1205-1213.

32. Zhao SS, Shao RG, He HW. Potential targets for anti-liver fibrosis. *Yao Xue Xue Bao* 2014; 49: 1365-137.
33. Seki E, De Minicis S, Osterricher CH, Kluwe J, Osawa Y, Brenner DA, Schwabe RF. TLR4 enhance TGF-beta signaling and hepatic fibrosis. *Nat Med* 2007; 13: 1324-1332.
34. Reeves HL, Friedman SL. Activation of hepatic stellate cells-a key issue in liver fibrosis. *Front Biosci* 2002; 7: 808-826.
35. Abraham DJ. TGF- β and smad signalling in fibrosis. *Exp Dermatol* 2008; 17: 887-890.