

Original Research Article

Protective role of allicin (diallyl thiosulfinate) on cell surface glycoconjugate moieties in 7,12-dimethylbenz(a)anthracene-induced oral carcinogenesis

Sasikumar Dhanarasu

Department of Biochemistry, College of Medicine, University of Hail, PO Box 2440, Hail, Kingdom of Saudi Arabia

*For correspondence: **Email:** drdskumar31@yahoo.com; **Tel:** +966-535461930

Sent for review: 5 July 2015

Revised accepted: 20 April 2017

Abstract

Purpose: To evaluate the protective and restoring effects of allicin in 7,12-dimethylbenz(a)anthracene (DMBA)-induced buccal pouch carcinogenesis.

Methods: 1 week after receiving allicin (20 mg/kg body weight) orally, the buccal pouches of hamsters were painted daily with 0.5% 7,12-dimethylbenz(a)anthracene (DMBA) in liquid paraffin for 14 weeks and then every other day for another 2 weeks, after receiving allicin orally and thereafter for 14 weeks. The protective effects of allicin was evaluated by measuring the tumour incidence, tumour volume and tumour burdens as well as the levels of glycoconjugates were analyzed by using specific colorimetric methods. Animals not exposed to allicin and/or DMBA, those exposed to DMBA alone and others exposed to allicin alone served as controls.

Results: Allicin significantly reduced the tumour incidence, tumour volume and tumour burden. DMBA-altered glycoconjugates in plasma, buccal mucosa tumour tissues and erythrocyte membrane of tumour bearing hamsters were normalized after treated with allicin.

Conclusion: The results suggest that allicin has considerable potential to protect and restore the cell surface glycoconjugates moieties in the presence of allicin or possibly other oral carcinogenic agents.

Keywords: Oral cancer, 7,12-dimethylbenz(a)anthracene, cell surface glycoconjugates, allicin, diallyl thiosulfinate

Tropical Journal of Pharmaceutical Research is indexed by Science Citation Index (SciSearch), Scopus, International Pharmaceutical Abstract, Chemical Abstracts, Embase, Index Copernicus, EBSCO, African Index Medicus, JournalSeek, Journal Citation Reports/Science Edition, Directory of Open Access Journals (DOAJ), African Journal Online, Bioline International, Open-J-Gate and Pharmacy Abstracts

INTRODUCTION

Cancer is characterized by key hallmark properties such as cell proliferation, apoptosis evasion, invasion, metastasis, and angiogenesis [1]. One of the most common malignant diseases worldwide is cancer of the oral cavity. In the Kingdom of Saudi Arabia (KSA), epidemiological studies have shown that tobacco use or shamma is the major aetiological factor of oral carcinogenesis in KSA [2].

In experimental animals, oral squamous cell carcinoma can be induced by continued

application of potent chemical carcinogens such as 7,12-dimethylbenz(a)anthracene (DMBA) and nitroquinoline-1-oxide. Since the last six decades, the Syrian golden hamsters have been used in experimental studies for the evaluation of oral carcinogenesis. It is known that the DMBA-induced hamster buccal pouch carcinogenesis model has also histological, biochemical and molecular similarities to that of the human oral cancer [3].

Glycoproteins are proteins that have carbohydrate moiety attached covalently to their peptide backbones. The oligosaccharide moiety

of glycoconjugates is involved in the transport of metabolites across cell membranes. Glycoconjugates are released into the circulation through increased turnover, secretion, and/or shedding from malignant cells [4]. The increased levels are positively correlated with increasing stages in oral cavity cancer patients [5].

Elevated levels of glycoconjugates resulting from biochemical changes in cell surface glycoproteins and glycolipids often occur during malignant transformation [6]. In patients with malignant neoplasm, altered serum glycoconjugates are usually indicators for diagnosis, staging, prognostication, treatment monitoring, and detecting of early recurrence of cancer [7,8]. Lipid bound sialic acid is used as a marker for several cancers as well as for the prognosis of cancer treatment [9].

Several medical plants and their constituents have been reported to prevent experimentally induced squamous cell carcinomas [10-12]. Our previous studies indicated that medicinal plant modulates the effect of circulatory antioxidants against oral carcinogenesis [13]. Recently, it was reported that cardamom has chemopreventive effects against fore stomach papillomagenesis [14]. Various phytoconstituents such as carotenoids, vitamin C and phenolic acids present in medicinal plant possess protective effects [15]. In particular, flavonoids (a group of plant polyphenolic compounds) are known to possess potent antioxidant effects [16].

Allicin (Figure 1), diallyl thiosulfinate (or S-(2-propenyl) 2-propene-1-sulfinothioate), is the main biologically active compound derived from garlic (*Allium sativum* L.). It became an object of interest due to its potential to confer a vast spectrum of health benefits including: antimicrobial, antifungal and antiparasitic [17], antihypertensive [18], cardioprotective [19], anti-inflammatory [20] and anticancer activities [17,21].

The present study was designed to focus the protective role of allicin on cell surface glycoconjugate moieties by measuring the glycoconjugates of DMBA-induced oral carcinogenesis in golden Syrian hamsters.

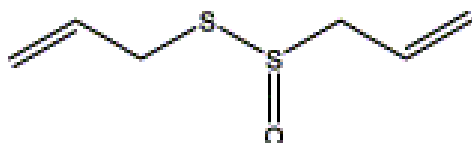


Figure 1: Chemical structure of allicin [S-(2-propenyl) 2-propene-1-sulfinothioate or diallyl thiosulfinate]

EXPERIMENTAL

Chemicals

7,12-dimethylben[a]anthracene was obtained from Sigma Aldrich Chemical Limited (St. Louis, MO, USA) while allicin was purchased from Shanghai Harvest Pharmaceutical Co., Ltd. (Shanghai, China). All other chemicals utilized in the present study were of analytical grade.

Animals

Male golden Syrian hamsters (*Mesocricetus auratus*) 8-10 weeks old, weighing 80-120 g were used for the experiments. The animals were obtained from Central Animal House, King Saud University, Riyadh, KSA and were housed in polypropylene cages at room temperatures (22 ± 2 °C) and relative humidity 55 ± 5 % with a 12 hr light/dark cycle in an experimental room.

They were provided with Purina chow diet pellets (Manufactured by Grain Silos and Flour Mills Organization, Riyadh, KSA) and tap water *ad libitum*. Animals were acclimatized for a week before the study. All the experimental protocols were approved by the Institutional Animal Care and Use Committee of the University of Hail, KSA.

Experimental protocol

The Golden Syrian hamsters were randomized into four groups of 10 animals each as illustrated in the experimental protocol in Figure 2. The left buccal pouches of animals allocated in group I were painted with liquid paraffin thrice a week for 14 weeks and used as negative control animals. Similarly the left buccal pouches of animals in groups II and III were painted with 0.5 % DMBA in liquid paraffin thrice a week for 14 weeks [22].

While the animals in group II received no other treatment, those in group III receive oral administration of allicin (20 mg of powder/ kg body weight), starting one week before exposure to the carcinogen and continued every other day (once in 2 days), until each animal was sacrificed. Group IV animals received oral administration of allicin (20 mg/kg body weight) alone throughout the experimental period. The experiment was terminated at the end of 16 weeks and all animals after giving anesthesia were euthanized by cervical dislocation. The experiments were designed according to our previous studies [10-12].

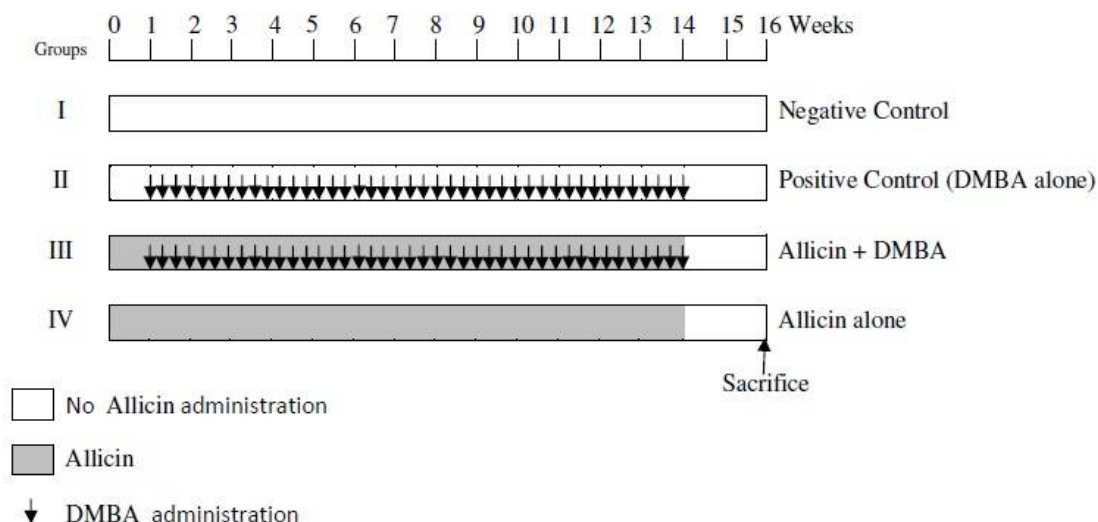


Figure 2: Experimental protocol for chemoprevention study of allicin against DMBA-induced carcinogenesis

The buccal mucosal tissues were immediately blotted and kept in an ice bath. Histopathological examination was carried out on the buccal mucosal tissues for all animals. Briefly, the mucosa tissue was fixed in 10 % formalin and routinely processed and embedded with paraffin. Then, 2-3 μm section were cut in a rotary microtome and stained with haematoxylin and eosin for examination. Tissue samples were weighed and homogenized using appropriate buffer in an all glass homogenized with Teflon pestle using a specific medium.

The protein-bound hexose in plasma, erythrocyte membrane preparation and defatted issues were estimated as previously described [23-26] Sialic acid estimation was done by the method of Warren [27]. Plasma lipid bound sialic acid level was determined by the method of Katopodis and Stock [28] while fucose was estimated by the method of Dische and Shettles [29].

Statistical analysis

Table 1: Effects of allicin on tumour incidence and volume and burden of control and experimental Syrian hamsters in each group

| Group | Tumour incidence | Total tumours | Tumour volume | Tumour burden |
|----------------------------|-------------------------|----------------------------|--------------------------------|--------------------------------|
| | Squamous cell carcinoma | Number of tumours (animal) | $\text{mm}^3/\text{tumour}^\#$ | $\text{mm}^3/\text{animal}^\#$ |
| Group I (Negative Control) | 0 | 0 | 0 ^a | 0 ^b |
| Group II (DMBA) | 100 % | 31 (10) | 358.26±32.72 ^a | 1110.61±75.42 ^b |
| Group III (DMBA + allicin) | 11 % | 2 (1) | 75.73±6.13 ^a | 151.46±8.38 ^b |
| Group IV (allicin alone) | 0 | 0 | 0 ^a | 0 ^b |

Tumour volume was measured using the formula $V = \frac{4}{3} \pi \left(\frac{D_1}{2}\right) \left(\frac{D_2}{2}\right) \left(\frac{D_3}{2}\right)$ where D_1 , D_2 and D_3 are the three diameters (mm) of the tumour. Tumour burden was calculated by multiplying tumour volume and the number of tumours/animal. [#] Values are expressed as mean ± SD for 10 animals in each group. ^a $p < 0.05$, ^b $p < 0.05$

The values are expressed as Mean±SD and the statistical comparisons were performed by one-way analysis of variance (ANOVA) followed by Duncan's multiple range test (DMRT). At 95 % confidence interval, p-values less than 0.05 were considered statistically significant.

RESULTS

Table 1 shows the tumour incidence, tumour volume and tumour burden of the control and experimental Syrian hamsters. In DMBA-painted hamster (group II), 100 % tumour formation with mean tumour volume (358.26 mm^3) and tumour burden (1110.61 mm^3) was observed. Oral administration of allicin (20 mg/kg body weight) significantly reduced the tumour incidence from 100 % to 89 %, tumour volume (75.73 mm^3) and tumour burden (151.46 mm^3) in DMBA-painted hamsters (group III). No tumour was observed in negative control (group I) as well as allicin alone treated animals (group IV).

The histopathological features of control and experimental Syrian hamsters in each group are provided in Table 2. Different histopathological changes (severe keratosis, hyperplasia, dysplasia and squamous cell carcinoma of the epithelium) were observed in hamsters painted with DMBA alone (group II). A mild to moderate preneoplastic lesions (hyperplasia (+), keratosis (++) and dysplasia (+)) were noticed in group III animals.

Figure 3 shows the levels of protein bound hexose, hexosamine, total sialic acid, lipid bound sialic acid and fucose in plasma of control and experimental Syrian hamsters in each group. The levels of glycoconjugates were significantly increased in tumour bearing hamsters (group II) as compared to control animals (group I). Oral administrations of allicin (20 mg/kg body weight) to DMBA painted animals (group III) reverted the status of glycoconjugates to near normal concentration while the animals treated with allicin alone showed no significant difference in glycoconjugates levels as compared to control animals. A significant decrease ($p < 0.05$) in the levels of erythrocyte membranes protein bound hexose, hexosamine and total sialic acid were observed in group II hamsters and the increase in group III animals when compared to group I. The levels of hexose, hexosamine and sialic acid were no significant ($p < 0.05$) difference in group IV animals when compared to group I animals (Figure 4).

The levels of protein bound hexose, total sialic acid and fucose in buccal mucosa tissues of control and experimental Syrian hamster in each group are shown in Figure 5. The hexose, total sialic acid and fucose significantly increased in group II animals tissues compared to control rats (group I). Oral administration of allicin (20 mg/kg body weight) normalized the status of glycoconjugates levels in DMBA treated rats (group III). No significant differences were noticed in the levels of glycoconjugates in Syrian hamsters treated with allicin alone when

compared with control rats.

DISCUSSION

In this study allicin significantly reduced the DMBA-induced tumour incidence, tumour volume and tumour burden. It also normalized the altered glycoconjugates in plasma, buccal mucosa tumour tissues and erythrocyte membrane of tumour bearing hamsters.

Malignant transformation of oral epithelium is associated with atypical glycosylation of cell surface carbohydrates [30]. In the presence of DMBA, the altered levels of protein bound carbohydrates during carcinogenesis [31] with increased levels of protein bound hexose, hexosamine and sialic acid in the plasma [32] observed in group II animals is well documented. Malignant transformation of oral epithelium is often connected with atypical glycosylation of cell surface carbohydrates [33]. Increased levels of glycoprotein linked with higher proliferative activity often occur in ovarian cancer [34]. In cancer patients, the high levels of glycoconjugates in sera is usually as a result of the release of glycoconjugates from the cell membrane [35]. Evidence from animal experiments suggests that the presence of malignant tumours invoke increased hepatic synthesis of glycoproteins that can then enter into the circulation [36]. Increase in glycoprotein has also been reported in hepatic neoplasm [37]. This may be due to the elevated hepatic synthesis, decreased amounts or deficiency of the enzymes involved in the synthesis of cell surface glycoproteins.

Higher levels of serum sialic acids have been documented in patients with various types of cancers including oral carcinoma [38]. In DMBA-painted animals (group II), the elevated total sialic acid level can be explained by a spontaneous release of aberrant sialic acid containing cell surface glycoconjugates [39].

Table 2: Histopathological features of control and experimental Syrian hamsters in each group (n=10)

| Group | Keratosis | Hyperplasia | Dysplasia | Squamous cell carcinoma |
|-------------------------------|-----------|-------------|-----------|-------------------------|
| Group I (Negative Control) | - | - | - | - |
| Group II (DMBA) | +++ | +++ | +++ | ++(10) |
| Group III (DMBA + allicin) | ++ | + | + | ++(1) |
| Group IV (allicin alone) | - | - | - | - |

Absent -, Mild +, Moderate ++, Severe +++. Number in parentheses indicates total number of animals bearing tumours

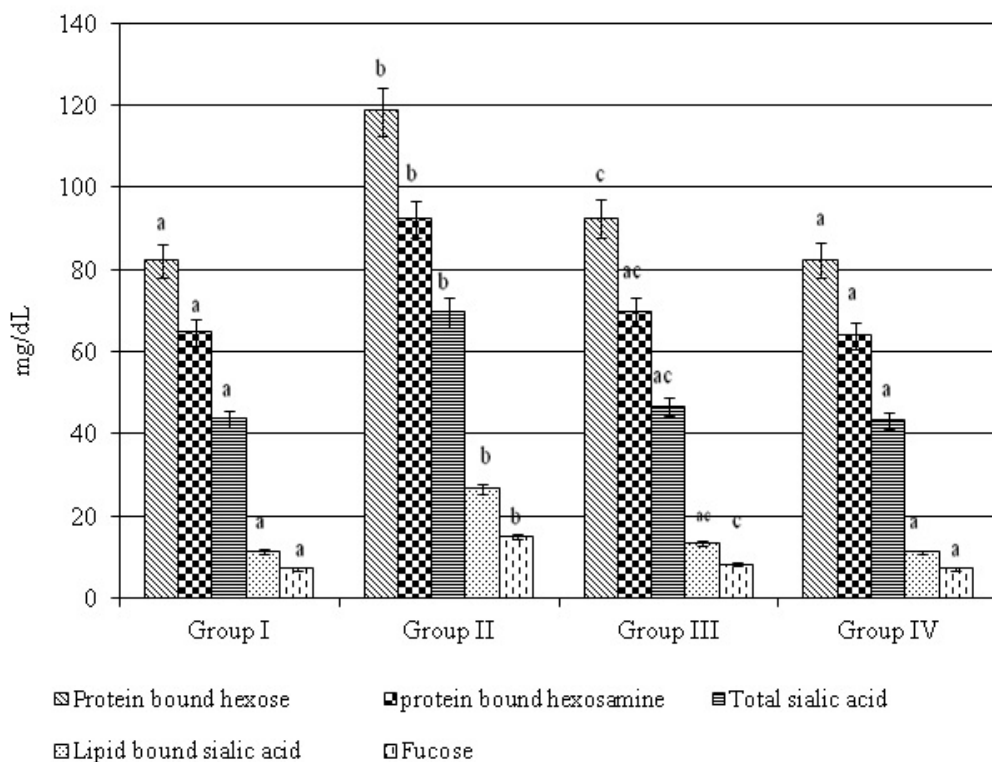


Figure 3: Status of glycoconjugates in plasma of control and experimental Syrian hamsters in each group. The values that do not share a common superscript letter (a, b and c) between groups differ significantly at $p < 0.05$ (analysis of variance followed by DMRT; $n=10$).

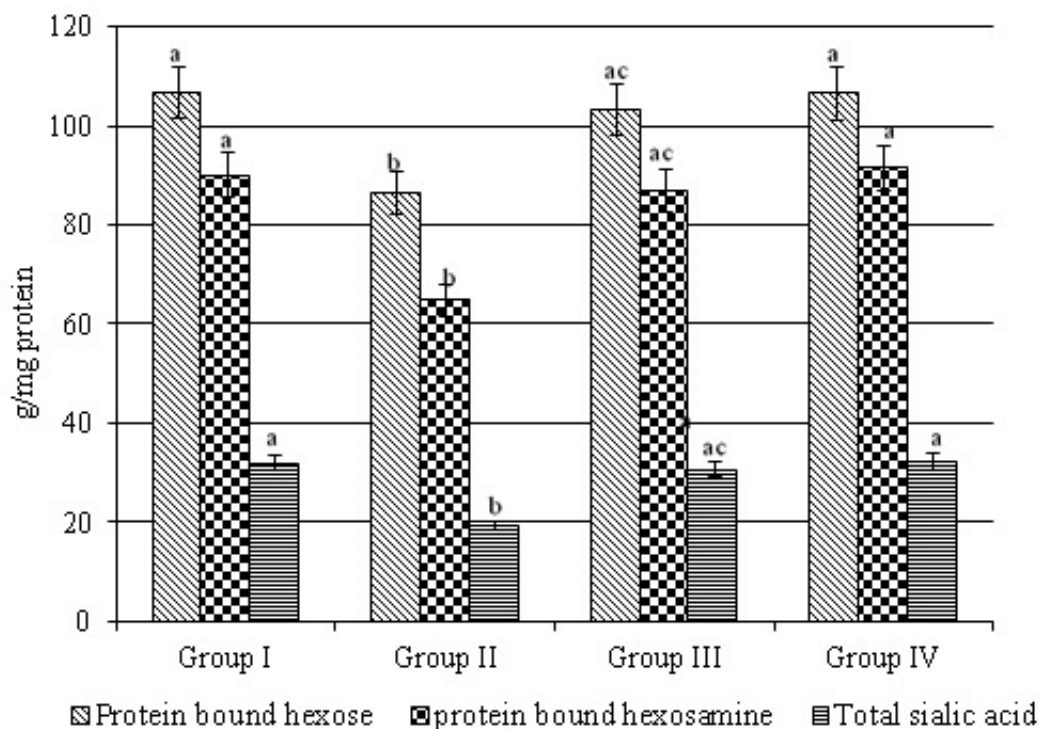


Figure 4: Status of glycoconjugates in erythrocyte membranes of control and experimental Syrian hamsters in each group. The values that do not share a common superscript letter (a, b and c) between groups differ significantly at $p < 0.05$ (analysis of variance followed by DMRT; $n=10$).

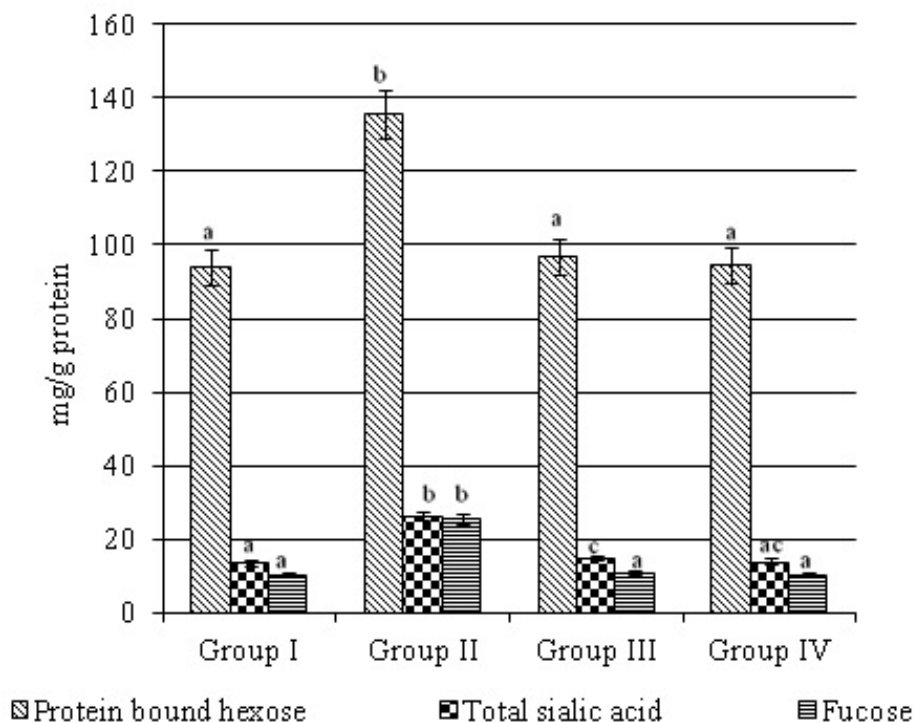


Figure 5: Status of glycoconjugates in buccal mucosa of control and experimental Syrian hamsters in each group. The values that do not share a common superscript letter (a, b and c) between groups differ significantly at $p < 0.05$ (analysis of variance followed by DMRT; $n=10$).

It may also be due to increase in the activity of serum or tissues sialidase. In this study, allicin not only prevented the cancer formation but also inhibited the abnormalities seen in cell surface glycoconjugates in the tumour tissues and circulation, which indicates their membrane stability effects during neoplastic transformation.

CONCLUSION

The results suggest that allicin has considerable potential to protect the cell surface glycoconjugate moieties during oral carcinogenesis. Protective effect of allicin is probably due to its suppressive effect on glycoprotein synthesis by modulating the activities of the enzymes involved in the glycosylation. Further studies are however needed to elucidate the exact molecular mechanism for the chemopreventive potential of allicin in DMBA-induced oral carcinogenesis.

DECLARATIONS

Acknowledgement

We wish to express our sincere thanks and gratitude to Prof. (Dr). Awdah Al-Hazimi for his valuable suggestions and also thankful to the

University Hail, Saudi Arabia for providing necessary facilities.

Conflict of Interest

No conflict of interest associated with this work.

Contribution of Authors

The authors declare that this work was done by the authors named in this article and all liabilities pertaining to claims relating to the content of this article will be borne by them.

Open Access

This is an Open Access article that uses a funding model which does not charge readers or their institutions for access and distributed under the terms of the Creative Commons Attribution License (<http://creativecommons.org/licenses/by/4.0>) and the Budapest Open Access Initiative (<http://www.budapestopenaccessinitiative.org/read>), which permit unrestricted use, distribution, and reproduction in any medium, provided the original work is properly credited.

REFERENCES

- Hanahan D, Weinberg RA. Hallmarks of cancer: the next generation. *Cell*, 2011; 144: 646-674.
- Allard WF, De Vol. EB, Te OB. Smokeless tobacco (shamma) and oral cancer in Saudi Arabia. *Community Dent Oral Epidemiol*, 1999; 27: 398-405.
- Miyata M, Furukawa M, Takahasi K, Gonzalez FJ, Yamazoe Y. Mechanism of 7,12- dimethylbenz(a)-anthracene induced immunotoxicity: role of metabolic activation at the target organ. *Jap J Pharmacol*, 2001; 86: 302-309.
- Rajpure KB, Patel PS, Chawda JG, Shah RM. Clinical significance of total and lipid bound sialic acid levels in oral pre-cancerous and oral cancer. *J Oral Pathol Med*, 2005; 34: 263-267.
- Baxi BR, Patel PS, Adhvaryu SG, Dayal PK. Usefulness of serum glycoconjugates in precancerous and cancerous diseases of the oral cavity. *Cancer*, 1991; 67: 735-740.
- Manoharan S, Padmanabhan M, Kolanjiappan K, Ramachandran CR, Suresh K. Analysis of glycoconjugates in patients with oral squamous cell carcinoma. *Clinica Chemica Acta*, 2004; 339: 91-96.
- Patel PS, Baxi BR, Adhvaryu SG. Evaluation of serum sialic acid, heat stable alkaline phosphatase and fucose as markers of breast carcinoma. *AntiCancer Res*, 1990; 10: 1071-1074.
- Baxi BR, Patel PS, Adhvaryu SG, et al. Usefulness of serum glycoconjugates in precancerous and cancerous diseases of the oral cavity. *Cancer*, 1991; 67: 135-140.
- Voigtman R, Pokorny J and Meinshausen A. Evaluation and limitations of the lipid-associated sialic acid test for the detection of the human Cancer. *Cancer*, 1989; 64: 2279-2283.
- Sasikumar D, Mathi S, Suzan MAS, Manoharan S, Prema S. Terminalia Arjuna (Roxb.) modulates circulatory antioxidants on 7,12-dimethylbenz(a)anthracene- induced hamster buccal pouch carcinogenesis. *Oman Medical Journal*, 2010; 25 (4): 276-281.
- Sasikumar D, Awdah H, Prema S, Mathi S. Chemopreventive and Antilipidperoxidative Potential of *Thespesia populnea* (L.) on Experimental Buccal Pouch Carcinogenesis, *Ibnosina J Med BS*, 2010; 2(6): 269-277.
- Manoharan S, Panjamurthy K, Vasudevan K, Sasikumar D. Protective effect of *Jasminum grandiflorum* Linn. on DMBA-induced chromosomal aberrations in bone marrow of wister rats. *Int J Pharmacol*, 2006; 2(4): 406-410.
- Sasikumar D, Mathi S, Abdel-Tawab Salama SM, Manoharan S and Prema S. Terminalia arjuna (Roxb.) modulates circulatory antioxidants on 7,12-dimethylbenz(a)anthracene- induced hamster buccal pouch carcinogenesis. *Oman medical journal*, 2010; 25(4): 276-281.
- Samir Qiblawi, Sasikumar Dhanarasu and Moez Al-Islam Faris. Chemopreventive Effect of Cardamom (*Elettaria cardamomum*) against Benzo(a)pyrene-Induced Forestomach Papillomagenesis in Swiss Albino Mice. *J Environ Pathol Tox*, 2015; 34(2): 95–104.
- Tan AC, Konczak I, Sze DM and Ramzan I. Molecular pathways for cancer chemoprevention by dietary phytochemicals. *Nutr Cancer* 2011; 63: 495–505.
- Xiao ZP, Peng ZY, Peng MJ, Yan WB, Ouyang YZ, Zhu HL. Flavonoids health benefits and their molecular mechanism. *Mini Rev Med Chem* 2011; 11: 169–77.
- Koch HP and Lawson LD. Garlic: the Science and therapeutic application of *Allium sativum* L. and related species. 2nd ed. Baltimore: Williams & Wilkins; 1996.
- Elkayam A, Mirelman D, Peleg E, Wilchek M, Miron T, Rabinkov A, et al. The effects of allicin and enalapril in fructose-induced hyperinsulinemic hyperlipidemic hypertensive rats. *Am J Hypertens* 2001; 14:377–81.
- Gonen A, Harats D, Rabinkov A, Miron T, Mirelman D, Wilchek M, et al. The antiatherogenic effect of allicin: possible mode of action. *Pathobiology* 2005; 72:325–34.
- Lang A, Lahav M, Sakhnini E, Barshack I, Fidder HH, Avidan B, et al. Allicin inhibits spontaneous and TNF- α induced secretion of proinflammatory cytokines and chemokines from intestinal epithelial cells. *Clin Nutr*. 2004; 23:1199–208.
- Hirsch K, Danilenko M, Giat J, Miron T, Rabinkov A, Wilchek M, et al. Effect of purified allicin, the major ingredient of freshly crushed garlic, on cancer cell proliferation. *Nutr Cancer*. 2000; 38:245–54.
- Morris AL. Factors influencing experimental carcinogenesis in the hamster cheek pouch. *J Dent Res*, 1961; 40: 3-15.
- Dodge JF, Mitchell G, Hanahan DJ. The preparation and characterization of hemoglobin free ghosts of human red blood cells. *Arch Biochem Biophys*, 1968; 110: 119-130.
- Quist EH. Regulation of erythrocyte membrane shapes by calcium ion. *Biophys Res Commun*, 1980; 92: 631-637.
- Niebes P. Determination of enzymes and degradation products of glycosaminoglycan metabolism in the serum of healthy and varicose subjects. *Clin Chim Acta*, 1972; 42: 399-408.
- Wagner WD. A more sensitive assay discriminating galactosamine and glucosamine in mixture. *Anal Biochem*, 1979; 94: 369-394.
- Warren L. Thiobarbituric acid and assay of sialic acid. *J Biol Chem*, 1959; 234: 1974-1975.
- Katopodis NN, Stock CC. Improved method to determine lipid bound sialic acid in plasma. *Res Commun Chem Pathol Pharmacol*, 1980; 30: 171-180.
- Dische L, Shettles LB. Specific color reactions of methyl pentoses and spectrophotometric micromethod for their determination. *J Biol Chem*, 1948; 175: 595- 604.
- Dennis JW, Granovsky M, Warren CE. Glycoprotein glycosylation and cancer progression. *Biochim Biophys Acta*, 1999; 1473: 21-34.

31. Chen H Egan JO, Chiu. Regulation and activities of α -fetoprotein. *Crit Rev Eukaryot Gene Expr*, 1997; 7: 11-41.
32. Herfeld A and Greengard O. The effect of lymphoma and other neoplasms on hepatic and plasma enzymes of the host rat. *Cancer Res*, 1977; 37: 231-238.
33. Dennis JW, Granovsky M, Warren CE. Glycoprotein glycosylation and Cancer progression. *Biochim Biophys Acta*, 1999; 1473: 21-34.
34. Goldhirsch A, Berger E, Muller O. Ovarian Cancer and tumour marker: Sialic acid, galactosyl transferase and CA-125. *Oncology*, 1998; 45: 281-286.
35. Hickey R, Clark RL, Cumbley RW. Year book of Cancer. Chicago: Yearbook, Medical Publishers 1986; 427.
36. Macbeth RA and Bekesi JG. Plasma glycoproteins of malignant disease. *Arch Surg*, 1964; 88: 635-637.
37. Agostini C. Hexosamine content found in serum and ascitic fluid of the rat during the development of Yoshida ascites hepatoma cells. *IRCS Med Sci Libr Compend*, 1976; 4: 400-403.
38. Tewarson SL, Mittal VP, Singh M. Serum sialic acid: an important Cancer marker. *Indian J Cancer*, 1993; 30: 125-131.
39. Dall'olio F, Trere D. Expression of alpha 2,6- sialylated sugar chain in normal and neoplastic colon tissues. Detection by digoxigenin conjugated Sambucus nigra agglutinin. *Eur Jr Histochem*, 1993; 37: 257-265.